

JOURNAL

OF

MORPHOLOGY

EDITED BY

C. O. WHITMAN

University of Chicago

WITH THE CO-OPERATION OF

EDWARD PHELPS ALLIS
Milwaukee

F. R. LILLIE
University of Chicago

HOWARD AYERS
University of Cincinnati

T. H. MORGAN
Bryn Mawr College

E. G. CONKLIN
University of Pennsylvania

E. B. WILSON
Columbia University

VOLUME XVIII

LANCASTER, PA., U. S. A.

The New Era Printing Company

1903

1190

CONTENTS OF VOL. XVIII

NOS. 1 AND 2 APRIL, 1903

PAGES

I. HENRY LESLIE OSBORN. *On the Habits and Structure of Cotylaspis insignis, Leidy, from Lake Chautauqua, New York* 1–44

II. EDWARD PHELPS ALLIS. *The Skull and the Cranial and First Spinal Muscles and Nerves in Scomber scomber* 45–328

Volume XVIII. *April, 1903.* *Nos. 1 and 2.*

JOURNAL

OF

MORPHOLOGY.

ON THE HABITS AND STRUCTURE OF COTYLASPIS INSIGNIS LEIDY, FROM LAKE CHAUTAUQUA, NEW YORK.

HENRY LESLIE OSBORN,

Saint Paul, Minnesota.

TABLE OF CONTENTS.

a. Introduction 1
b. Distribution 3
c. Habits 7
d. External anatomy 9
e. The Cuticle 12
f. The Musculature 12
g. The Parenchyma 14
h. The Alimentary System 15
i. The Excretory System 17
k. The Nervous System 21
l. The Marginal Organs 24
m. The Reproductive System 26
i. general statement 26
ii. the male organs 27
iii. the female organs 31

a. Introduction.

The genus *Cotylaspis* was founded in 1857 by Dr. Joseph Leidy, of Philadelphia, for the reception of a fluke worm which

he found in the Unionidæ of the Schuylkill River. His account, which is sufficiently adequate for taxonomic purposes, is very brief and does not extend to details of morphological value. Leidy in his notice in 1858 expressed the opinion that *Cotylaspis* may be a stage in the life cycle of *Aspidogaster,* but this proved to be incorrect. In 1884 Poirier, in a paper describing a number of different trematodes, devotes two pages to a summary of the anatomy of a form which was found in a turtle [*Triarthra*] in the Senegal River in Africa, and which he referred to the genus *Aspidogaster,* making it a new species, *A. lenoiri.* This account is confined to the coarser, anatomical facts. In 1893 Braun reported the facts of Poirier's article in Bronn's *Klassen und Ordnungen.* In 1892 Monticelli revised the Aspidobothridæ in his contribution to Leukart's Festschrift volume. He saw the necessity of separating Poirier's fluke from the genus *Aspidogaster,* and instituted a new genus, *Platyaspis,* for it. In 1898 the present writer reported the anatomy of a fluke found by him in the Anodontas of Lake Chautauqua in 1895, which presented such a close resemblance to the form found by Poirier in Africa as to convince him of their generic similarity, and relying on the work of Monticelli an account of it was published under that name. This was followed by an article by Professor C. A. Kofoid in 1899 in which he pointed out the fact that the *Platyaspis* of my former paper is undoubtedly identical with Leidy's *Cotylaspis,* and the further fact that *Platyaspis* in Monticelli's sense differs from *Cotylaspis* in one particular, the marginal organs of the ventral sucker, to which reference will be made later in the course of this paper.

The object of this paper is to place on record the facts as at present known in regard to this member of the family Aspidobothridæ, a family of great interest to students of the Trematodes, yet one in regard to some of the members of which almost nothing has until recently been known. Our knowledge of the family hitherto rests on the studies that have been reported by Voeltzkow and Stafford of *Aspidogaster,* by Monticelli and quite recently Nickerson of *Cotylogaster,* and by Nickerson of *Stichocotyle.* In addition to these genera the anatomy of which is adequately known, we have briefer records of *Macraspis, Cotylaspis,* and

Platyaspis, which latter however is probably identical with *Cotylaspis.* Another genus, *Aspidocotyle,* is also known very inadequately.

Material for the study of *Cotylaspis* can be had in abundance at Chautauqua, but unfortunately it has only been possible for me to be there during parts of July and August, so that I have not had access to the material during the remainder of the year. The flukes, as well as the hosts, bear transportation well, so that I have been able to use them for histological purposes at other times, but I have reason to suppose that the disturbance of their natural environment reacts unfavorably on the reproductive organs, and at any rate on the development, and that material should be studied *in situ* for the embryology.

The small size of the animal makes it available for study alive under compression, and most of the parts have been examined in this way. Compressed specimens have been killed and fixed, preferably by means of saturated aqueous solution of corrosive, then hardened in the same fluid and stained and mounted whole, and preparations made in this way supplement the live animal. The excretory system in its finer tubes can only be seen in the living specimen. Material was also hardened in various preservatives for sectioning: Hermann's, Flemming's and Perenyi's fluids were used, also Mayer's picro-nitric, and saturated aqueous corrosive sublimate solution. For general histological purposes I found that the corrosive hardening was the best, followed by iron-hæmatoxylin stain. I also tried using methylene blue *intra vitam.* This demonstrated the muscular system beautifully but has not as yet given me satisfaction with the nervous system.

The work on this article has been done in part in the laboratory of the Chautauqua College of Liberal Arts, and in part in that of Hamline University. I am especially obliged to Dr. W. S. Nickerson for many valuable suggestions in connection with the best technique for the study of trematodes, and for the use of his manuscript of *Cotylogaster occidentalis.*

b. Distribution.

All my material was found in Lake Chautauqua, New York, a glacial lake, twenty-five miles long and varying in width from one

to two miles, with wooded or open sloping shores. It is situated at the head of a small river which finds its way into the Allegheny at Warren, Pennsylvania, and thus belongs to the Mississippi River system. There are a number of summer resorts on the lake, and the greatest among them, The Chautauqua Assembly, has a permanent summer population of perhaps fifteen thousand people, which is occasionally swelled for the day to perhaps twice that number. At the foot of the lake the city of Jamestown is located. A complete exploration of the lake has not been possible, but collections have been made at localities in different parts, including both ends and the middle of the lake, and where the bottom was different as clean and sandy, shelly and stony with weeds, and muddy, but only on or near the shore where material could be taken from a boat or by wading. Several different species of Unionidæ are found in all of these situations. Off the Assembly grounds, which are located three miles from the head of the lake, we find *Anodonta plana* Lea and less often *A. grandis*. *Unio luteolus* Lam. is the commonest species of *Unio*, while *U. edentulus* Say is very common, and *U. ventricosus*, *U. phascolus* Hild. and *U. gibbosus* Bar. are found more rarely. I have examined a great many individuals of all of these forms during the seasons of '95, '96, '97 and '98, chiefly from the shore at Chautauqua Assembly, and as a general result can say that *Cotylaspis* occurs in all parts of the lake and that it is almost totally confined to *Anodonta*, being found in *Unio* only in two instances (in *U. luteolus*). For the sake of a record I will state here that my specimens were obtained at the following points on the lake: near the head of the lake at Point Chautauqua and Chautauqua Assembly; in the middle of the lake at Long Point and Bemus Point, and at the foot of the lake at Celoron. I also collected at the beginning of the "outlet," and at the river at Jamestown.

The preference of the fluke for *Anodonta* is surprising, since *U. luteolus* is equally abundant and *U. edentulus* also is very frequent. At one time I thought that it might be attributed to the fact that in *Anodonta* the kidney is directly accessible from the branchial chamber, while in *Unio luteolus* it is not, owing to the fact that the inner gills coalesce with the adjacent surface of the visceral mass. But the same communication as in *Anodonta* ex-

ists in *U. edentulus,* so that the kidney is equally accessible there, yet *Cotylaspis* has not been found in Chautauqua Lake in *U. edentulus.*

Moreover in other localities this discrimination is not made by the fluke. Thus M. A. Kelley, '99, reports observations made in Pennsylvania, Illinois, and Iowa, in all of which states he found *Cotylaspis* present in several different species of *Unio,* though he reports *Anodonta* as being most frequented.

Not only does Kelley report a much larger list of hosts for the animal but he reports a much greater number of parasites per host than is generally found in the mussels of Lake Chautauqua. The maximum number which I found was twenty-four, and this is far in excess of the average number, while the maximum found by Kelley is thirty-eight, and he cites a case of *Anodonta corpulenta* in which Kofoid found ninety-two *Cotylaspis* in a single mussel. This far exceeds the numbers for the Chautauqua *Anodontas,* where however nearly every one is parasitized in some degree. In only two cases were the flukes entirely absent. In a few instances I found only one or two, but the number commonly ranges from four to eight or ten, though it varies somewhat with the kind of bottom inhabited by the host.

A count made in three different situations gave the following results:

Bottom of clean, hard sand.	32 Anodontas, 113 flukes, av. of 3.5 per host.
Bottom of stones, weeds and mud.	86 Anodontas, 432 flukes, av. of 5 per host.
Bottom of very soft, thick oozy mud.	11 Anodontas, 96 flukes, av. of 8.7 per host.

The last of these situations is especially interesting. It is at the mouth of a drain, and the mud there is very fine grained. The hosts are of large size, and their shells almost entirely destitute of epidermis, and externally are white and pearly.

These facts indicate a correlation between the muddiness of the water and the number of flukes present in a given host. The muddiness seems due to organic matter, and the implication is that this furnishes food for a greater number of the flukes. The age of the host is not closely correlated with the number of *Cotylaspis* if at all. To test this point fifty Anodontas from a stony, weedy

bottom were taken and the length of the shell in millimetres taken, and the number of *Cotylaspis* counted. The results of this enumeration were as follows:

Shell in mm.	No. of *Cotylaspis.*	Shell in mm.	No. of *Cotylaspis.*	Shell in mm.	No. of *Cotylaspis.*	Shell in mm.	No. of *Cotylaspis.*
34	2	60	7	70	5	80	7
		60	7	70	4	82	9
42	1	63	4	71	6	83	11
45	4	63	7	73	2	87	6
47	4	64	6	73	3	86	9
47	6	66	4	73	4	89	10
		66	6	74	2		
51	2	66	14	74	4		
53	3	66	5	74	8		
56	6	66	3	75	4		
57	3	67	3	75	5		
58	6	68	1	77	5		
59	4	68	1	77	7		
		68	3	77	13		
		68	4	78	5		
		69	1	79	4		
				79	7		
				79	9		
Total, 11	42	16	76	18	97	6	52
Average.	3.8		4.7		5.4		8.7

These figures may be accepted as showing that, while the age of the host has some influence in accounting for the number of *Cotylaspis* present, it cannot be a determining factor, as is shown clearly by the fact that we find fourteen parasites in a host 66 mm. long and only one in another 69 mm. long.

There are some noteworthy differences between the facts of distribution of *Cotylaspis* at Chautauqua Lake and in the localities that are noted by Kelley. He finds the parasite by no means restricted to *Anodonta,* but while it is not as generally found among the Unionidæ as is *Aspidogaster,* still it is found in 24 of the 44 different species of hosts that he examined, as against 37 hosts for *Aspidogaster.* He also finds that *Cotylaspis* is present in six of the ten localities that he examined, *Aspidogaster* being found in nine of them. In Lake Chautauqua, as noted, *Cotylaspis* is not found outside of the genus *Anodonta* (the exceptions being too occasional to be counted). As some of the localities studied by Kelley are of the same river system as Lake Chautauqua and are nearer the mouth of the river, and as the

occurrence of *Cotylaspis,* as well as of *Aspidogaster,* is more considerable in those places, the supposition is aroused that possibly the distribution of the parasite has been from the lower to the higher parts of the river system and that its absence from the other Unionidæ in Chautauqua Lake means a shorter period since its introduction there. His figures indicate a preference for *Anodonta,* and if, for any reason, the numbers of *Cotylaspis* in the lake are limited to the number that can be accommodated by the *Anodonta* population, then we should not expect to find them outside of that form. The idea of a comparatively recent arrival of the flukes in Lake Chautauqua would harmonize with this interpretation of the distribution. Kelley's list of localities includes, besides the Schuylkill system and the Mississippi system, the Susquehanna River system as included in the distribution of *Cotylaspis.* It will be interesting to find whether it occurs in other rivers of this country. It appears probable that it is much more common in this country than in other parts of the world.

A summary of these facts includes the following points:

Cotylaspis is confined to *Anodonta* and not found in *Unio.*

It is nearly universally present in *Anodonta.*

Its numbers are not in direct relation with the size and age of *Anodonta.*

Its numbers vary directly with the purity or impurity of the water in which the host is found.

c. Habits.

Cotylaspis is most commonly found firmly adhering by its large ventral sucker to the free outer surface of the kidney of its host (see Fig. 1). It is also, but less often, found adhering to the free edge of the inner gill plate or to the adjoining surfaces of the visceral mass. By opening the mantle chamber of the mussel and pushing the gills aside, the kidney is displayed and the fluke can be seen in its natural position. Its body presents two distinct portions, the large oval adhesive "ventral sucker," arising from which and extending obliquely upward and forward is the slender and extremely mobile body of the animal. In life the body is kept swaying, first to one side and then to the other, and its dilated tip touched to the kidney surface. By watching it with a lens the following events are seen to take place: First there is

an elongation of the body; then the dilatation of the front portion to form a large circular disk, which is applied to the kidney surface, sometimes firmly enough to adhere strongly; then a contraction of the disk, sweeping across the surface of the kidney and gathering up material, which is then seen to be swallowed, movements for the purpose taking place in the pharynx; then the entire body is much contracted, after which the events are repeated in the same order in another place. I have tried to show these facts in Fig. 2, *b*.

One might suppose that the fluke would change its position from time to time, but it does not appear ordinarily to do so. To test this I opened an *Anodonta* and pinned the parts under water in such a position as enabled me to watch the flukes and, to report one case, I found that two flukes did not move at all from the position in which I first found them from 9.30 A. M. of one day till 9.30 A. M. of the day following. In the evening of that day they had approached each other, and on the day following, forty-eight hours after the beginning of the experiment, the kidney was dead and decaying, and the flukes were found on the adjacent surface of the visceral mass.

I found that the flukes bear artificial environments very well. I have removed them from the mussel and kept them in glass dishes covered so as to protect them from the dust, and they live thus for several weeks. They seem equally well off in hydrant water or in normal salt solution or in a mixture of the two (equal parts). Flukes have lived thus three weeks and behaved normally. In such case they adhere to a certain spot, never moving from it, and keep going through the motions already described, thereby keeping a circular area around them swept entirely clean. I have also kept mussels in my laboratory aquaria for several months and had them sent me by express from Chautauqua for the sake of the flukes. I found that, in such, most of the systems were normal, but there were indications that the reproductive organs had suffered some disturbance.

There is a long and important interval in the life-history of *Cotylaspis* of which nothing is known. As I shall show later in this paper, the development of the eggs from the earliest segmentation takes place after the egg has left the parent, from which

time we know nothing of the fluke till it is found in the mantle cavity of the *Anodonta* at which time it has assumed the characteristics of the adult. It is a strange and interesting fact that Poirier found *Platyaspis* in the intestine of a turtle, but as the form he found is fully matured we are debarred thereby from regarding the turtle as an intermediate host. It is possible that the fluke happened in the turtle accidentally, and more likely than that the turtle should be the usual final host.

As to the relation of the fluke to the *Anodonta,* Leidy pointed out that it is ectoparasitic, and it appears that it is rather a messmate than a parasite. We can see that its work in constantly sweeping up material from the surface of the kidney would be favorable rather than otherwise to the mussel. And this habit is clearly correlated with the greater numbers found in water that is more dirty. The operation yields food for the fluke, and hence the dirtier the water the more numerous they are, as we have seen.

In all the mussels which I have examined I have made a careful search in the cavity of the kidney and in the pericardial chamber for the double purpose of deciding whether *Cotylaspis* is in the habit of locating in either of these organs, and also of ascertaining if there is any other fluke that dwells in these parts. In regard to both of these enquiries I found, as a result of a very great many observations, that not only is *Cotylaspis* never found there, but also that no other fluke is. This result was the more unexpected since the closely allied fluke *Aspidogaster* is very generally found in the pericardium and connected organs in the Unionidæ, being reported by Kelley as more frequent than *Cotylaspis.* I am convinced that *Aspidogaster* does not exist in Chautauqua Lake, or if present is extremely rare, since I have been familiar with Unionidæ there for five years and it has not appeared in that time.

d. External Anatomy.

Cotylaspis (see Figs. 3, 4 and 5), as already noted, presents two somewhat distinct regions, the body and the ventral sucker. The latter is very conspicuous and underlies and supports the former. As in all the members of the family Aspidobothridæ the

ventral sucker is complex, and it is subdivided into a number of acetabula. The body does not possess the usual oral sucker of the order, but it begins with a pre-oral cavity the "mouth funnel," encircled by a very thin and mobile wall, looking obliquely downward and forward and tapering posteriorly to the mouth, which is situated on the summit of a low eminence and opens by means of a narrow vertical slit. The body enlarges as it goes back, till near the posterior end it suddenly becomes bluntly rounded. In life the body is distinctly elevated above the ventral sucker, and its contour is complete posteriorly, but in preserved specimens this distinctness is more or less lost. There is a single excretory opening, located in the middle dorsal line and almost at the extreme posterior end of the body (Fig. 3). The genital organs open by a common orifice, not separately, as stated by Leidy '58. This orifice is in the middle ventral line of the body (Fig. 4) near the level of the front of the ventral sucker. In addition to these openings there are the minute openings of the marginal organs, twenty in number (Fig. 4). The total length of adults taken from preserved specimens varies in 36 cases between 1.2 mm. and 1.8 mm., and the widths of these specimens between 0.6 mm. and 1 mm. *Cotylaspis* is thus the smallest member of the family; *Aspidogaster* comes next, 3 mm. × 1 mm., while the others are much larger, *Cotylogaster* being 10 mm. long, *Macraspis* 15 mm. long and *Stichocotyle* 105 mm. long at the maximum.

The ventral sucker is subdivided by strong ridges bounding deeply concave areas into a very characteristic number of acetabula. These are so located that we may recognize a peripheral series of twenty acetabula surrounding a median series of nine (Fig. 4). The two series are further so related that each median acetabulum has one of the peripheral series on each side, and there is one finally at each end of the series. This arrangement is like *Cotylogaster michelis,* excepting that at the ends in that form there are more than one acetabulum, and it is like *Aspidogaster* except that in it there is a double not a single median row. In *Stichocotyle* the ventral sucker possesses a single row of acetabula, and Jägerskiöld '99 states that *Macraspis* has a ventral sucker much like that of *Stichocotyle.* In general, in the Chau-

tauqua specimens the acetabula number 29 in all, 9 in the median series, 18 matching them in the peripheral series and the two median peripheral ones. In my former paper I called attention to the fact that Poirier's African species differed decidedly from this scheme, there being in the African form 7 in the median series, 8 in the corresponding peripheral rows on each side, or 16 in all, and then finally 2 median ones in the peripheral series; in all 25, as against 29 in the American form. In the case of *Cotylogaster* Nickerson has found that, while in Monticelli's species the lateral and median series correspond, in *C. occidentalis* these two series do not correspond.

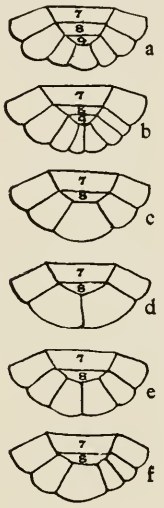

Diagram to show variation in the acetabula of ventral sucker. *a* is a copy of the posterior end of Pl. 1, Fig. 4. *b, c, d, e* and *f* are corresponding views. The numbers 7 and 8 occupy corresponding acetabula in each diagram.

The sucker shown in Fig. 4 of this article is not, however, the invariable form at Chautauqua. It is very general, but in addition to it I have found a number of variations, as indicated in the accompanying text figure. These deviations have never been found to occur in the anterior part of the sucker. They are shown in *b, c, d, e,* and *f, a* being a copy of the hind end of Fig. 4 of the plate. I have found the form *a,* which we may call the characteristic form, in 58 instances, besides having met it in many more non-recorded instances, and I have found the rest as follows: *b,* three cases; *c,* three cases; *d,* one case; *e,* one case; *f,* one case; in all there are nine cases that show variation. The variation may be in having only eight instead of nine acetabula in the median row; this fills the gap between this and the African species in that particular, or it may be in the peripheral series, where we may have an acetabulum doubled, as in *b, e, f,* or it may be the opposite that has occurred, and we find that an acetabulum has failed entirely to appear as in *d.* These variations bring the American and African forms nearer together, and unless we are assured that Poirier has not overlooked a posterior median acetabulum—an easy thing to do, since the walls of these acetabula tend to cohere and the last acetabulum is very small—we

cannot be sure that Poirier's account is not based on a variant form like the one in Fig. *c*.

Stafford '96 describes a cavity in *Aspidogaster* to which he gives the name "cervicopedal pit," located between the "neck" and the "foot," which runs backward some distance. A structure which is possibly related to this is described by Nickerson '99 as occurring in *Cotylogaster occidentalis,* where the front half of the body is "capable of being retracted telescopically, into the body proper." No such pit is found in *Cotylaspis,* as shown by sagittal sections (Fig. 6), and there is no power of retracting the front part of the body like that of *Cotylogaster.*

e. The Cuticle.

An unusually heavy cuticle envelops the entire worm and is infolded at all the orifices, viz., those of the mouth, excretory organs, marginal organs of the ventral sucker and the reproductive organs (Figs. 6, 7, 8). It is thickest dorsally on the body, 15 μ, and thinnest in the acetabula of the ventral sucker, 1 μ, and in the mouth funnel. Owing to its thickness it is thrown into wrinkles by the contractions of the animal, a longitudinal system appearing when the body is thrust forward and a transverse system when it is shortened (Fig. 2, *a*). It is as usual entirely devoid of cellular elements, and rests directly upon the muscular layer of the body wall. The outer portion is slightly darker colored than the inner, but there is no line recognizable between these. At all of the openings of the body the cuticle passes in and becomes directly continuous with the epithelium of the organ, as will be more fully noted in connection with those parts. There are certain foreign structures imbedded in the cuticle; these are parts of the glands of the parenchyma and certain structures which appear to belong to the sensory nervous system and can be better considered later. There are no hairs or hooks of any kind developed in connection with the cuticle anywhere.

f. Musculature of the Body-wall.

This has the usual form found in trematodes, and is much the same as reported by Stafford in *Aspidogaster* and by Nickerson in

Stichocotyle. I found that iron-hæmatoxylin stains the muscle fibers very deeply, so that it is possible to remove all the stain from the surrounding tissue and leave them deeply stained in strong relief. I also found that, by keeping living specimens in a weak aqueous solution of methylene blue, the muscle fibers were beautifully picked out. A tangential section (Fig. 9) shows the body-wall muscles in position, and discloses a circular layer next the cuticle, under them a longitudinal series and finally oblique fibers running in two directions. The fibers are never close together, but lie with considerable intervals between them in which the cuticle and the parenchyma are in contact. In methylene-blue preparations I could frequently see rounded nucleated cells (Fig. 11) lying beside the muscle fibers, which appeared to be identical with the myoblasts of Stafford (Fig. 26). In iron-hæmatoxylin preparations the circular muscle fibers were structureless but in both the longitudinal and the oblique fibers I found an appearance which is indicated in Figs. 9 and 11. In strongly decolorized preparations the fiber, 4 μ in diameter, could be seen to present two very distinct parts, an unstained portion imbedded in which were deeply stained elongate spots. This structure resembles that found by Nickerson in the longitudinal fibers of *Stichocotyle,* and indicated in his Fig. 16.

The arrangement of the body-wall muscles is altered at the excretory and genital openings, where the fibers form circular and radial muscles that are used in controlling the movements of these apertures. As already noted there is no oral sucker in connection with the mouth funnel, the body-wall muscles here are arranged in nearly the usual manner, and, not as in the ventral sucker, collected into special masses marked off from the parenchyma by a limiting membrance. The acetabula of the ventral sucker are due to the arrangement of the muscles there. These have the same structure as in *Aspidogaster* and are sufficiently described in Stafford's article on that genus.

The longitudinal and transverse muscular coats of the body-wall are continued inwards and backwards from the point where the body and the ventral sucker meet in the middle line, and thereby form (Fig. 5, 6, 7) a muscular partition, the diaphragm, which

divides the animal anteriorly into separated dorsal and ventral portions. The diaphragm fuses with the wall of the intestine ventrally on the level of the ovary, and behind this point the body is not subdivided by it as in front (see Fig. 8), which is in the plane *cd* of Fig. 6. A diaphragm running across the body underneath the intestine is reported for *Aspidogaster, Cotylogaster* and *Macraspis,* and appears to be wanting in the allied *Stichocotyle.* The diaphragm is not a characteristic trematode organ, not being found at all generally in the order. The relation of the vitellaria to the diaphragm is not the same in *Cotylaspis* and *Aspidogaster,* they being entirely below it in the former and, according to Stafford, dorsal to it in *Aspidogaster.* The other parts are related to it as in *Aspidogaster.*

The parenchyma muscles are long and often branched, as noted by Nickerson in *Stichocotyle,* and by Stafford in *Aspidogaster.* They are most commonly found in three situations, viz., (*a*) running across from one part of the body-wall to another when these come near together, *e. g.,* in the mouth funnel, and in the sides of the body between point where the diaphragm joins the side of the body and the ventral sucker. (*b*) From the pharynx to the body-wall long fibers stretch across the parenchyma, and doubtless these serve as protractors and retractors of the pharynx. (*c*) A third set of fibers are conspicuous in horizontal sections, running longitudinally as to the body among the vitellaria, often branching. I have not succeeded in recognizing the attachments of this system of fibers. The visceral portions of the musculture will be taken up in connection with the related organs.

g. The Parenchyma.

The parenchyma (Figs. 6, 7, 8, 12, etc.) fills the places around the organs, being somewhat denser where it is in contact with them (Figs. 7, 19) than elsewhere, as noted by Stafford in *Aspidogaster.* It is composed of the usual branching fibers and enlarged nuclei. In it unicellular glands are to be found. These are most numerous in the head region, on the sides of the pharynx, but they are also found in other parts of the body. They are flask-shaped (Fig. 13), in some cases the deeper portion measuring 20μ across, having a narrower neck which runs obliquely

toward the surface where it penetrates the cuticle to open to the outside, as in Fig. 13. The exact relation of the outer end of the cell and the cuticle I have not yet made out. The cell contains a finely granular material with no affinity for the hæmatoxylin stains, but tinging faintly with orange G. Each cell has a distinct nucleus, which is located on the margin of the cell in the deeper portion (Fig. 14). It is not compressed there as in many gland cells. In some instances fibers of the parenchyma muscles are in such relation with these cells as to suggest that they may, by contraction, discharge those cells.

h. The Alimentary System.

This is shown in Figs. 3–8, 15, 16, 17 and 18. It is not essentially different from that of the rest of the members of the family. The mouth, only slightly in front of the pharynx, projects into the mouth-funnel at its base. It is very distensible and is controlled by circular and dilator fibers (Fig. 15). There is a slight indication of a pre-pharynx. The pharynx has a flattened egg shape, its vertical diameter slightly exceeding the transverse. It is lined with a continuation of the outer cuticle, and composed of muscular fibers bound into a mass like that of the ventral sucker, and marked off from the parenchyma by a limiting membrane. It is crossed by branched muscle fibers, and on its surface are fibers running lengthwise and crosswise. It contains cells which resemble the parenchyma gland cells in appearance. There are long protractor fibers attached to its hinder end, which run forward through the parenchyma and are attached to the body-wall. Distinct retractor fibers were not seen, but indications of them are present.

The œsophagus is short and broad. Its wall consists of muscular fibers, and lying directly on these a layer of cuticle directly continuous with that of the pharynx. Internally this layer abuts directly against the epithelium of the intestine (Figs. 3, 6, 16). In view of the observations of Pratt '98 upon the cuticle of the appendix of *Apoblema,* where this layer passes underneath the epithelium, I have made a careful study of my sections at this point to determine if a similar relation exists here, but none of my sections will bear such an interpretation. I have also

noticed that in the cuticle there are elongate, slender, projecting pieces which, in life, look much like intestinal cells, but smaller, and which like them sway backward and forward with the contractractions of the animal. Sections show that these are parts of the cuticle. I have not found traces of nuclei in any part of the cuticle of the œsophagus.

There are numerous unicellular glands in the parenchyma surrounding the œsophagus, which differ from the parenchyma glands in being smaller, and in staining well. I have not succeeded in tracing ducts from these cells, and do not know whether they discharge into the œsophagus or farther forward into or in front of the œsophagus. Voeltzkow '88 and Stafford '96 describe similar structures as salivary glands. In *Aspidogaster,* however, the cells lie on the sides of the pharynx and discharge in front of it. Glands of this sort are common in the trematodes and terminate variously. In *Polystomum* (Zeller '72) they are postpharyngal in position, and, according to Braun, discharge into the pharynx posteriorly. Walter '83 describes two species of *Monostomum.* In *M. proteus* they are in a diffused mass surrounding the pharynx and intestine, while in *M. reticulare* there is a single compact mass on each side which discharges into the hinder part of the pharynx. In *Distomum palliatum* (Looss '85) these glands lie in a position exactly the same as in *Cotylaspis.*

The intestine, as in the rest of the family, is entirely simple; it is neither forked nor branched. Its wall continues the lines of the œsophagus unbroken. It lies in the center of the animal and extends posteriorly to a point a little in advance of the posterior end of the body. Its wall consists of two distinct layers, an inner epithelium and an outer muscular coat. The epithelium is composed of cells that are attached at the base only, and are entirely free from each other. They are very tall and slender, some measuring 105 μ in length and 10 μ across the base. Others are shorter and broader and have an appearance of contraction, perhaps owing to the action of reagents. They are frequently swollen at the free end, as in Fig. 16, and are always blunt and never acute at the tip, as indicated by Monticelli '92, Fig. 15, for *Cotylogaster michelis.* They are essentially alike in all parts of the intestine, and not sharply pointed at the anterior end and

much shorter posteriorly, as in *Macraspis* according to Jägerskiöld '99. In life these long cells sway about with the motions of the animal; at times those in front run out into the œsophagus as in Fig. 16, and at other times they point posteriorly. The cytoplasm of these cells is always minutely vacuolated, and generally there are large vacuoles in them. The most constant of these is one located at the free end of cell; besides it there are others at deeper levels. Each cell has a large nucleus generally located near its base, of a diameter of 5–7 μ, presenting a distinct membrane, a large deeply staining nucleolus and a small amount of chromatine in scattered grains. In a few instances I saw nuclei manifesting indications of activity, in which the nuclear membrane was wanting and in place of a clear nucleus there was a densely stained granular mass. The muscular coat of the intestine does not call for special remark. It consists of two layers, an inner circular layer and an outer longitudinal one (see Fig. 18). The fibers are scanty, especially those of the longitudinal layer.

i. The Excretory System.

The general arrangement of the parts of the excretory system is shown on the right side of Fig. 3. The main parts are:—a median single terminal pore, two globular bladders, almost entirely separate from one another, a collecting vessel running forward from the bladder to the level of the pharynx, a recurrent vessel running posteriorly to the level of the ventral sucker, an anterior and a posterior branch from the recurrent vessel, and capillaries running from flame cells to the anterior and posterior vessels. All these parts are visible in living compressed specimens, but the flame cells are very indistinct, owing to their small size and the thickness of the cuticle through which they must be seen. The bladders and collecting vessels can be studied in sections, but none of the rest of the system can be seen in sections or in any kind of preserved material.

The excretory pore is single and located on the summit of a low eminence at the hind end of the body (Fig. 5). The two bladders, which are entirely free from each other elsewhere, meet here and open into a short tube whose opening is the pore. The bladders are oval and decidedly larger than the collecting vessel

beyond. These parts are not the same in the family at large. In *Macraspis* there is a short unpaired bladder (as in trematodes generally); in *Aspidogaster* the collecting vessels are slightly swollen near the tips, and after meeting diverge and open by two separate and distinct pores; in *Cotylogaster occidentalis* there are two separate very thin-walled bladders with a single median pore, which opens at the base of the dorsal cone (Nickerson '99); in *Stichocotyle* the function of a bladder is assumed by the very large collecting vessels, which communicate with the exterior by means of two very narrow tubes which join and form a single short and very slender one. In all these cases the excretory opening is located posteriorly and dorsally. To return to *Cotylaspis,* the excretory pore is an indentation of the cuticle (Fig. 19) which leads by a short passage into the bladders. Their walls are lined in the parts nearest the exterior with a layer indistinguishable from the cuticle of the body in general, but in the deeper parts the lining is a true nucleated epithelium, which is directly continuous with that of the collecting vessel. Fig. 20, which passes through the junction of the collecting vessel and the bladder, leaves no room for doubt on this point. It is an important further fact that in the wall of the bladder, between the epithelium and the cuticle, we find cells (Fig. 21) in which the cytoplasm is still recognizable, but the nucleus shows signs of degeneration, and in place of a distinct nuclear membrane, nucleolus and scattered chromatine grains, we find a formless mass deeply staining and having the size and position of a nucleus. If we accept these as indication of cell-degeneracy, then in this place at least the cuticle seems to be a modified epithelium, a fact in harmony with the indications of its origin given by that of the œsophagus.

In addition to this lining the bladders possess muscular fibers, a distinct sphincter muscle can be seen (Figs. 18, 19), and in the wall are scattered longitudinal fibers continuous with those of the collecting vessel. The parenchyma condenses around the bladders, where we find a denser aggregation of fibers and nuclei.

In life the bladders simultaneously pulsate somewhat rhythmically. Pulsations were noticed in *Aspidogaster* by Huxley '78, who states that the entire collecting vessel pulsates, which is not the case in *Cotylaspis.* At the moment of contraction the pore

opens, after which it is closed and presents a puckering appearance, indicative of the action of the sphincter already noticed. The contraction is a quick systole, followed by a slow diastole, at the end of which a second contraction follows and so on. Counts of the seconds between a number of successive contractions were: 35, 28, 21, 29, 40, 35, 45, 20, 55 in one instance. Wright and Macallum '87 found that in *Sphyranura* the two bladders did not contract simultaneously, and that there was no constant rate; that the systole was slower than the diastole and did not obliterate the cavity of the bladder.

The junction of the excretory bladder and the collecting vessel are easily seen in life, and at this point I have clearly seen a valve which opened and shut in correspondence with the pulsations of the bladder. The collecting vessed runs in the central level of the body, and when it reaches the diaphragm it passes dorsally to it, and runs directly to the level of the pharynx (Fig. 3). This is very unlike *Aspidogaster,* where "the anterior ends of these vessels project far into the forward prolongation of the 'foot' (to within 0.10 mm. of its anterior border) and suddenly narrow to much smaller tubes which bend directly back along the collecting vessels before rising to the neck region" (Stafford '96, p. 33), and thus the vessel is beneath the diaphragm. In *Stichocotyle* the collecting vessel, though similar in location, is structurally unlike that of *Cotylaspis,* being very much enlarged and communicating with the exterior by means of a very much narrowed passage; instead of being smaller than the excretory bladder it is much larger and assists its function. In *Macraspis* the collecting vessel appears from Jägerskiöld '99 to be much as it is in *Cotylaspis.* The wall of the collecting vessel in *Cotylaspis* consists of a distinct epithelium with nuclei at frequent intervals. The cells are not flattened so as to leave the nuclei bulging, but contain considerable cytoplasm (Fig. 22). In no case have I been able to detect cilia or flagella in the collecting vessels, and I am convinced that they are wanting, though they are readily seen, as in Fig. 25, just at the point where the vessel passes into the recurrent vessel. The lumen of the collecting vessel is distinct, and I have examined it repeatedly for concretionary structures like those reported by Stafford, Nickerson and Pratt for *Aspidogaster, Stichocotyle* and

Apoblema, but without finding any. There are distinct longitudinal fibers in the collecting vessel wall (Fig. 22), though they are not very numerous. I have not seen any circular fibers, and believe that they are totally wanting.

The recurrent vessel is directly continuous with the collecting vessel, and of the same diameter, but it differs in being supplied with frequent strong flagella, as are all the rest of the vessels with the exception only of the capillaries next the flame-cells. The recurrent vessel does not receive any capillaries, but these enter its two branches, which form near the level of the ventral sucker (Fig. 23), and one of which runs forward and the other backward. All of the smaller draining vessels are tributaries of these forks. All these parts are supplied with numerous comparatively large flagella (Figs. 23, 24, 25, 26) located close to each other. The flagella are not visible in the freshly mounted animal, owing to their great speed, but later, through fatigue perhaps, they slow down and then become readily visible. Each one has a thickened base and tapers to a point at a distance from the base considerably greater than the diameter of the vessel. In motion they have the appearance of a rapidly turning screw, and must produce a strong current in the direction of the collecting vessel as all are located so that the free end is in that direction. I have not as yet succeeded in recognizing the cell-structure of the flagellum or of the cells in the walls of these vessels.

As already noted, the recurrent vessel here is not like it is in *Aspidogaster,* where it arises in the front end of the " foot " and first runs backward and then forward to the neck, when it returns and takes a posterior course, branching once in the anterior part of the body and then, near the middle, dividing into three branches instead of two as in *Cotylaspis.* Further, the recurrent vessel is smaller than the collecting vessel. In *Stichocotyle* (Nickerson '95) the recurrent vessels are still different; a small recurrent vessel arises (called by Nickerson " collecting tubule ") near the end of the large " excretory vesicle," which is the homologue of the collecting vessel of *Cotylaspis;* near the pharynx this vessel is supplied with flagella as in *Cotylaspis,* but it is represented as branching in a number of different places, and at these points is somewhat swollen.

The still smaller subdivisions of the excretory systems may be called the capillaries (Fig. 24). They can be seen dividing and when followed out to terminate in lesser divisions terminating finally in flame-cells. I have not been able to see these vessels to my entire satisfaction, but in places they are clearly visible. I have never seen them entering any vessels other than the anterior and posterior forks of the recurrent vessel. They do not appear to branch trichotomously, as they are thought to do in *Aspidogaster* by Stafford. I have not seen any indications of anastomoses between these or any of the parts of the excretory system, though such are found by Nickerson in *Stichocotyle,* and are mentioned by Braun '93 as being general in the order. These capillaries were flagellated, as are the larger vessels into which they run, but their tributaries, the ultimate capillaries, do not appear to be so. I have repeatedly examined them with an immersion lens, without finding flagella or cilia in the vessels, though they were seen distinctly in the flame-cell adjoining and in the capillary beyond. The flame-cells (Fig. 27) are funnel-shaped, small and very indistinct. They are 10 μ in length and 7 μ broad at the wide end and hollow within, where I could see a lining of numerous small active cilia, quite different from the large flagella of the vessels farther down. In appearance the flame-cells bear considerable resemblance to those found by Looss '92 in *Amphistomum clavatum,* and indicated in his figures 2 and 19. He states that the funnels in that species are open at the end and that the capillary leading from it is not ciliated, but the similarity ends here, as in *Amphistomum,* several of the non-ciliated capillaries meet and empty into a much larger ciliated vessel.

k. The Nervous System, and Sense Organs.

My knowledge of the nervous system is as yet very incomplete. There is a transverse commissure crossing above the pharynx (Figs. 3, 5 and 6). This runs down on each side of the pharynx and then branches, each giving rise to an anterior and a posterior branch. There is no considerable enlargement of the mass of nervous material at the meeting place of these trunks (Fig. 28), *i. e.,* no ganglionic concentration of nervous tissues. The anterior trunk is short and it soon disappears in the parenchyma of the

mouth region. The posterior trunk, however, can be traced in sections posteriorly to a point near the excretory bladders. The two trunks run widely apart, each lying near the margin of the flattened body. The structure of the trunks is wholly fibrous and faintly stainable; no indications of nerve cell bodies or nuclei are visible in them. Cells are, however, recognizable on the sides of the trunks which may perhaps be nerve cells, but I have not been able to see any fibers connecting them with the trunks, or to prove that they are nervous.

A pair of eyes are distinctly visible in young individuals, but they are absent in old ones. Attention is called to them by Leidy, who thought that they were functional in the fluke while in the mussel, but this cannot be considered as proved and, as I shall later try to show, is perhaps improbable. The eyes are located (Figs. 2, 2*b*, 3, 4, 28 and 29) at the front of the pharynx between it and the posterior nerve trunk. It is in close contact with the latter. After maturity the eyes gradually disappear, and in consequence we find all stages in the process, some with both eyes well-shaped, others with one eye replaced by a mass of disorganized pigment while its mate is still well-shaped, and still others with no eyes. In 52 cases of which I have preserved specimens or drawings both eyes are present in 29, none in 12, the left eye only in 8, the right being absent, and the right only, and the left had disappeared in 3.

The eye in the best conditions in which I have found it (Fig. 29) is a hollow cup of a diameter of 10 μ. The cup is open at one side and at the opposite side is thickened, growing thinner as you pass toward the open rim. The opening looks outward, forward and downward (Fig. 29). The wall of the cup is composed of minute grains of very dark brown, almost black, pigment, which in the mass looks black. With an oil-immersion lens one can see that these grains are separated and the indications are that they are imbedded in a non-stainable substance. In some cases the outlines of the cup are as distinct as in the drawing, a sharp line inside at the bottom being as distinct as indicated in the figure. I have not been able to recognize any lens in any of my specimens; one may have been present earlier and already degenerated. On the opposite side of the eye in some cases I have recognized a

nucleus (see Fig. 28), but have not been able to determine whether it really belongs to the eye or is merely one of the parenchyma nuclei accidentally so located. In other eyes the pigment is not so clearly arranged in the form of a cup, and yet the globular shape is retained, and in still other cases the pigment is shapeless.

These eyes and their degeneration are facts that must be interpreted in connection with any conception of the biological relations of *Cotylaspis* which we may adopt. Leidy explained them by correlating them with the ectoparasitic habit of the worm. But this interpretation is weakened by the fact that they degenerate in the anodon, and we are consequently forced to look for another. It is more plausible it seems to me to regard the degeneration of the eyes as an indication of a previous habit in which they were useful, such as a free life, or to fall back on phylogeny and explain them by recency of the derivation of *Cotylaspis* from free ancestral forms, such as the turbellarians. In favor of the latter interpretation is the somewhat generally accepted belief that the Aspidobothridæ are a very primitive trematode family, and this view is not incompatible with the other, that of a free existence prior to the occupation of the anodon.

Sections which cut the animal tangentially give surface views of the cuticle and show structures imbedded in it which appear to be nervous, and perhaps tactile. Their location can be seen by a reference to Fig. 30. They are not regularly arranged and are more numerous at the anterior end of the worm. A section shows them to be located entirely in the outer portion of the cuticle (Fig. 31), and in some cases a distinct conical elevation of the cuticle surrounds the outer part of the organ. It consists of an oval, homogeneous, solid, central portion occupying a space which is supplied in its wall with several stainable threads of granular substance, all arising from a common center at the base. These threads are seen in surface views as a ring of minute points (Fig. 30), and have every appearance of being nervous. At the base of this structure a single stronger thread passes through the remaining portion of the cuticle and is lost in the parenchyma. I regard is as the nerve, though I have not been able to connect it in any case with an undoubted member of the nervous system. Sense organs in the cuticle have been reported by Blochmann '95, certain of

which, as his figure 5*a*, present considerable resemblance to these, and in which he is able, not only to recognize an oval cuticular portion located in a low papilla of the outer cuticle, but also a nerve fiber which as here pierces the cuticle and then runs inwards to connect with a nerve cell in the parenchyma. As his studies are also on the trematodes, I think that it is reasonable to base on them the identification of the cuticular structures of *Cotylaspis*.

l. The Marginal Organs.

Certain organs of problematical function have been recognized in some of the Aspidobothridæ called "marginal organs." They are found in *Cotylaspis* on the margin of the ventral sucker at the points where the walls of the acetabula meet it (see Figs. 3, 4, 5, 7, 8). There is one of these organs at each such meeting point, so that the total number of organs in one animal is ordinarily twenty. They lie in a triangular space at the junction of the three masses of muscular tissue, surrounded by parenchyma. In surface views of the living animal, as the movements have favored it, I have been able to see at the points indicated in Fig. 4 the minute openings of these organs by which they communicate with the exterior (Fig. 32). The organ consists of two distinct portions, a lower one nearest the outer surface and a deeper portion above the first. These two parts are both oval and of about the same size, viz., about 30 μ long by 20 μ wide. The structure of the two, as seen in sections stained with iron-hæmatoxylin, is very different. The lower part has a distinct narrow central passage lined with a continuation of the outer cuticle, which passage can be seen in some sections to pass entirely through the outer part of the organ and enter the upper part, though this is not visible in the section from which the drawing is made, owing to the fact that the organ curves. Beyond this narrow duct the wall of the lower portion is very thick and is composed, largely at least, of muscle fibers, some of which are visible in some of the sections attaching to the central passage below and into the upper portion of the organ above. In addition circular muscles can be seen surrounding the narrow duct. The upper part of the organ is hollow, but its cavity is large and the wall relatively thin. The cavity as here is a constant feature of this

part, but in some cases I do not find anything in it, and in other instances there is a sort of concretionary structure like that in the figure. As this is not found constantly it can hardly be considered an essential feature of the organ. The wall of this chamber is composed of the two coats; next the space a coat which has somewhat the appearance of both a cuticle and an epithelium. It contains nuclei but cell boundaries are wanting and the substance does not look actively protoplasmic. I am inclined to consider it a degenerated epithelium. On the outside of this layer distinct longitudinal muscular fibers are visible in many sections. There do not appear to be any circular muscles here. Beyond the upper part of the organ I find a mass of non-staining fine parallel threads which have the same appearance as the nerve trunks in other parts of the same series. Monticelli indicates a similar structure in his figure 8 of plate XXIII. of *Cotylogaster,* and regards it as a retractor muscle, but I am not able to recognize any muscular fibers in it, though these are demonstrated in other parts of the organ very clearly, and this speaks against that identification. Monticelli, in his idealized figure, indicates that the upper part of the organ is entirely closed. I do not agree with this opinion, since I can, in certain sections, trace a direct continuation from the surface opening up to the cavity of the upper organ, and besides, as stated above, I sometimes find concretions in the cavity of the upper organ as in *Cotylogaster* (Fig. 13), and at other times do not. The latter I attribute to escape of these, and this implies a passage to the exterior.

Monticelli suggests that this organ in *Cotylogaster* is a tactile organ and that it is used to determine by pressure if a surface is a suitable one for the adhesion of the ventral sucker. Voeltzkow also reports the organ in *Aspidogaster* and suggests that it is there an organ of touch. Nickerson finds a similar organ in *Cotylogaster occidentalis,* and he takes a different view of its function and inclines to the opinion that it is not a sense organ but a secretory organ. I have not as yet ascertained any facts which decide the matter. The large amount of muscular tissue in the organ indicate its capacity for protrusion, though I have never been able to get a view of it protruded, and the nerve going to it indicates tactile function, but on the other hand it does not have the

appearance of a sensory organ and its anatomical structure is more that of a gland, for instance its hollow upper part and the narrow passage connecting from it to the exterior. And so is the fact that the upper cavity contains deposits of varying character, having the appearance of a concretion that had been produced by the cells. But, on the other hand, the epithelium looks very unlike an active glandular epithelium, and the size of the nerve seems unexplained if the organ has that function.

We do not know whether there are marginal organs in *Platyaspis lenoiri* of Poirier '86 or not. His account makes no mention of them, but his paper is very brief and we have no means of knowing how exhaustive his studies were. It is not at all impossible to suppose that they are present and that he overlooked them, for they are very small and would be easily overlooked, especially in many methods of preparing the specimen. The general anatomical similarity between that form and Leidy's make it strongly probable that they are identical generically. The points are: The entire anatomy of the reproductive system, which is different in each genus of the family, the character of the ventral sucker which differs in each genus, the form of the body which is also somewhat characteristic, and the mouth funnel which is characteristic. The absence of eyes is not an objection now that we know that they are absent in older specimens of *Cotylaspis*.

m. The Reproductive System.

i. *General Statement.*

Some or all of the parts of the reproductive system are shown in Figs. 3–8 and 33–62. There is a single generative opening which is located in the mid-ventral line of the body a little distance in front of the ventral sucker (Fig. 4). This gives entrance to a very short passage which divides and leads to the cirrus on the right and the uterus on the left (Fig. 33). The general plan of the system is as follows (Fig. 3). In the male system there is an eversible penis or cirrus (Fig. 34) enclosed in a sack lying on the right side just behind the external orifice. A seminal vesicle runs from this under the intestine to the left side where, after a more or less wavy course, it ends near the center of the body. A very slender spermatic duct passes from the inner side of the seminal

vesicle, crosses to the right side of the body under the intestine and runs backwards to the spermary which is a single large globular organ located under the intestine and near its posterior end. In the female system we find (Fig. 3) a winding uterus enlarged at intervals by the enclosed eggs. The uterus may pass from the left to the right side under the intestine, or it may be shorter and remain on the left side, but in either case it finally passes from the left to the right under the intestine and thus reaches the yolk duct, passing on as the oviduct and " tuba fallopii " to finally reach the ovary. This lies under the diaphragm on the right side. The only organ entering the passage to the ovary is the duct from the yolk receptacle, there being no shell glands or Laurer's canal. The yolk receptacle is a triangular chamber at the junction of the right and left ducts from the vitellaria, which are a number of small glands on each side of the body close to the ventral surface. A detailed account of each of these parts will now be given.

ii. *The Male Organs.*

The spermary is single as it is in *Aspidogaster* and *Macraspis,* while in *Cotylogaster* and *Stichocotyle* there are two. It lies directly below the intestine (Sp., Fig. 8) and a little in advance of its posterior end. It is just above the muscles of the ventral sucker, below the excretory collecting vessel, and behind the yolk receptacle. In specimens under compression it is pushed aside by the intestine and generally appears on its right. It is spherical and its diameter varies between 0.26 and 0.18 mm. It has a distinct wall (Fig. 37) in which are scattered nuclei, and in which muscular fibers are recognizable after iron-hæmatoxylin staining. This muscular tissue is very scanty unlike *Aspidogaster,* in which Stafford finds a longitudinal and a circular layer. A layer of cells lies in contact with the wall, parietal cells (Figs. 38 and 40), and the interior is occupied with free *" central cells"* which show stages of spermatogenesis in some of my series. The latter are developed from the former. Two stages of the organ have thus far come to my notice, viz., a " resting stage," in individuals killed in May, and an " active stage," in animals killed in July and August. In the former, the resting stage, the parietal cells, as in Fig. 38, show a large and distinct nucleolus excentrically located

in a faintly stained mass which occupies most of the cell, and which appears to be the nucleus. In some cases there is a faint indication of a nuclear membrane nearly coinciding with the cell boundary. Nothing that I can identify as chromatine is seen in these cells. In July the parietal cells are very different, as seen in Figs. 37 and 40, when a small amount of cytoplasm can be seen, and in it a nucleus filled with deeply staining chromatine and a grain in the cytoplasm which has the appearance of a centrosome. The central cells in the resting spermary are much larger than the parietal, Fig. 39 is drawn from one of them in the same section as Fig. 38 and with the same magnification. There is a considerable amount of cytoplasm, and a nucleus of the same texture, with a nuclear membrane which is only seen by using the most careful illumination. In these cells deeper stained grains on the edge of the nucleus are probably cromatine. These cells are not apparently in groups as in the active organ. Fig. 37 is a camera lucida drawing of the active spermary. It shows active parietal cells in a layer around the edge; generally they are in a single layer though in places they are more numerous, and the center occupied by cells very different in character from those on the wall, being often in groups and presenting certain nuclear differences of importance. These central cells are in the act of spermatogenesis, some of the phases of which are clearly indicated.

In so far as I have been able to interpret the spermatogenesis from my material the order of the events is indicated by the order of the drawings in the plate. The parietal cells become active (40) and detach themselves from the wall (41); the nuclear material divides without the division of the cell, forming a syncytium, increasing very much in size (42). This then passes toward the center of the spermary and the nuclei take the position seen in Fig. 43 and cell boundaries begin to appear on the periphery, but the mass is still one in the center, like the centro-lecithal segmentation of some arthropods. At this stage, of which very many cases can be found (see Fig. 37), there are generally about six rather large cells in the transverse section. Each of these cells has an abundant cytoplasm, and a nucleus which is filled with chromatine in the form of a fine network in contrast with the small number of distinct loops as shown in Fig. 41. No nucleolus occurs in these cells.

In some, *e. g.*, Fig. 46, I find deeply stained spots in the cytoplasm, which by more extended studies I may be able to prove to be centrosomes; they have the appearance and position necessary to that identification. I have not succeeded in recognizing intermediate stages between 42 and 43. There are syncytia composed of double the number of nuclei as 43; one of these is shown in 44, and in these there is a more distinct indication of the formation of walls between the nuclei and the cutting off of the base of the cell from a central residue of the original mass of cytoplasm. Fig. 47 is a stage of this in which four of the cells are indicated as being in the same condition of karyokinesis at the same time, viz., the metaphase. Isolated cells from similar situations are shown in Figs. 48 and 49. It has not been possible to study the chromosomes in detail; there seem to be a small number. I incline to identify the cells of this stage as the spermatogones. They divide and double the number, as shown in Fig. 44, where the cells are smaller. They show a smaller and much denser nucleus, and in some cases the nuclear material is drawn out into elongate shapes, as in Fig. 45, which I am inclined to regard as the spermatids, early stages in the formation of the spermatozoön, and thereby to identify these cells as the spermatocytes. I have only in one or two places seen indications of the presence of spermatozoa, and have been inclined to suspect that the season was not right for them.

So far as I am aware the history of the spermatic cells is not known for any of the Aspidobothridæ and it is not recorded for many of the trematodes. In so far as I am acquainted with it the process in general seems much the same as here, as indicated by the figures of Schwartz '86, Wright and Macallum '87, and Heckert '89. In all of these parietal and central cells are found, clusters of cells by division double the number from spermatogones to spermatocytes and the nucleus of the latter gives rise to the spermatozoön. It is also noticeable that the precess as I have indicated it agrees rather closely with the process as it takes place in the earthworm according to Calkins '95, whose Figs. 4 and 5 bear much resemblance to my Figs. 43 and 44. I find, however, that the central mass, corresponding perhaps with the "blastophore" of his paper, is not connected with the cells as long. In his this

connection persists even to the spermatid stage. In my Fig. 45 the cells are not distinctly separated centrally, but in other clusters, as in Fig. 47, they are distinctly so at the spermatogone stage. In such cases there is no nucleus in the central mass.

The spermatic duct is exceedingly slender, and for a long time escaped my observation. It is recognizable by the presence in its distal end of two or more small concretionary bodies which appear to be constantly present. The duct leaves the anterior side of the spermary and runs forward, crosses the body and passes into the spermatic vesicle, not at the end of the latter, but at its inner side a little in advance of its termination (Figs. 3, 35). This is quite unlike the facts as indicated in Poirier's figure of the African form, where there is no distinction between seminal vesical and sperm duct, a passage of the same dameter running, according to him, from the cirrus to the spermary. In *Aspidogaster* the sperm duct is smaller than the seminal vesicle, but it enters the end of the latter and not its side. The concretionary structures referred to are not found in the spermary or in any other part of the sexual apparatus. They are large and distinct, and consist of a dark stainable interior surrounded by an outer translucent non-stainable portion. One of them from a section is shown in Fig. 36. I have not been able to account for them, and do not find mention of anything similar in other trematodes. The seminal vesicle is very variable in diameter and length in different cases. In all cases that I have seen it is either empty or contains a fine-grained material in which no structures could be recognized. In no case could I recognize any spermatozoa in it. Its wall is composed of nucleated cells, and muscle fibers are recognizable in it. It enters the cirrus sack posteriorly and on the right side. At this point and around the cirrus sack in *Aspidogaster* there are prostatic glands, but I have not distinguished such in *Cotylaspis*. The cirrus sack is oval and measures 0.26 mm. by 0.17 mm. It has a muscular wall enclosing somewhat loose cells having much the appearance of parenchyma, surrounding the cirrus in the center (see Fig. 34). The latter communicates anteriorly with a sheath by means of which the cirrus is everted, and posteriorly with a continuation of the seminal vesicle, which enters the sack posteriorly. The cirrus is walled by a muscular coat in which strong and numerous fibers are

visible and an inner coat of distinctly nucleated cells. Anteriorly the cirrus narrows where it passes into the much enlarged sheath whose wall is slightly muscular, and in addition is lined with a transition type of cells between the epithelium of the cirrus and the outer cuticle, in direct communication with which it stands through common genital passage and the genital opening (*cf.* Fig. 33). The inner part of the system of passages is narrow, and slightly wound to permit eversion of the organ. In *Aspidogaster* there is a very complex system of folds in the cirrus sack which are thought to be employed in everting the cirrus, but nothing like them can be found here. I have not at any time seen any indications of activity in the cirrus, and this, taken in connection with the virtually entire absence of spermatozoa in my material, would encourage the supposition that the male organs are not in action in July and August.

iii. *The Female Organs.*

The ovary is always located on the right side directly under the diaphragm and on the level of the center of the ventral sucker (see Fig. 31). It is elliptical and varies in length (in thirteen cases killed under compression and mounted in balsam) from 0.1 mm. to 0.3 mm. In *Aspidogaster* the organ is said to measure 0.35 mm. in length. Its width ranges from 0.07 mm. to 0.13 mm. It consists of two portions which (Fig. 50), from the point of view of the contained ovarial cells, are very distinct, viz., an anterior part containing very large cells in close relation with the beginning of the oviduct and a deeper posterior portion in which the cells are small and more immature. The ovary is enclosed in a very thin but perfectly distinct wall in which much flattened nuclei can be seen at wide intervals. Stafford considers this layer in *Aspidogaster* to be a flattened parenchyma. I have seen nothing in *Cotylaspis* to indicate its source. The wall contains some muscle fibers, but they are not very numerous. The cells inside this wall (see Fig. 50) do not form any distinct epithelial layer. As is usual among the trematodes the cells show stages of development as you go toward the oviduct. I have not traced the stages of ovigenesis completely, but the following observations have been made. There is posteriorly a peripheral layer of cells (Fig. 52) in contact with the outer wall. They are small, have a large nucleus

.006 mm. in diameter, and consist of a nuclear membrane, scattered and indefinite chromatine in small grains, and a nucleolus. The nucleus nearly fills the cell and the cytoplasm is small in amount. These cells bear a close resemblance in size, position and structure of the primitive cells of the spermary. The center of this portion of the ovary is occupied with a type of cell shown in Figs. 53 and 54, doubtless derived from cells of the sort just described, which show different stages of mitotic division. In the center of the ovary we find much larger cells (Fig. 55) with a nucleus of a diameter of .01 mm., in which a distinct membrane encloses a large nucleolus which is a center of a system of minute threads on which minute grains of chromatine are arranged. These cells have a large amount of cytoplasm of a fine-grained homogeneous texture completely filling the faint but definite cell membrane. These cells are much crowded which results in the production of the characteristic wedge shape. They fill this region of the ovary completely, to the entire absence of the parietal cells of the deeper portion of the organ. In the anterior part of the organ the cells (Fig. 56) attain a size of .033 mm. The nucleus now is still larger (.015 mm. in diam.) and the nucleolus is very large, .004 mm. The granular chromatine is very scanty in amount. The cytoplasmic portion of the cell, unlike the preceding stage, is greatly vacuolated. This condition does not appear to be artificial, since it is found in specimens hardened in a great variety of reagents, corrosive, picro-nitric and chrom-osmium-acetic. Cells of this sort are seen in some of the sections in the act of descending into the "fallopian tube" as Voeltzkow called the following upper part of the oviduct in *Aspidogaster*. As it is probably in the "tuba" that fertilization takes place (*vid.* Stafford '96, p. 49) one would expect that the maturation of the egg would occur in this part of the ovary itself or in the tube leading to the upper part of the "*tuba.*" I have not, however, as yet been able to observe any ova in this situation in which there is any indication of nuclear activity.

The position of the ovary in *Cotylaspis* is just the reverse of that in *Aspidogaster,* where the deeper portion is anterior and the part next the "tuba" is posterior. This difference involves only the ovary and the upper part of the tuba, which in *Aspidogaster* is suddenly bent on itself in the middle, while in *Cotylaspis* it is straight.

The "tuba" resembling that found in *Aspidogaster,* is a very peculiar modification of the portion of the oviduct next the ovary, resulting in the production of a series of connected chambers possibly used in lodging the egg during the processes of maturation and fertilization. It consists (Fig. 51) of a somewhat dense wall infolded at intervals transversely to form a sort of diaphragm open in the center. This denser part is covered with a cellular portion, the nuclei of whose cells are readily seen. There are no cilia in the "tuba"; they are readily seen in the adjoining oviduct. I have never succeeded in seeing ova or spermatozoa in these parts, though it is probably here that fertilization takes place. I have found fully formed eggs, composed of egg-cell, yolk cells and shell, in uterus just beyond the yolk-duct, and these must have been recently formed. As I have not paid special attention to this point it is possible that I may yet be able to get some points in the history of the formation and fertilization of the egg. I have not succeeded in recognizing any muscular tissue in the walls of the tuba even in sections in which the muscular fibers were particularly distinct elsewhere.

The oviduct (Fig. 3) beyond the "tuba" runs first posteriorly, where it receives the duct from the yolk receptacle, then transversely to the left side beneath the intestine, then with a winding course forward remaining mostly or wholly on the left side. It runs obliquely dorsally through the diaphragm and then runs to the genital pore, where it opens to the exterior. The part of the oviduct next the tuba for a short distance is ciliated, but the remainder of the passage is not. It is lined everywhere with nucleated cells which are clear, tall and strongly nucleated where the tube is not cilated, but in the dilated portions which contain the eggs the wall is of greatly flattened cells whose nuclei are elongate. In the beginning of the uterus muscle fibers do not appear to be numerous if they are present at all, but in most of the passage they are very evident and in two distinct sets transverse and longitudinal. The passage is slightly longer than the body, and hence is somewhat coiled, but this is not carried to the great degree that is found in some of the trematodes. It ends at the genital opening where it always comes in from the left opposite to the position of the cirrus sack. In this terminal por-

tion of the oviduct at the genital aperture the epithelium so evident elsewhere in the passage changes to cuticle and is continuous with that of the general surface of the body. The oviduct receives only one duct, that from the yolk receptacle, which enters it at a point very near to the ovary. In many trematodes a duct opens into the oviduct between the entrance of the yolk-duct and the ovary, the Laurer's canal. I have examined this region very carefully without being able to recognize any indication of such a passage in *Cotylaspis*. Laurer's canal is somewhat rudimentary in *Aspidogaster,* where, in the mature form, its outer end does not open to the exterior as in trematodes generally, where it is present, and it is stated by Nickerson to be absent in *Stichocotyle,* and is absent from *Cotylogaster.** Laurer's canal at best seems to be a very variable structure, opening in some cases to the exterior, in other cases to the intestine, in still others ending blindly and in still others being wholly absent. It is present in one species and absent in another closely related one, *e. g.,* in the genus *Distomum*.

This location of the vitellaria is shown in Fig. 3. They are made up of a comparatively small number of flask-shaped follicles, all of which lie so as to open toward the center of the body. The follicles differ in number in different cases; in nine different flukes I counted them as follows: 70, 72, 76, 80, 84, 90, 105, 110. They are approximately equally divided between the right and left sides. All of them underlie the diaphragm (see Fig. 7), and in this regard are different from *Aspidogaster,* in which these follicles all lie dorsal to the diaphragm. Stafford shows (Figs. 11, 12, 25) their ducts piercing the diaphragm to communicate with the rest of the reproductive system which is under the diaphragm. The ducts leading from the follicles are ordinarily invisible, but can be demonstrated by making the yolk cells flow in them by pressure. They lead to a right and left main duct, which at last enters the yolk receptacle just in front of the spermary. The follicles themselves (Fig. 57) measure from .05 to .08 mm. in width and .08 to .13 mm. in greatest length. Those of a particular animal are of nearly the same size; possibly their difference of size in different animals is due to functional conditions, but the cells in all have the

* According to Monticelli, but Nickerson (Zool. Jahrb., XV., Syst., p. 611, 1902) finds it present in the American species *C. occidentalis.*

same appearance. The follicles are bounded by an extremely delicate structureless wall, enclosing a number of yolk cells in various stages of growth. The smallest and earliest cells (Fig. 58) have a diameter of .01 mm. and bear considerable resemblance to the youngest ova, having a large nucleus with a large nucleolus, scattered grains of chromatine and a small amount of cytoplasm. Besides these there are larger cells in which the cytoplasm is more abundant and is beginning to be pervaded with minute droplets of yolk. There are also in the follicles still larger cells, of a diameter of .02 mm. (Fig. 61), where a cell wall is seen and next it a layer of yolk droplets, then a hollow space, and then a central mass of protoplasm with a nucleus. This is the final form of the yolk cell, in which it passes down to and is found in the yolk receptacle.

The yolk receptacle lies between the ovary and the spermary. It is a triangular cavity, two angles are at the junction of the two ducts from the vitellaria, the third angle being at the origin of the passage leading out to the oviduct. The wall of this organ can be traced in living specimens under compression out into the three different ducts and by pressure the contents can be forced out through the ducts. The wall in sections is seen to be distinctly cellular as indicated by the presence of flattened nuclei, unlike that of the vitellarian follicles in which nuclei can not be recognized. I have not observed any muscular tissue in this wall in specimens in which it is easily seen in the oviduct. The yolk receptacle is filled with yolk-cells identical in appearance with the largest cells in the vitellaria, which clearly have merely been collecting and waiting here till an egg cell shall descend, when they will join it, and in the oviduct near by acquire a shell, thereby completing the egg. In many of the trematodes there are two organs at or just beyond the junction of the yolk-duct and the oviduct, the ootype in which the embryo is formed and the shell gland, a gathering of cells surrounding the ootype which produces the substance of which the shell is composed. I have not succeeded in recognizing either of these as distinct organs in *Cotylaspis;* doubtless here the ootype is never more than a slightly specialized part of the oviduct. Thus in *Macraspis* Jägerskiöld '99 refers to it by name, though in his figure no distinct part is represented to correspond. According to Stafford a distinct enlargement of the oviduct is found just

beyond the junction of the yolk-duct in *Aspidogaster* with much thicker walls "lined with high epithelium cells" and surrounded by unicellular glands which contribute the shell substance. I have not been able to find a similar organ in sections of *Cotylaspis.*

The eggs are lodged in swollen places in different parts of the uterus beyond the entrance of the yolk-duct. These places are not constant in location, and seem to be formed temporarily to accommodate the egg. I doubt if the eggs remain stationary in passage, but think it more likely that they are slowly moved along and thrown out of the animal. In some cases I have seen an egg close to the beginning of the uterus and supposed that this was the place of its formation, but have never seen one in process of formation. The number of the eggs is always small; there are never more than thirteen present at one time in any of the cases that I have recorded, and generally less. In *Aspidogaster* they develop in the uterus to the point where the young worm is moving about within the shell and is ready to emerge (Voeltzkow '88, p. 272). In *Cotylogaster occidentalis,* according to Nickerson '00, "the eggs when discharged . . . contain a fully formed embryo with unforked intestine and simple subterminal sucker at the posterior end. The body of the embryo is covered in part with a simple epithelium bearing distinct tufts of cilia." But in *Cotylaspis* the egg has not undergone the first segmentation by the time it leaves the parent.

When the mature worms are removed from the mussel and placed in aquaria they generally soon expel a number of eggs, or can be compelled to do so by carefully managed compression. These minute embryos were transferred by means of a capillary pipette under a simple microscope to the center of a slide, where they were covered and submitted to microscopic examination. Fig. 63 is a camera lucida drawing of one of these, and shows its condition as it leaves the parent. Eggs were also seen and studied *in situ* both in the living parent and in preserved states, both in whole preparations of the parent and in sections. Isolated eggs were kept in aquaria from which they were transferred from time to time to slides for examination.

The eggs in *Cotylaspis* are unusually large, measuring in length from .22 mm. to .35 mm. and in width from .10 mm. to .16 mm.

In *Aspidogaster* they are stated by Voeltzkow to measure .127 mm. by .061 mm.; this is less than half as large as the corresponding dimensions in *Cotylaspis*.

They are of a lemon-yellow color, and are curved as in Fig. 63, which slight bend in the long axis is a very constant characteristic. Near one end is located an operculum, and by irrigating a slide containing embryos with acetic acid I could observe the bursting off of the operculum and the issuing out of the yolk cells, owing to the pressure within. In some cases I found an operculum at each end. The embryo, as usual, consists of a single approximately centrally located embryo-cell, and a surrounding mass of numerous yolk-cells. The spherical embryo-cell measures .04 mm. in diameter, and up to the time it is passed out from the parent shows no outward indications of segmentation. In living eggs it is clear and structureless; the nucleus cannot be seen, but in sections this cell, which can be identified by its central position, size and structure, has a distinct nucleus, and in some cases two or even four nuclei were seen. But in no case were two such embryo-cells visible in the embryo, which must be a conclusive proof that the segmentation does not take place in the body of the parent. In this *Cotylaspis* is quite unlike the rest of the known Aspidobothridæ.

The yolk-cells have distinct boundaries rendered nearly invisible by crowding (see Fig. 63). They are numerous and considerably smaller than the embryo cell (.025 mm. in diameter). They look quite unlike the yolk-cells of the yolk receptacle having a clear peripheral zone and a denser central zone, in the center of which is the nucleus (Fig. 63). This contrasts strongly with the cell before it has become incorporated with the embryo, in which distinct grains of yolk are seen and located at the periphery of the cell, and may be an indication of the beginning of changes related to the nutrition of the egg-cell.

An attempt was made to follow the development of the embryo, but only a very little has been gotten as yet. As already stated, the egg does not develop in the parent. By keeping recently discharged embryos under observation from day to day I found that the egg-cell begins to segment, and that its development progresses as shown in Figs. 66–74. These indicate a total segmentation at

an exceedingly slow rate which, however, may be abnormal. They extend to the formation of a morula at the end of three days, and at that time the growth altogether ceased in every instance. My knowledge of the form of the animal after Fig. 78 is an entire blank till the definitive form is reached. The youngest specimens that I have found in the mussel had the outward form of the parent established except with regard to the completion of the ventral sucker, and internally it was like the adult except that no indication of the genitalia was visible. Such specimens are found in the fluids that flow out from the mantle cavity on opening the mussel, and are also found in the mucus that can be scraped from the surface of the foot and the gills in the neighborhood of the kidneys.

Since the eggs are enclosed in their shell in the upper part of the oviduct it seems clear that they are fertilized before they leave the parent. In that case the standstill to which they come cannot be due to internal causes, and must be due to external ones. Since the egg is supplied with the yolk-cells presumably to serve as food, and is protected from the effect of environmental conditions by its shell, it is very difficult to see to what the non-development is due. There is thus a lost interval coming between the early segmentation and the young animal with the chief organs of which we know nothing. The presence of the eyes might lead us to suppose it passes through a period of free life at this point, and its primitiveness among the trematodes would be in harmony with this hypothesis. But how are we to explain the non-development of the eggs on this basis? It is such eggs that ought to be the easiest to rear. If there is not a free stage then we must look for a host, either the mussel itself or an intermediate host. There is precedent in the family for the latter from the case of *Stichocotyle,* Odhner '99 having recently shown that that form has two as had been long surmised. At present however we are not in a position to attempt to fill in the interval by means of any adequate hypothesis.

Biological Laboratory, Hamline University,
March 3, 1900.

LIST OF REFERENCES.

'95. **Blochmann, F.**
Ueber Muskulatur und Sinneszellen der Trematoden. Biol. Cent., XV., p. 216.

'93. **Braun, M.**
Trematoden. Bronn's Klass. u. Ord., IV.

'89. **Heckert, A.**
Unters. u. d. Entwik. u. Lebensgesch. des Distomum macrostomum. Bibl. Zool. Leukart u. Chun, IV.

'78. **Huxley, T. H.**
The Anatomy of the Invertebrated Animals.

'99. **Jägerskiöld, L. A.**
Ueber den Bau von Macraspis elegans. Ofvs. Kongl. Vet. Akad. Forhandlengar, III.

'99. **Kelley, H. M.**
Statistical study of the parasites of the Unionidæ. Bull. Ill. State Lab. Nat. Hist., V.

'99. **Kofoid, C. A.**
Identity of Cotylaspis insignis Leidy and Platyaspis anodantæ Osborn. Zool. Bull., II.

'57. **Leidy, J.**
Observations on the entozoa found in Naids. Proc. Ac. N. S. Phil., Ser. 2, pt. 1.

'58. **Leidy, J.**
Contributions to Helminthology. Proc. Ac. N. S. Phil., Ser. 2, pt. 2, no. 10.

'85. **Looss, A.**
Beit. Kentn. Trematode Distomum palliatum. Zeit. f. w. Zool., XLI.

'92. **Looss, A.**
Ueber Amphistomum subclavatum, etc. Festchr. für Leukart.

'92. **Monticelli, S.**
Cotylogaster michelis. Festschr. für Leukart.

'95. **Nickerson, W. S.**
On Stichocotyle nephropis. Zool. Jahrb., VIII.

'99. **Nickerson, W. S.**
Concerning Cotylogaster occidentalis, nov. sp.; a preliminary notice. [Manuscript of article read at meeting of Naturalists in Chicago.]

'00. **Nickerson, W. S.**
Concerning Cotylogaster occidentalis. Science, XI., p. 250.

'98. **Odhner, Th.**
Ueber die gesch. Form von Stichocotyle. Zool. Anzeiger, XXI.

'98. **Osborn, H. L.**
Anatomy of Platyaspis of Lake Chautauqua. Zool. Bull., II.

'86. **Poirier, J.**
Trematodes nouveau ou peu connus. Bull. Soc. Philom. Paris, Ser. 7, vol. X.

'86. **Schwartz, W.**
Die postembryonal Entwik. der Trematoden. Zeit. f. w. Zool., XLIII.

'96. **Stafford, J.**
Structure of Aspidogaster conchicola. Zool. Jahrb. Anat., IX.

'88. **Voeltzkow, A.**
Aspidogaster conchicola. Arbeit. Inst. Wurzburg, V.

'93. **Walther, E.**
Unters. u. Bau d. Trematoden. Zeit. f. w. Zool., LVI.

'87. **Wright, R. R., and Macallum, A. B.**
Sphyranura osleri. Am. Journal of Morphology, I.

'72. **Zeller, E.**
Bau u. Entwik. Polystomum integerrimum. Zeit. f. w. Zool., XXII.

ABBREVIATIONS.

The same reference letters are used in all the figures.

A. Vs. Anterior branch of recurrent vessel.
Bdy. Body
Cap. Capillary.
Cl. Ch. Cloacal chamber of host.
Col. Vs. Collecting vessel of excretory system.
Con. Concretion.
Cot. *Cotylaspis in situ* in host.
Cr. Cirrus.
Cr. S. Cirrus sack.
Cr. Sh. Cirrus sheath.
Cut. Cuticle.
Cy. Cytoplasm of cell.
Dpm. Diaphragm.
Eg. Egg in uterus.
Ep. Epithelium.
Ex. Bl. Excretory bladder.
Ex. Po. Excretory pore.
Ex. V. Excretory vessel.
F. Foot of host.
Fl. Cl. Flame cell.
G. Po. Genital pore.
I. Br. Inner gill of host.
Int. Intestine of *Cotylaspis.*
Int. Ep. Intestinal epithelium.
Lb. Pl. Labial palpus.
Lat. Com. Lateral compartment of ventral sucker.

L. Nv. Lateral nerve.
M. Mouth.
M. F. Mouth funnel.
Man. Mantle of host.
Mg. Or. Marginal organ.
Mu. Ad. Adductor muscle of host.
Mu. Muscle fibers.
Mu. dl. Dilator muscle fibers.
Mu. lon. Longitudinal muscle.
Mu. obl. Oblique muscle.
Mu. Par. Parenchyma muscle.
Mu. tr. Circular muscle.
Mu. sp. Sphincter muscle.
Ncl. Nucleolus.
Nu. Nucleus.
Nu. M. Nuclear membrane.
Nv. Nerve.
Oc. Eye.
Od. Oviduct.
Oes. Œsophagus.
Oe. Gl. Œsophageal glands.
Ov. Ovary.
P. Gl. Parenchyma gland cell.
P. Vs. Posterior branch of recurrent excretory vessel.
Par. Parenchyma.
Pg. Pigment, in eye.
Ph. Pharynx.
Pr. Ph. Prepharynx.
R. Vs. Recurrent excretory vessel.
S. C. Cuticular sense organ.
Sp. Spermary.
Sp. D. Spermatic duct.
Tb. Tuba fallopii.
Tr. Cm. Transverse nerve commissure.
Ut. Uterus.
V. S. Ventral sucker.
V. Sm. Seminal vesicle.
Vac. Vacuole.
Vt. Vitellaria.
Vs. D. Duct from seminal vesicle to cirrus.
Vt. R. Yolk receptacle.

EXPLANATION OF PLATE I.

All the figures are made from camera lucida drawings, unless otherwise noted.

Fig. 1. View of *Anodonta* opened so as to display the surface of the kidney, and two specimens of *Cotylaspis in situ,* nat. size.

Fig. 2. Young *Cotylaspis* killed with Hermann's fluid with oral sucker distended, × 44.

Fig. 2, *a*. Dorsal view of living *Cotylaspis* very much contracted from life, without camera.

Fig. 2, *b*. View of a living specimen in successive attitudes, × 14.

Fig. 3. Dorsal view, combined from life and from total preparations, × 53.

Fig. 4. Ventral view, × 30.

Fig. 5. Side view, idealized, × 45.

Fig. 6. Sagittal section in plane of cirrus, × 40.

Fig. 7. Transverse section, anterior region, in line *ab* of Fig. 6, × 77.

Fig. 8. Transverse section, posterior region, in line *cd* of Fig. 6, × 77.

Fig. 9. Tangential section just below the surface, near the anterior end, × 293.

Fig. 10. Two muscle fibers from section, iron-hæmatoxylin, × 850.

Fig. 11. Myoblast from methylene-blue preparation, without camera.

Fig. 12. Body-wall and origin of diaphragm at *Cr. S.* of Fig. 6, × 320.

Fig. 13. Unicellular gland-cells of parenchyma, from mouth funnel, × 850.

Fig. 14. Unicellular glands, deeper portion, from vicinity of pharynx, × 567.

Fig. 15. Mouth and prepharynx from horizontal section, × 200.

Fig. 16. Pharynx, œsophagus and intestine in section, showing the relation of cuticle and epithelium, × 440.

Fig. 17. Intestinal epithelium cells in section, iron-hæmatoxylin, × 567.

Fig. 18. Wall of intestine in section passing in the muscle layer, × 270.

Fig. 19. Sagittal section in the plane of the excretory pore, the right side is anterior, × 425.

Fig. 20. Horizontal section in plane of excretory bladder and collecting vessel, × 425.

Fig. 21. Wall of the excretory bladder, showing the degenerating epithelium, iron-hæmatoxylin, × 850.

Fig. 22. Excretory collecting vessel, × 850.

Fig. 23. Principal vessels of the excretory system, the arrows show the direction of the current, without camera.

Fig. 24. View from life to show relation of flame cells and capillaries to the larger vessels of the excretory system.

Fig. 25. View from life of the relation of the collecting and recurrent vessels, and of a capillary crossing them.

Fig. 26. Flagellum from one of the excretory vessels.

Fig. 27. Flame cell and capillary, from living compressed specimen.


1
2
2a
2b
3
4
5
6
7
8
9
10
11
12
13
14
15
16
17
18
19
20
21
22
23
24
25
26
27
Ex Po
Ex Bl
Sp
Vt
Ov
Tb
Ad
Vt R
Dpm
Ves
Cut
Par
Mus
Ph
Int
Ex Bl
Mu Sp
Vac
Mu
Mu tr
Mu lon
Mu Sb
Pal
Pal Sp
Ex Pa
Ex Ve
Tr Cm
L Ve
L Xc
G Ps
G S
Ves Th
Ves Gl
Ves Ph
Ves Ov
Ves Ad
Ves Ex
Ves Ex Bl
Ves Ex Ve
Ves Tr Cm
Ves L Ve
Ves L Xc
Ves G Ps
Ves G S
Ves Dpm
Ves Vt
Ves Vt R
Ves Sp
Ves Int
Ves Par
Ves Mus
Ves Ph
Ves Mu Sp
Ves Mu
Ves Vac
Ves Mu tr
Ves Mu lon
Ves Mu Sb
Ves Pal
Ves Pal Sp
Ves Ex Pa
Ves Ex Po

EXPLANATION OF PLATE II.

Fig. 28. Transverse commissure and related parts in horizontal section, × 160.

Fig. 29. Section of eye from same series as Fig. 6, × 850.

Fig. 30. Cuticle, tangential section, near anterior end, × 850.

Fig. 31. Cuticular sense-organ, in vertical section, × 1600.

Fig. 32. Marginal organ, section passing in its length, × 567.

Figs. 33, 34. Uterus and cirrus sack, in two neighboring sections of horizontal series, × 180.

Fig. 35. Junction of spermatic duct and seminal vesicle, from specimen killed in corrosive under compression and stained with Ehrlich's hæmatoxylin, × 180.

Fig. 36. Walls of spermatic duct and seminal vesicle, with concretion in former, from section, × 850.

Fig. 37. Median section of spermary, sagittal series, picro-nitric, iron-hæmatoxylin, × 320.

Fig. 38. Two parietal cells of spermary, animal killed in May, corrosive sublimate, iron-hæmatoxylin, × 850.

Fig. 39. Central cell from same section as preceding, × 850.

Fig. 40. Parietal cell from same series as Fig. 37, picro-nitric, iron-hæmatoxylin, × 850.

Figs. 41, 42, 43, 44, 45. Central cells from same spermary as Fig. 40, showing various stages of spermatogenesis, × 850.

Fig. 46. Central cells of spermary, spermatogones (?), showing centrosomes (?), corrosive, iron-hæmatoxylin, × 850.

Fig. 47. Karyokinesis in spermatogones, stage between 43 and 44, from same series as 40–45, × 850.

Figs. 48, 49. Two spermatogones from still another series, showing stages of karyokinesis, picro-nitric, iron-hæmatoxylin, × 850. [270.

Fig. 50. Ovary in longitudinal section, cut in plane of "tuba fallopii," ×

Fig. 51. Longitudinal section of part of "tuba," × 850.

Fig. 52. Parietal cell of ovary in July, × 850.

Figs. 53, 54, 55, 56. Cells from different parts of the same ovary showing development of the ovum, picro-nitric, iron-hæmatoxylin, × 850.

Fig. 57. Follicle of the vitellaria, in median section, from same series as Figs. 52–56, × 567.

Figs. 58, 59, 60, 61. Cells from follicle of vitellaria in different stages of maturation, from the same series as the preceding, × 850.

Fig. 62. One of the yolk-cells from the yolk-receptacle, × 850.

Fig. 63. An egg from life, × 220.

Fig. 64. Yolk-cell in egg in uterus, from section, corrosive, iron-hæmatoxylin, × 850.

Fig. 65. Embryo from same egg as 64, showing two nuclei but no division of the cytoplasm, × 850.

Figs. 66–74. Surface views without camera from embryos in eggs, the time of development being as follows: Figs. 66, 67, 68 and 74 are from the same parent, the first at the time of deposit, the rest at eighteen hours, forty hours and six days later respectively. Figs. 69, 70, 72 and 73, from another parent, are forty-eight hours, forty-eight hours, ninety hours and one hundred and fourteen hours old respectively. Fig. 71, from a third parent, is sixty-six hours old.

28
Mu
Tr Cm
Ph
Sal Gl
Int
29
Ph
33
Ut
Cr Sh
Cr S
V Sm
34
Ut
Emb
Cr Sh
Mu
Par
Cr
Vs D.
V.Sm
Int
Con:
V Sm
Sp.D.
35.
36
Sp D
Con
38
Mu
Nu
39
Nu
32
Nu
Mu
Nu
Ep
Con
Cut
Mu
Cut.
Ex Or
30
Cut
37
40
41
42
43
44
45
46.
47.
48.
64
65
Ant
50.
O
Vra
Ep
Ta
51.
Ep
Nu.
51.
Par
Nv
Cut
49
66
67
68
63.
52.
53
54.
55.
56
Ov Ov
69
70.
71
57
59.
60.
61
62.
58
72.
73
74

THE SKULL, AND THE CRANIAL AND FIRST SPINAL MUSCLES AND NERVES IN SCOMBER SCOMBER.*

EDWARD PHELPS ALLIS, JR.

CONTENTS.

INTRODUCTION 46
OSTEOLOGY 48
1. Skull 48
2. Vertebræ 113
3. Visceral Arches 117
1. Gill Filaments 117
2. Basal Line 120
3. Branchial Arches 123
4. Hyoid Arch 137
5. Mandibular and Palatine Arches 151
4. Shoulder Girdle, Sternum, and Pectoral Fin 158
LATERAL LINE SYSTEM 164
1. Main Infraorbital Canal 165
2. Supraorbital Canal 173
3. Preoperculo-mandibular Canal 181
4. Supratemporal Commissure 186
5. Lines of Surface Pit Organs 187
MYOLOGY 188
1. Muscles of the Eyeball 188
2. Muscles innervated by the Nervus Trigeminus and Nervus Facialis 189
3. Muscles innervated by the Nervus Glossopharyngeus and Nervus Vagus 204
4. Muscles innervated by the Occipital and First Spinal Nerves .. 218
5. Muscles of the Pectoral Fin 226
NEUROLOGY 230
1. Brain 230
2. Nervus Olfactorius 232
3. Nervus Opticus 234
4. Nervus Oculomotorius 235

*The manuscript for the present work was sent to the JOURNAL OF MORPHOLOGY, for publication, in July, 1899. Since then several important works relating to the subject have appeared. To make proper reference to them all would entail such important changes in the text, or such frequent use of footnotes, that I conclude best to let the work appear as it was sent to press, without additions or comment of any kind.

5. Nervus Trochlearis..... 237
6. Nervus Abducens..... 237
7. Trigemino-facial Complex..... 238
8. Nervus Acusticus..... 272
9. Nervus Glossopharyngeus..... 274
10. Nervus Vagus..... 279
11. Occipital and First Spinal Nerves..... 290

Introduction.

The present work on *Scomber* was begun in my laboratory, in February, 1892, by Dr. J. Dewitz, and was continued, unfortunately with frequent interruptions, until the spring of 1898. Since then Mr. Jujiro Nomura has been engaged upon it, almost continuously, until the present time, his work being the preparation of the drawings used for illustration and also the preparation of the dissections relating to the brain and to the roots and apparent origins of the nerves. In all of Dr. Dewitz's dissections the brain was so badly preserved that it disintegrated, leaving the roots of the nerves detached. Those drawings that do not relate to the brain are some of them copies of Dr. Dewitz's sketches; others, those relating to the skull, are made from Dr. Dewitz's preparations; while still others are from dissections prepared by Mr. Nomura, guided by Dr. Dewitz's sketches.

Soon after this work was begun by Dr. Dewitz, a similar work was started, by other assistants I had engaged for the purpose, on several other teleosts, my intention being to have the cranial anatomy of some ten or fifteen teleosts and ganoids carefully investigated; my work on *Amia* having convinced me that, in all questions relating to the morphology of the head, an exact knowledge of the anatomy of the adult fish should precede any embryological investigation of it. This purely anatomical knowledge could, I was well aware, be, to a great extent, derived from the study, by sections, of advanced larvæ, a method that is certainly much more enticing and perhaps much quicker. But dissections of the adult must still often be referred to for completeness or for control; and, moreover, those dissections offer the great advantage of the possibility of proper illustration. I had accordingly decided to have the work first done on the adult, and then com-

pleted, in certain details, by reference to sections of larvæ, thus reversing the method I had pursued in my investigations of *Amia*. It, however, soon became evident that I had seriously underestimated the scope and difficulty of the task proposed, and I have been obliged to limit it considerably.

During the course of these several investigations several staining methods were tried, under the direction of Dr. Dewitz, more particularly for the nerves, but they were all finally abandoned for the simple and patient use of the scalpel and dissecting microscope.

The nomenclature employed in the descriptions is, with a few slight changes, the same as that used in my several works on *Amia;* where I adopted, with slight modifications, the terms employed by Sagemehl and van Wijhe, because of the necessary references to those authors' descriptions of the same fish. The occipitale laterale, as there and here used, is, accordingly, the exoccipital of English writers; the extrascapular is the supratemporal; and the exoccipitale, petrosal, squamosal and intercalar are, respectively, the epiotic, prootic, pterotic, and opisthotic. In place of Sagemehl's auto-prefrontal and auto-postfrontal, I have employed the terms preorbital ossification and postorbital ossification, not wishing to introduce definite and special names. The preorbital ossification is, accordingly, the lateral ethmoid, or ectethmoid of English writers, and the postorbital ossification, the sphenotic. That there are regrettable features in the use, in English writings, of the nomenclature thus first adopted by accident rather than intention, and here continued simply for the sake of uniformity in my several works, is only too evident.

The term median is applied only to structures that lie in the mid-vertical plane of the head, or in the middle line or plane of some particular structure. Mesial is used to indicate the opposite to lateral.

The numerous specimens of *Scomber* used during the course of the investigation were obtained partly from the Halles Centrales at Paris, and partly from the Mediterranean coast from Ventimiglia to Marseilles; and I am not sure that two varieties, or perhaps species, of the fish were not used. Certain differences in the shape of the head seemed constant and were perhaps sufficient to indicate a difference in variety.

Osteology.

The complete skeleton of the head of *Scomber* (Fig. 4) is pointed, anteriorly, and is, both in lateral and dorsal views, somewhat triangular in general outline. In dorsal views it is about twice as long as it is wide in its widest part, while, in lateral views, it is less than once and a half as long as it is tall. In its ventral portion it is much compressed, the inferior edges of the mandibular and opercular bones almost meeting in the mid-ventral line. It is accordingly, in transverse sections, somewhat triangular in outline, the point of the triangular being directed downward. The opercular bones are large, and their inferior edge, which is nearly straight, forms nearly one half of the ventral edge of the skeleton. The hind end of the mandible lies somewhat behind the middle point of this ventral edge, and the height of the complete skeleton at this point is nearly three times the height of the skull proper in the same place. The skull proper, as here referred to, naturally includes only those bones and cartilages of the head that are immovably attached together to form, in their posterior portion, the brain case, and, in their anterior portion, the antorbital processes and the rostrum.

The bones of the skull of *Scomber* are all more or less soft and tender, and this renders the deeper dissections of the head of the fish particularly easy. Most of the bones are somewhat porous, and the so-called primary ossifications usually contain, in preserved specimens, much fatty or oily matter, this being particularly noticeable in specimens that have been first treated in chromic acid.

1. *Skull.*

The Skull proper of *Scomber* (Figs. 5–10) is about twice as long as it is broad, and nearly twice as broad, in its broadest part, as it is deep at its hind end. Its hind end is, however, not its deepest part, as the mid-ventral line of the skull is decidedly convex and the deepest part of the curve lies approximately opposite the base of the postorbital process. The skull has, thus, its greatest depth at or near the hind end of the orbit, and, in this plane it is, on its dorsal surface, nearly as broad as it is at its hind end.

The mid-dorsal line of the skull is nearly straight, and the anterior half of its dorsal surface is relatively flat. On this part

of its dorsal surface there is a median, slightly depressed region which extends from near the front end of the skull backward approximately to the plane of the hind end of the orbit. Slightly posterior to the middle of the orbit there is usually a strong, and sometimes almost pit-like depression, the deepest part of which lies immediately in front of the intracranial, epiphysial ridge and directly above a recess of the cranial cavity that lodges the fore brain and the olfactory lobes. Lateral to, or postero-lateral to the depression, on each side, near the lateral edge of the skull, three, deep, longitudinal grooves begin, and, widening as they extend backward, soon occupy nearly the entire dorsal surface of the skull.

These three grooves, on each side of the head, are separated from each other by two tall, thin ridges of bone, and the posterior half or two thirds of the mesial groove, on each side, is separated from the corresponding groove of the opposite side of the head by a similar ridge. This latter ridge, which is median in position, forms an anterior prolongation of, or is the anterior end of, the strong spina occipitalis. The other two ridges, on each side, project upward and laterally, the more lateral one of the two inclining laterally much more than the other. This more lateral one of the two ridges is continued posteriorly by a sharp, flat process of the squamosal, the superficial edge of the process lying, however, at a deeper level than the outer edge of the ridge in front of it, a sharp angle usually separating them. This angle forms the hind end of the ridge proper, and the outer edge of the ridge is here always enlarged, the enlargement marking the place where the preoperculo-mandibular sensory canal joins the main infra-orbital one.

The lateral one of the three grooves thus found on each side of the head, lodges the dilatator operculi muscle. The other two lodge anterior extensions of the trunk muscles. The lateral groove is the dilatator groove of Sagemehl's descriptions of other fishes (No. 65, p. 61), while the next adjoining one has the lateral and mesial boundaries of his temporal groove (No. 65, p. 80) but differs radically from that groove in not being roofed by the dermal bones of the skull. The name temporal groove can, however, be retained for it. The mesial groove, although not specially de-

scribed and named by Sagemehl, is shown, more or less developed, in his figures, and may be called the supratemporal groove.

The general outer level of the dorsal surface of the posterior part of the skull is given in the outer edges of the five ridges that separate the six dorsal grooves one from another, and is decidedly convex, the dorsal surface of the skull, on each side, sloping laterally, backward and downward to its postero-lateral corner.

The Dilatator Groove (*dgr*) is shorter than the other two, looks upward and decidedly laterally, and lies on the external surfaces of the frontal and squamosal bones and the postorbital ossification. Posteriorly it opens onto the lateral, and not onto the posterior surface of the skull, the opening extending from the dorso-lateral corner of the postorbital process backward to the enlarged hind end of the ridge that separates the groove from the temporal groove. The posterior half of this opening lies directly dorsal to the two facets that receive the two dorsal articular heads of the hyomandibular, the anterior facet often cutting slightly into the dorso-lateral edge of the skull and hence into the edge of the opening. Directly above the anterior edge of this anterior facet, and slightly in front of the middle of the opening of the groove, there is a small process, more or less marked in different specimens. From this process a slight ridge runs forward and mesially along the floor of the groove, the process and ridge separating the opening and groove into two somewhat different regions. The mesial and posterior of these two regions lies at a slightly deeper level than the other one, the difference in level being most marked toward the hind end of the groove. The process and ridge mark the line of origin of a longitudinal tendon of the dilatator operculi muscle.

The Temporal Groove (*tgr*) is the middle one of the three, and is deeper than either of the other two. It opens, at its hind end, onto the posterior surface of the skull, the opening occupying the entire space between the dorso-posterior corner of the exoccipitale and the postero-dorso-lateral corner of the skull. The bottom of the groove, at about the middle of its length, changes abruptly in level, the posterior portion lying considerably deeper than the anterior one. At the antero-mesial corner of the pos-

terior portion there is a marked depression, directed forward downward and mesially. Opposite this depression, in the antero-lateral corner of the posterior portion of the groove, there is usually a small, flat and relatively wide recess, which leads forward and laterally onto the dorsal surface of the postorbital ossification, between that bone and the overlying anterior end of the squamosal. Nothing indicating the significance of this recess could be found.

The ledge that separates the two portions or levels of the temporal groove is formed partly of bone and partly of cartilage, the cartilaginous portion being a small, four-cornered surface of cartilage which may be called the temporal interspace. The remainder of the bottom of the groove, and also its bounding side walls, are formed by parts of the frontal, parietal, squamosal and exoccipitale bones, and by a small, posterior portion of the postorbital ossification. From the cartilaginous interspace a narrow line of cartilage runs laterally between the adjoining edges of the squamosal bone and the postorbital ossification, and another backward between the squamosal and exoccipitale. A third line, usually entirely covered by the parietal, runs mesially and backward between the exoccipitale and supraoccipital, the interspace itself being continued forward, internal to the parietal, between the supraoccipital and the postorbital ossification.

The Supratemporal Groove (*sptgr*) is shallower than either of the other two. It opens, at its hind end, onto the posterior surface of the skull, the opening lying between the dorso-posterior process of the exoccipitale and the spina occipitalis. Ventral to, and coextensive with its hind edge there is, on the mesial part of the posterior surface of the skull, a grooved or depressed portion. The lateral edge of the supratemporal groove, in its anterior portion, curves slightly laterally and forward, the corresponding part of its mesial edge curving much more strongly in the same direction. The groove itself thus curves laterally, at its anterior end, its anterior extremity lying on a level with, and close to, the anterior ends of the two other grooves.

In certain of the teleosts described by Sagemehl (Nos. 65 and 66), the supratemporal groove is indicated in all, or in a part, of a depressed region lying posterior to a line called by him the linea nuchæ, which line is said by him to indicate the position of

the anterior edge of the trunk muscles. In *Alestes* the posterior limits of this depressed region correspond exactly to those of the groove in *Scomber,* but in most of the fishes described the depression includes the entire dorsal surface to the exoccipitale, its posterior limits thus corresponding, approximately, to those of the temporal and supratemporal grooves united of *Scomber.* The temporal groove of this latter fish may, thus, be simply a part of the superficial depression shown by Sagemehl in the fishes described by him, and not at all the homologue of his temporal groove, which groove is covered dorsally by parts of the adjoining bones of the skull. This marked disagreement in the relations of the temporal groove of *Scomber* to the bones that bound it has already been referred to in an earlier work (No. 6,), and it was there stated that it seemed to indicate that *Scomber* and *Amia* represented two different lines of descent from some fish in which the trunk muscles had not, as yet, invaded the temporal regions of the skull. That the dorsal, bony covering of the groove has simply disappeared in *Scomber,* thus leaving the muscles exposed, seems improbable, for parts of the bones that are covered by the muscles, in *Scomber,* are traversed by the lateral sensory canals.

The Lateral Surface of the brain case is, in its general outer level, inclined at about 45° to the mid-vertical plane of the head. The entire posterior portion of this surface is, however, occupied by a deep depression, the center of which lies on a level with the dorsal surface of the vertebral column and slightly in front of the front end of that column. This depression gives to the hind end of the skull a pinched appearance, and to the dorsal part of its lateral surface, at its hind end, an inclination of something like 70° to the vertical plane. The depressed region is, apparently, in no way comparable to the subtemporal hole of cyprinoids (No. 66, p. 554), and apparently owes its existence simply to the entire absence of a bulla acustica. The saccular recess of the cranial cavity lies internal to the deepest part of the depression.

The Posterior Surface of the skull is relatively small, because of the four large dorsal grooves that cut into its dorsal portion, and it presents no special characteristics. Its mesial third, on each side, forms a slightly depressed region which is continuous, at its upper end, with the hind end of the supratemporal groove.

The Orbits are large, occupying sometimes one half the length of the skull. They are separated from each other, throughout nearly their whole extent, by membrane only, there being no interorbital ossification whatever, excepting only the small basisphenoid, and the interorbital cartilage being reduced to small remnants at the base of the basisphenoid and at the anterior ends of the mid-dorsal and mid-ventral lines of the orbit. These greatly enlarged orbits cut into the skull to such an extent that an anterior surface is formed to the brain case. This surface, on each side, is presented forward, downward and but slightly outward, is relatively flat, and forms the hind wall of the orbit of its side. Its lateral edge is formed by the antero-lateral edge of the postorbital process and by the anterior edge of the wing of the parasphenoid, and it is deeply notched at about the middle of its length, the nervi trigeminus and profundus, and the associated branches of the lateral sensory nerves, there entering the orbit.

The Chondrocranium has either disappeared or been almost entirely ossified, excepting in the antorbital region. In the postorbital region nothing remains of it but several relatively unimportant nodules and interspaces of cartilage, and the several narrow lines extending from them between the adjoining edges of the neighboring bones. The cartilage seems, in certain parts of these separating lines, to be replaced by a dense connective tissue, and, in others, to have entirely disappeared, the bones in the latter places being apparently directly connected by suture. These sutural connections are usually formed by splint-like processes which project from one bone and overlap and fit into corresponding depressions on the outer surface of the other. The processes may, however, arise from both bones, in which case they interlock. Similar sutural connections may also be found even where the bones, in their deeper parts, are still wholly separated by cartilage, the splint-like sutural processes, in such cases, arising only from the denser, superficial layers of the bones concerned. As these sutural processes are usually thin and semi-transparent, the lines of cartilage or tissue separating the deeper parts of the bones can, in most places, still be seen through them.

In seeking to determine what parts of these separating lines were formed of cartilage, stainings with reagents proved most unsatis-

factory, the dense connective tissue that separated certain of the bones, staining with almost the same colour and intensity as the cartilage itself. Skulls slightly boiled, and examined while fresh, were then tried with better results, but the most satisfactory results were obtained by a process of natural staining which consisted in simply leaving to macerate, for a short time, a fresh head that had been slightly boiled. The cartilaginous parts of the skull, so treated, soon turned a dark rich brown, the other tissues remaining unchanged.

The postorbital remnants of the chondrocranium are in part exposed, either on the outside or the inside of the skull, and in part entirely enclosed between the edges of the adjoining bones. The exposed interspaces are six in number: a dorso-median one lying immediately posterior to the epiphysial ridge; a ventro-median one at the base of the shank of the basisphenoid; a dorso-lateral one, on each side, lying in the floor of the temporal groove and already referred to; and a ventral one, on each side, lying along the ventral edge of the petrosal. The larger part of each dorso-lateral, or temporal interspace is seen on the external surface of the skull, as is also a narrow, median line of the post-epiphysial one. The two ventral interspaces are only visible on the internal surface of the skull, or after the parasphenoid has been removed. They will all be described in describing the bones related to them. No one of them is, in any place, continuous with the antorbital cartilage. The post-epiphysial cartilage and the small bit at the base of the shank of the basisphenoid are, however, connected with the antorbital cartilage by the thick, membranous, interorbital septum, which should, undoubtedly, be considered as a part of the primordial cranium that has not chondrified.

The persisting cartilage of the anterior part of the chondrocranium is a continuous median piece with dorso-lateral, ventro-lateral, and anterior extensions, these extensions forming parts of the roof and floor of the antorbital processes, and the ventral, median, and anterior portions of the rostrum. The cartilage separates the three primary ossifications of the antorbital region one from the other, and caps their several articular processes. Its ventral surface is flat, forms the base of the anterior part of the chondrocranium, and is grooved, in the middle

line, for nearly its entire length, the groove being widest and deepest between those processes of the preorbital ossifications that give articulation to the palato-quadrate. The ventral edges of these latter articular processes are capped with thick bands of cartilage, which extend outward, on each side, from the ventral portion of the chondrocranium. Anteriorly the mid-ventral groove becomes shallower, and finally disappears entirely not far from the extreme anterior end of the chondrocranium. In front of the anterior extremity of the groove there is a short and narrow ungrooved surface, and then the chondrocranium ends in a hooked or beak-like portion.

The median longitudinal groove on the ventral surface of the chondrocranium of the adult *Salmo* is said by Parker to represent the obtuse angle and space which, in earlier stages, lay between the then unfused trabeculæ (No. 50, p. 107). The trabeculæ are said by him to arise, in *Salmo,* independently of each other and of the "investing mass"; to fuse, later, with each other, and with the anterior end of the investing mass; and then, still later, to become again separated from the latter mass. All of these statements are confirmed by Stöhr (No. 71, p. 97), but they are not in accord with my interpretation of Vrolik's statement (No. 76, pp. 252, 254) that the "Schädelfalten" are outgrowths of the "Schädelbalken." In the adult *Salmo* the free hind end of each of the trabeculæ is said by Parker to present, on its ventral surface, a facet, which is called by him the "anterior pterygoid process," or posterior "facial connective growth." This facet or process is said by him to be the basipterygoid of Huxley. The trabeculæ themselves are said by Parker to be the first facial arches of the animal (No. 50, p. 114), a conclusion supported by Platt's recent work on *Necturus* (No. 56).

The median groove on the ventral surface of the antorbital cartilage of *Scomber* lodges, throughout its entire length, a median, longitudinal process, or rib, which rises vertically from the dorsal surface of the parasphenoid, the latter bone itself fitting into a larger, but slight depression only, in the same cartilage. Slightly in front of the anterior end of this latter depression the chondrocranium ends in the hooked or beak-like portion already mentioned. The base of the beak is slightly wider than the cartilage

from which it arises, its lateral edges being extended to form small processes which project laterally, downward and forward. They are rounded on their superior surfaces, but flat on their inferior, postero-ventral surfaces, where they rest, on each side, upon the dorsal edge and dorsal surface of the anterior portion of the vomer. The median part of the beak is compressed laterally, and has a rounded, median, anterior edge. Its ventral end lies between the dorsal ends of the lateral articular processes of the vomer, fitting into a deep median indentation in the anterior edge of that bone. The postero-dorsal edge of the beak abuts against the antero-ventral edge of the ethmoid, the anterior end of the latter bone being slightly differentiated as an antero-median process. The superior surfaces, both of the beak and of its lateral processes, are seen in dorsal views of the skull. In ventral views the anterior end of the beak alone is seen, the lateral processes, and often the beak also, being hidden from view by the enlarged anterior end of the vomer. The beak gives articulation to the internal surface of the rostrale. The lateral processes do not give direct articulation to any bony or cartilaginous structures. Slightly posterior to them there is, on each side, a lateral process of the basis cranii which caps the ventral surface of a ventro-lateral process of the ethmoid, and gives articulation to the palatine.

In certain of the Characinidæ, Sagemehl's figures seem to indicate that the beak of *Scomber,* or that structure and its lateral processes also, are ossified as parts of a greatly developed ethmoid. The articulations in the Characinidæ are, however, not exactly similar to those in *Scomber,* and the ethmoid of the former fishes is said by Sagemehl to be, in part, a dermal bone. The lateral processes, in particular, are greatly developed in certain Characinidæ, and they may represent the lateral processes of the beak of *Scomber* fused with the ventro-lateral processes of the ethmoid.

At the dorso-posterior and ventro-posterior edges of the antorbital cartilage of *Scomber* there are short, median, cartilaginous processes projecting backward. The ventral surface of the dorsal process and the dorsal surface of the ventral one are both raised in slight, median ridges. These ridges are usually connected, along the median line of the posterior surface of the antorbital cartilage, by a similar, more or less pronounced ridge in the cartil-

age. The two processes, and the connecting ridge, represent, with the basisphenoid, all there is, in *Scomber,* of the cartilaginous or bony interorbital septum usually found in fishes. The dorsal process is flat, broad and blunt. The ventral process is narrower and thicker than the dorsal one, and is pointed posteriorly. Laterally to the dorsal process, between it and the postero-dorso-lateral corners of the cartilage, there is, on each side, a wide and deep indentation, the preorbital incisure (*ip*). Through it the ophthalmic nerves leave the orbit and reach the dorsal surface of the chondrocranium. Running forward and slightly laterally from the incisure, across the dorsal surface of the cartilage, there is a small sharp groove, which, near the anterior edge of the antorbital process, becomes a nearly closed canal, and then leaves the cartilage in a more or less pronounced notch, which is the ethmoid incisure (*ic*). The groove and canal lodge, as in *Amia,* the united ramus ophthalmicus superficialis trigemini and ramus ophthalmicus superficialis facialis. That part of the antorbital cartilage that, on each side of the head, lies lateral to the groove, is called by Parker, in *Salmo* (No. 50, p. 108), the ectoethmoidal wing, or antorbital expansion of the mesoethmoid. The part that lies between the two canals is called by him the mesoethmoidal region and is considered as part of the culmen cranii.

The Ethmoid (*ETH*) of *Scomber* is one of the three primary ossifications of the antorbital part of the chondrocranium. It is, in the adult, a median bone, but gives some slight indications of having been formed either by the fusion of two lateral components, or by the fusion of two lateral components with a single, median piece. It is to all appearance entirely of primary origin, no indication whatever being found in it of a fusion of dermal and cartilaginous components. It is not traversed, in any part, by any portion of the lateral sensory canals, and there are not even, so fas as could be determined, any surface lines of pit organs in any relation whatever to it. Its dorsal and lateral surfaces are exposed in the prepared skull, and their edges lie, in every part, on a level with the outer surfaces of the adjoining cartilage of the chondrocranium. Its ventral surface is not exposed, lying inside the cartilage, and being everywhere separated from the base of the chondrocranium by a relatively thick layer of cartilage. In

vertical longitudinal sections, the ventral edge of the bone is seen as an arc of a circle, as if the ossification of the cartilage had begun on the outer, dorsal surface of the chondrocranium, and from there extended inward. In transverse sections the ventral edge of the bone is everywhere nearly straight, as is also, in horizontal longitudinal sections, its posterior edge.

The dorsal surface of the ethmoid is somewhat rectangular in general outline, its posterior edge being straight, its anterior edge and end somewhat rounded and irregular, and its lateral edges concave. The lateral portions of its posterior half or two thirds are covered, on each side, by the anterior end of the corresponding frontal, a median tapering surface of the ethmoid being left exposed between the two frontals. The ethmoid, in this part, slightly overhangs, on either side, the nasal pit, and the frontals slightly overhang the ethmoid. Immediately under and in front of the front end of each frontal there is, in the ethmoid, a strong process projecting laterally, or laterally and slightly forward. It is relatively thin, its dorsal surface lies on a level with the dorsal surface of the ethmoid, and it gives support, on its posterior edge, to the front end of the frontal. On its outer end it supports the nasal, lying immediately ventral to the mesial edge of that bone, slightly in front of the middle of its length. It is not capped with cartilage, is not an articular process, and may be called the dorso-lateral process of the bone. From its anterior edge there arises a ligament, which runs downward and forward and is inserted on a process on the outer surface of the maxillary near the ventral edge of the anterior end of that bone. Directly ventral to this dorso-lateral process, at the ventral edge of the ethmoid, there is a second lateral process. It is directed laterally, downward, and forward, is much stronger than the dorsal process, and is capped with cartilage, the cartilage of the cap being always, in small fishes, and often in large ones, continuous, along the ventral surface of the process, with the cartilage of the base of the chondrocranium. This second process is thus a process of the chondrocranium, strengthened by the ethmoid bone which grows downward upon and around it. It gives articulation to the palatine bone, near its anterior end, and so fulfils, in this respect, the function of that process of cyprinoids that is described by

Sagemehl as a lateral process of the vomer and said by him to be partly ossified, in certain species, as the septomaxillary (No. 66, p. 510).

Posterior to its lateral processes, between them and the hind end of the bone, the ethmoid is constricted laterally, the constriction being most pronounced slightly below the dorsal surface of the bone. This part of the bone forms the anterior part of the mesial wall of the nasal pit, and a part of the floor of that pit. It is separated, posteriorly, from the preorbital ossification, by a narrow line of cartilage, but this cartilage may be bridged, near the middle of its length, by an exceedingly thin but wide splint-like process of the ethmoid. Ventrally the ethmoid may touch, or be slightly overlapped by, the dorso-lateral edge of the vomer. In front of its lateral process the bone is somewhat rounded, and has a median ridge-like portion which is continuous, anteriorly, with the beak of the chondrocranium, its dorsal surface running forward and downward in a slightly curved line. Directly on top of this portion of the bone, and immediately postero-dorsal to the rostrale, there is, in the recent state, a tough pad of tissue, which is strongly but loosely attached to the top and sides of the ethmoid and hence capable of considerable movement.

In the interior of the ethmoid there is always a median space, of variable size and shape, filled with a semi-liquid, fatty or oily substance. In one specimen this space was almond-shaped in both horizontal and vertical sections, its hind end coming to the hind edge of the bone, and its front end reaching to about the anterior third or quarter of the bone. In another specimen it was oval and small in vertical section, instead of being almond-shaped and large, and lay at about the dorsal third of the bone. In a third specimen it was round, or sub-cubical, occupied the whole posterior third of the bone, excepting only thin dorsal and lateral plates, and, ventral to the inferior surface of the bone, extended slightly into the underlying cartilage. It is the mesoethmoidal fat-cavity described by Parker (No. 50, p. 108) in *Salmo,* and considered by him, in that fish, as a "remnant of the azygous nasal sac of the Myxinoid."

The ethmoid of *Scomber* is thus seen to be in no part or way the homologue of the so-called ethmoid of *Amia.* This has

already been stated by me in one of my earlier works (No. 7), in which the so-called ethmoids of certain other fishes were compared with that of *Amia*. In that work I stated my opinion that the two bones in *Esox* called by Huxley " Bones 2 " were probably the homologues of the ethmoids of *Amia* and *Salmo*. Since then I find that Gegenbaur (No. 29, p. 9) has described a bone in *Alepocephalus* as the ethmoidale median, and said of it that it is an "unpaares Knochenstück—bei Esox paarig—." The bones of *Esox* here referred to must be bones 2 of Huxley, which bones were thus considered by Gegenbaur as ethmoids. The median ethmoid of *Alepocephalus* is said to overlap externally (lateral umgreifen) the frontals of that fish, and to be the homologue of the bone called by Parker in *Salmo* the supraethmoid. It has a ventro-lateral process resembling strongly the corresponding process in *Scomber,* the process giving articulation either to the palatine, alone, or to both that bone and the maxillary. The bone is said to be one of the "secondären Knochen" (No. 29, p. 29), as is also the palatine, but both of these bones are said to differ from the other secondary bones of the fish in not being separated from the underlying cartilage by perichondrium. Whether this ethmoid bone of *Alepocephalus* is the homologue of the similarly named bone in *Amia,* or of that of *Scomber,* it is impossible to determine from the descriptions.

In *Gadus æglefinus* (No. 12), the ethmoid is said by Brooks to be overlapped externally by the frontals, and in this as well as in its relations to the skull it agrees closely with the ethmoid of *Scomber.* The ossification has, however, extended forward and downward, and includes the cartilaginous beak of *Scomber.* It gives attachment, on each side, as in *Scomber,* to a strong ligament that has its insertion on the maxillary; and it gives articulation, on its anterior edge, to a rostrale, called by Brooks the pre-ethmoid cartilage.

The Rostrale (*R*) of *Scomber* is a small, flat, detached piece of cartilage, connected by fibrous tissue with the anterior end of the skull. It is roughly square, or slightly hexagonal, in general outline, with a prominent process or shank at the middle of its lower edge. At the middle of its upper edge there is a sharp indentation, from which shallow grooves extend downward, a short distance, on both the outer and the inner surfaces of the piece.

The inner surface of the piece is usually slightly concave, and faces backward and slightly downward. The outer surface is slightly convex, faces forward and upward, and has, along its median line, a slight ridge. The inner surface, on each side, rests against, and is firmly bound by fibrous tissues to, the outer surface of the anterior end of the maxillary, that bone extending from the upper to the lower edge of the body of the piece. The outer surface of the piece, on either side, rests against, and is firmly bound by tissue to, the inner surface of the ascending process of the premaxillary, the ventral part of the anterior edge of the latter bone resting against the ventral, median shank of the rostrale. The median ridge on the outer surface of the rostrale, which extends also onto the shank of the piece, lies between the adjoining, antero-mesial edges of the premaxillary bones, but it does not come to the level of their outer surfaces, lying everywhere internal to their outer edges, and being covered by the fibrous or ligamentous tissues that bind the two premaxillaries together. The median groove on the inner surface of the rostrale rests upon, and articulates with, the median, anterior, ante-ethmoidal process or beak of the chondrocranium and skull.

The Maxillary (*MX*) is a long, flat, doubly-curved bone, the hollow of one curve directed inward, that of the other downward and forward. The anterior end of the bone is enlarged and thickened, and has its anterior border bevelled to a narrow edge. Dorsal to this bevelled edge, on the dorsal edge of the bone, there is a strong articular head directed upward and mesially; and ventral to the bevelled edge there is, on the outer surface of the bone, a small, flat, oval, articular surface directed forward and laterally. The middle and most anterior portion of the bevelled edge projects slightly, and there is, on each side of it, a small articular surface. Immediately dorso-posterior to the ventral articular surface there is, on the ventral portion of the outer surface of the bone, a small but strong process directed laterally and forward, and having on its anterior surface a small, well-formed, articular eminence. Immediately postero-dorsal to this process there is still another articular surface which occupies a shallow depression in the outer surface of the bone. Each of these several articular surfaces is covered with a thin layer of tissue that adheres

closely to the bone, stains like cartilage in carmine preparations, and is so brittle that it chips off in little pieces when being removed. Otherwise it seems to be of a fibrous, or semi-cartilaginous, rather than a cartilaginous character, and in cleaning macerated specimens it is always removed with the other tissues.

The dorsal articular head of the maxillary articulates, indirectly, with a large articular head on the lateral edge of the anterior end of the vomer, the two elements being separated by a tough fibrous, or fibro-cartilaginous pad which is attached to a strong ligament that extends from the skull to the outer surface of the maxillary. This ligament arises from the anterior edge of the dorso-lateral process of the ethmoid, or from the lateral surface of the median ridge on the anterior end of the ethmoid in front of that process, and has its insertion on the little process near the ventral edge of the outer surface of the maxillary, as shown in Fig. 54. The fibrous pad, connected with this ligament, that extends downward between the maxillary and vomer, and other similar, but less developed pads of tissue that lie between the maxillary and premaxillary, and between the maxillary and palatine, seem to represent, in *Scomber,* the submaxillary cartilages described by Sagemehl (No. 65, p. 102) in certain other teleosts.

Between the ventral articular surface on the outer surface of the maxillary and the process that lies immediately dorso-posterior to it and projects downward and forward over it, there is a narrow but relatively deep space into which a part of the dorsal edge of the premaxillary fits. This part of the latter bone is lined, on both its inner and outer surfaces, with the same tissue that lines the articular surfaces of the maxillary, and its two surfaces articulate, respectively, with the ventral articular surface of the maxillary, and with the articular eminence on the anterior surface of the little process of that bone. The articular surface immediately posterior to the little process gives articulation to the anterior end of the palatine.

The articular edge at the anterior end of the maxillary rests against a small articular surface on the inner surface of the premaxillary.

Between the dorsal articular head of the maxillary and the dorsal edge of the body of the bone posterior to it, there is a relatively

deep angle, with a rounded bottom, which fits against the ventral and anterior surfaces of the ventro-lateral process of the ethmoid, and may perhaps be said to there articulate with it.

No Jugal bone, the supramaxillary bone of Sagemehl, is found in *Scomber*.

The Premaxillary (*PMX*) is a curved bone of nearly the same length as the maxillary. Its anterior end is flat, and irregularly triangular in shape, the point of the triangle directed upward, or upward and backward, and forming the ascending process of the bone. Posterior to this triangular head of the bone, the premaxillary is slender, tapering gradually to a blunt and slightly enlarged hind end. The ventral edge of the bone is furnished, throughout its entire length, with small sharp teeth. In the angle between the posterior edge of the ascending process and the dorsal edge of the shank of the bone, there is a small projecting edge of bone, which presents articular surfaces both internally and externally. The external surface is slightly concave, the internal one slightly convex, and they fit in between, and articulate with the two articular surfaces on the outer surface of the maxillary, as already described. Immediately dorso-anterior to the articular edge there is a sharp edge, or even a sharp process of bone, which gives partial attachment to a band of fibrous tissue, somewhat ligamentous in character, which connects the bone, and also the maxillary, with the inner surface of the nasal near its anterior end. On the internal surface of the premaxillary, near its anterior edge, there is a small articular surface, covered with fibrous or fibro-cartilaginous tissue, which gives articulation to the anterior articular edge of the maxillary. The anterior edge of the bone is slightly roughened and forms the surface of insertion for the tough fibrous tissues that bind the bone to its fellow of the opposite side of the head.

The maxillary, premaxillary and rostrale are strongly bound together by fibrous or ligamentous tissues, and the premaxillary is bound by similar tissue to the corresponding bone of the opposite side of the head. The five elements thus form a single piece, between the separate parts of which but little movement is possible. The piece forms the upper jaw of the fish, and is capable of a certain amount of movement upon the anterior end of the cranium.

To that end of the cranium it is attached, not only by general fibrous tissues, but also, on each side of the head, by the ethmoido-maxillary ligament and the fibrous or semi-ligamentous nasalo-maxillary band. The ligament arises, as already stated, from the dorso-lateral process of the ethmoid, or from the median ridge of the ethmoid in front of the process. The semi-ligamentous band arises from or near the anterior end of the nasal bone. Both ligament and band are inserted, in whole or in part, on the outer surface of the maxillary, on or near the lateral process found near the ventral edge of the anterior end of that bone, and thus one or both of these structures seem to represent, in *Scomber,* the fourth division of the levator maxillæ superioris muscle of *Amia.* The band has often much the character of tough subdermal tissue.

When the mouth is closed the shanks of the maxillary and premaxillary pass upward internal to the lachrymal and are entirely hidden from view by that bone, the lower edge of the lachrymal thus forming, in the recent state, the apparent edge of the upper lip. The maxillary lies dorsal to the premaxillary, its ventral edge slightly overlapping laterally the dorsal edge of the latter bone. It is entirely without teeth, and a slight fold in the dermal tissues of the lip extends upward between it and the premaxillary. Another, but much more important fold extends upward between the outer surfaces of the maxillary and premaxillary and the inner surface of the lachrymal, this fold extending from the hind end of the mandible nearly to the anterior end of the snout. The hind ends of the maxillary and premaxillary are both slightly enlarged and flattened, and are bound together by dermal tissue. In the recent state, when the mouth is closed, they lie in a depression on the outer surface of the lower jaw, near the hind end of its dorsal edge. They are strongly but loosely connected with the mandible by dermal tissue, by which they are pulled downward and forward when the mouth is opened. The same tissues tend to pull them back in place when the mouth is closed, but, in addition to this indirect action, the adductor mandibulæ muscle acts directly upon the two bones by a long tendon that arises from the lower, anterior end of the muscle and is inserted on the external surface of the maxillary, at its ventral edge and not far from its anterior end.

In *Gadus æglefinus* (No. 12) the maxillary and premaxillary much resemble the corresponding bones in *Scomber*. They both articulate with and are bound to a median rostrale, and this latter element is movable upon the anterior end of the ethmoid. The maxillary of *Gadus*, however, is said to articulate directly and independently with the skull in a cartilaginous groove between the ethmoid and vomer, and the bone is, accordingly, much less intimately connected with the premaxillary than in *Scomber*. There is also a strong ligament, not found in *Scomber*, which arises from the apex of the ascending process of the premaxillary, on each side of the head, and, crossing the median line dorsal to the ethmoid, is inserted on the palatine bone of the opposite side. What seem to be the representatives of the little articular surfaces that I have described on the two bones in *Scomber* are, several of them, said to be simply the points of attachment of certain connecting ligaments. Otherwise there is a strong resemblance in the arrangement of the parts concerned in the two fishes.

The ascending process of the premaxillary I consider, as fully set forth in one of my earlier works (No. 7), as the probable homologue of one half of the ethmoid bone of *Amia* fused with the premaxillary of that fish. To the several references there made to other fishes, in support of this conclusion, *Alepocephalus* may here be added; for in that fish the ethmoid is said by Gegenbaur (No. 29) to be of dermal origin and to overlap externally the frontal, and the premaxillary is said to have no ascending process.

No Septomaxillary, as a separate bone, is found in *Scomber*. There is, however, as already stated, a process of the chondrocranium which fulfills the function of the septomaxillary process described by Sagemehl in cyprinoids. This process, in the cyprinoids, is said to articulate directly with the palatine, and indirectly, by means of a "Zwischenknorpel," with the maxillary. In *Scomber* it articulates with the palatine alone; but the hind edge of the dorsal articular head of the maxillary hooks around the ventrolateral process of the ethmoid, and hence to a certain extent articulates with it. The process, in *Scomber*, also presents practically the same relations to the palatine and maxillary that the sextomaxillary region of the skull of *Amia* does to those same bones. That part of the ethmoid of *Scomber* that occupies the base of this

process may, therefore, represent the separate septomaxillary of *Amia,* and certain lines in the bone, in *Scomber,* seem to indicate, slightly, that there was here a separate center of ossification. The ossification in *Scomber,* however, does not begin, externally, on the ventro-lateral edge of the skull and ossify inward, as the bone in *Amia* does, which may indicate that while there is homology in the region there is none in the bones (No. 7). It may be noted that Sagemehl considers the articulation of the septomaxillary with the maxillary as the primary arrangement in fishes, the articulation with the palatine being a secondary one.

The Preorbital Ossification (*PRE*) is an irregular bone having somewhat the appearance of an X applied to the outer surface of a part of a sphere. The arms of the X are raised considerably above the body of the bone, and their outer surface is marked with sculptured lines, which run from the end of the dorso-posterior arm downward and forward to the end of the ventro-anterior one, and from each of the four arms into the two adjacent ones. The two dorsal arms are somewhat fused with each other; the two ventral ones are distinctly separate. The ventro-posterior arm projects laterally as a strong, flat process, and its ventral edge, which forms the arc of a circle and is capped with cartilage, forms the posterior of the two articular surfaces by which the palato-quadrate articulates with the cranium. In *Salmo* the homologue of this process is said by Parker to form the anterior articulation of the palato-quadrate with the cranium, and it is called by him the anterior facial connective growth. The still more anterior, ethmoidal, or septomaxillary articulation, of *Scomber,* is, according to Parker's descriptions, replaced in *Salmo* by an articulation with the maxillary (No. 50, p. 109), but this does not seem to agree with his Fig. 2, Plate VI.

The ventro-anterior arm of the X of the preorbital ossification is connected by suture with a lateral process of the vomer that arises from that bone near its anterior end. The dorso-posterior arm extends backward under the frontal, and there forms part of the roof of the orbit. The posterior portion of this part of the bone is flat, thin, and relatively broad, and lies directly against the under surface of the frontal without the intervention of a layer of cartilage. The rest of the dorsal surface of the bone, except-

ing only a narrow lateral edge, is covered by a thin layer of the cartilage of the antorbital process of the chondrocranium.

From near the mesial end of the thin, dorso-posterior edge of the preorbital ossification a strong rib, or brace, runs downward and slightly inward to the ventral edge of the bone. It is flat, projects directly backward, or backward and inward, into the orbit, and may be called the orbital rib of the bone. It divides the posterior, or orbital face of the bone into two distinct regions, an external and an internal one. From the base of the lateral surface of the rib, and at about the middle of its length, a strong ligament arises, and, running downward, is inserted on the external surface of the palato-quadrate immediately posterior to the surface by which that arch here articulates with the skull. It holds the arch up against the ventral, articular edge of the postero-lateral process of the preorbital ossification, and allows a swinging, latero-mesial movement along that edge. The space internal to the orbital rib of the bone forms the extreme anterior end of the orbit, and has a concave surface. In it, slightly dorso-mesial to its middle point, is the posterior opening of the canal by which the olfactory nerve traverses the antorbital process, the canal lying entirely in the preorbital ossification. A short, straight ridge runs downward and inward tangential to the ventro-lateral edge of the opening; and ventro-lateral to this ridge, between it and the orbital rib, there is a deep recess. The anterior opening of the olfactory canal lies immediately internal to the angle formed between the dorso-anterior and ventro-anterior arms of the X of the preorbital ossification. That part of the bone that lies between these two arms forms the posterior part of the floor and the corresponding part of the mesial wall of the nasal pit.

The preorbital ossification is separated, anteriorly, from the ethmoid bone by a narrow line of cartilage; and the mesial edge of its orbital surface is separated by a similar line from the preorbital ossification of the opposite side of the head. The outline of the bone, where it adjoins the cartilage, is circular, the center of the circle being approximately the centre of the four arms of the X of the bone. The ventro-lateral edge of the bone may be slightly overlapped by the lateral edge of the parasphenoid.

The Vomer (*VO*) has a short, stout, anterior portion, or head, and a long, thin posterior portion, or body, which ends in a long and slender point. On each of its lateral edges, immediately posterior to the head of the bone, there is a flat, thin, lateral process, projecting laterally, upward and backward. The process occupies about one third the length of the edge of the body of the bone, and its dorso-posterior end, which is frayed, connects by suture with the lower end of the ventro-anterior arm of the X of the preorbital ossification. The dorso-anterior edge of the process lies immediately below, or slightly overlaps, the ventral edge of the ethmoid, its anterior end lying immediately below the cartilage that caps the ventro-lateral process of the same bone.

The head of the vomer is formed by two stout, condylar processes directed downward, forward and laterally, and having on their outer ends large and somewhat kidney-shaped articular surfaces, which are presented laterally, forward and slightly upward rather than downward. They articulate indirectly, on each side, with the corresponding maxillary bone, being separated from that bone by a dense biconcave pad of fibrous tissue. The articular surface of the vomer thus lies ventro-mesial, or ventro-postero-mesial to the articular end of the maxillary, instead of ventral and ventro-anterior to it, as in *Amia,* and the bone has no articular relation whatever with the palatine, that bone articulating with the ventro-lateral process of the ethmoid, and with the external surface of the maxillary.

Between the convex, mesial edges of the articular surfaces of the vomer, the ventral and ventro-anterior surfaces of the bone are concave. Along each lateral edge of the ventral part of this surface, parallel to and but slightly mesial to the hind ends of the infero-mesial, curved edges of the articular surfaces, there is a short row of small, sharp teeth, usually three or four in number.

The dorsal edge of the anterior end of the vomer is sharply notched in the middle line, between the anterior-superior ends of the articular heads of the bone, the notch receiving the median process of the beak of the chondrocranium. The lateral processes of the beak fit into V-shaped depressions on the dorsal surface of the vomer immediately posterior and lateral to this notch. With this part of the chondrocranium the vomer is intimately con-

nected, and is not easily removed without injury to the cartilage. There seems, however, to be no primary connection whatever of the bone with the cartilage such as Sagemehl found in the Characinidæ and Cyprinidæ.

The slender, pointed body of the vomer fits into a corresponding median depression on the ventral surface of the parasphenoid, the latter bone extending forward between the thin, lateral processes of the vomer almost to its anterior end. The vomer, accordingly, only touches the mid-ventral surface of the chondrocranium in that short ungrooved portion of the surface that lies between the anterior end of the parasphenoid and the beak of the rostrum.

The Nasal (*NA*) is a long and narrow bone, doubly-curved, somewhat like a tall and slender S. Its posterior half curves inward and forward, and lies along the lateral edge of the anterior end of the frontal, directly above the nasal sac. Beyond the frontal the nasal curves downward, outward, and forward, and then inward and forward, its anterior end reaching nearly to the level of the anterior end of the maxillary. In this part of its length it projects beyond the dorso-lateral processes of the ethmoid, and even slightly beyond the anterior end of the chondrocranium, the ends of the two nasals looking like horns on either side of the rostrum. From near the anterior end of each bone a fibrous band, or sometimes two such bands, descend to the lateral process near the lower ventral edge of the anterior end of the maxillary of the same side of the head, and to the adjoining dorsal edge of the anterior end of the premaxillary, as already described.

The nasal is traversed its full length by the supraorbital lateral canal, but the anterior organ of this canal is innervated by a branch of the buccalis facialis, and not by a branch of the ophthalmicus superficialis facialis. The one organ so innervated lies in the curved, projecting, anterior end of the bone, and its general position and innervation seem to indicate, as will be more fully explained in describing the lateral canals, that it corresponds to one of the organs found either in the ethmoid or in the antorbital bone of *Amia*. If such be the case, the nasal of *Scomber* is the equivalent of the nasal of *Amia* plus the antorbital of that fish, or plus that half of the ethmoid of the fish that lies on the corresponding side of the head. In general position it corresponds

much more to an antorbital than to an ethmoid, and its fibrous connection with the maxillary and premaxillary, lateral to the ascending process of the latter bone, are certainly in conformity with the conditions found in *Amia*, the ascending process of the premaxillary of *Scomber* being considered as the homologue of the ethmoid of *Amia* (No. 7). The nasal bone of *Scomber* would, in that case, be more properly called an antorbito-nasal.

In *Amiurus*, McMurrich describes an adnasal bone (No. 48, p. 278). He says of it that it is an anterior continuation of the infraorbital chain of bones, and is traversed by the main infraorbital canal; but the name given to it indicates that it must have closer relations to the nasal bone than to the infraorbital ones. It is said by Collinge (No. 19, p. 280) to be called by some authors the antorbital. It may represent a condition in the fusion of the antorbital with the nasal that is intermediate between the conditions found in *Amia* and those in *Scomber*.

The Frontals (*FR*) occupy more than three fifths of the full length of the dorsal surface of the skull, and form by far the larger part of that surface. In the posterior half of their length they are connected with each other by suture in the middle line of the head. In their anterior halves they diverge slightly from each other, and there disclose a small triangular bit of the chondrocranium and the median portion of the posterior half of the dorsal surface of the ethmoid. The extreme anterior end of each frontal usually turns slightly outward, and it there rests upon the posterior edge of the corresponding dorso-lateral process of the ethmoid.

Proceeding backward from the anterior end of the bone, the frontal widens gradually, with a wavy and irregular lateral edge, until it reaches the postorbital ossification, where it attains its greatest width. Posterior to this point the line of the lateral edge of the frontal is continued by the dorso-lateral edge of the postorbital ossification, the frontal seeming to have its entire postero-lateral corner cut away at a sharp and varying angle. The frontal here lies directly upon the postorbital ossification and a part of the latter bone seems to have here reached the dorsal surface of the skull by the wearing away, figuratively, of the frontal by the overlying dilatator operculi muscle.

Immediately posterior to the hind end of the antorbital cartilage, the frontal forms, for a short distance, the entire roof of the orbit of its side. Near the mesial edge of the ventral surface of this part of the bone, at about the middle of the entire length of the bone, and at about the middle of the orbit, a strong double ridge begins (Fig. 20). Running at first backward and but slightly laterally, this ridge soon begins to gradually curve laterally, and continuing in a more and more lateral direction reaches the lateral edge of the bone at the bottom of the curved or angular piece cut out of it to expose the postorbital ossification. The anterior surface of this ridge slopes downward and backward in a gentle curve, which is continuous, ventral to the ridge, with the orbital surfaces of the alisphenoid and the postorbital ossification. At about the middle of the length of the ridge, on its posterior aspect, a short branch ridge runs mesially, or mesially and slightly backward, to the antero-lateral corner of the median, post-epiphysial interspace of cartilage which has already been referred to and is described below. The entire ridge has thus somewhat the shape of a letter Y. The shank of this Y, and its posterior arm, are both double throughout their entire length, each being formed by two parallel, laminar processes which are directed backward and downward and enclose between them a narrow open space. The anterior arm of the Y is similarly double at its base, but not at its anterior end, the two laminar processes there uniting to a single ridge, thus leaving enclosed between their posterior portions a small wedge-shaped open space. The two laminar processes that form the posterior arm of the Y spread, when they reach the post-epiphysial cartilage, and lying nearly at right angles to each other, diminish gradually in height. The whole structure may otherwise be said to be formed by a combination of three thin laminar processes, one of which is large and slightly curved, and the other two somewhat V-shaped. The slightly curved process forms the anterior surface of the ridge and Y. The two V-shaped ones lie, one between the two arms of the Y, and the other between the posterior arm and the shank of the Y. The space enclosed between these three thin processes is thus Y-shaped with a relatively long shank and very short arms. Into this Y the dorsal end of the alisphenoid is received, that end of that bone being slightly ten-

oned where it fits in between the laminar processes, and being capped with cartilage. The small remnant of the chondrocranium that so lines the dorsal edge of the alisphenoid, thus presents the same intimate but wholly independent relation to the purely dermal frontal, that the cartilage of the lateral edge of the chondrocranium, in *Amia,* does to the purely dermal squamosal of that fish (No. 64, p. 188).

The two arms of the Y-shaped ridge of the frontal, and the corresponding portions of the related alisphenoid, enclose between themselves and the corresponding parts of the opposite side of the head a small anterior portion, or recess, of the cranial cavity. This recess lodges the fore brain and the lobi olfactorii. Anteriorly and ventrally it is not enclosed by bone, the bony brain case there being open toward the orbit. This opening is the orbital opening of the brain case, or orbital fontanelle of my descriptions of *Amia* (No. 5). Its edges give attachment, on each side of the head, to a membrane, which runs mesially downward and forward and connects with the hind end of the median, unpaired, membranous interorbital septum. The two membranes, one on each side of the head, thus close the orbital opening of the brain case, and form the floor of the fore-brain recess. That part of the hind edge of the median, membranous interorbital septum that is joined by, or gives attachment to, the two lateral membranes, is much thickened, especially in its upper and middle portions, and in the latter portion contains a nodule of tough fibrous or fibro-cartilaginous tissue. From this nodule the tough, fibrous, or fibro-cartilaginous eyestalks of the fish take their origin.

The antero-dorsal part of the orbital opening of the brain case is small, lies between the anterior arms of the Y-shaped processes of the frontals of the two sides of the head, and transmits the olfactory nerves. These nerves, after leaving the brain case, run forward in a median anterior extension of the cranial cavity which lies between the ventral surface of the frontals and the spreading, dorsal edge of the membranous interorbital septum. At about the anterior quarter of the septum the cavity ends and the olfactory nerve, on each side, there pierces the septum, laterally, and enters the orbit.

The fore-brain recess of the cranial cavity is limited dorso-posteriorly by the epiphysial ridge. This ridge (*epr,* Fig. 8), starting from the middle line of the head, runs backward and laterally, on each side, its anterior surface being formed by the anterior one of the two laminar plates that form the posterior arm of the Y-shaped ridge of the frontal. The posterior surface of the ridge is formed by the anterior, turned-down end of the small, median, postepiphysial interspace of cartilage already several times referred to. This cartilage fits into a depressed region formed, on the ventral surfaces of the adjoining edges of the frontals, by the spreading of the laminar processes that form the posterior arm of the Y of either side. It is somewhat rectangular in outline, is concave on its ventral surface, and strongly keel-shaped on its dorsal surface, the edge of the keel lying in the median plane of the head. It extends backward nearly to the hind edges of the frontals, where it abuts, with a wavy, transverse edge, against the anterior edge of the supraoccipital, the hind edges of the frontals slightly overlapping the latter bone. The anterior end of the cartilage is convex, or pointed, turns downward, sometimes almost at right angles to the rest of the piece, and ends, sometimes at the free inferior edge of the epiphysial ridge, and sometimes near that edge but separated from it by a thin plate of bone that projects backward from the summit of the ridge. At each of the antero-lateral corners of the cartilage there is a lateral projection from which a narrow line of cartilage extends outward along the dorsal edge of the posterial arm of the slightly Y-shaped dorsal end of the alisphenoid. At the base, or lateral end, of the posterior arm of this Y of the alisphenoid the line of cartilage is continued forward and mesially along the dorsal edge of its anterior arm, and backward and laterally along its shank. At the lateral end of the shank of the Y the line of cartilage joins another line which edges the dorso-mesial edge of the postorbital ossification. Antero-ventrally this latter line lies between the postorbital ossification and the alisphenoid, soon becoming indistinct and fibrous in appearance. Posteriorly it forms a definite but narrow band along the free, dorso-mesial edge of the postorbital ossification; and at the hind end of that bone joins the small interspace of cartilage that lies in the bottom of the temporal groove. This latter inter-

space has a free antero-mesial edge, but is elsewhere bounded by the postorbital ossification, the squamosal, the exoccipitale, and the supraoccipital. From it, as already stated, narrow lines of cartilage run outward between the adjoining edges of the above named bones.

The hind edge of the frontal is irregular and jagged in outline, and the dorsal surface of the posterior portion of the bone is deeply grooved to form the anterior portions of the three deep grooves that here occupy almost the entire dorsal surface of the skull. The ventral surface of the frontal gives little or no indication of these grooves. The hind edge of the bone overlaps the anterior edge of the supraoccipital, and overlaps partly, and is partly overlapped by the anterior edge of the parietal. The posterior portion of its lateral edge overlaps the mesial edge of the postorbital ossification. The two thin dorsal ridges of the bone that separate the anterior ends of the three dorsal grooves, overlap mesially corresponding ridges on the parietal and squamosal. The parietal is only slightly so overlapped, the squamosal is overlapped to a considerable extent. On the summit of the fronto-squamosal ridge, between the adjoining and overlapping edges of the frontal and squamosal and extending forward onto the frontal alone, there is a relatively wide groove which lodges a part of the main infraorbital lateral canal.

The frontal is traversed, through a large part of its length, by the supraorbital lateral canal, the hind end of that canal lying in those parts of the bone that form the anterior end of the floor of the supratemporal groove and the anterior end of the floor and also of the lateral bounding wall of the temporal groove. The canal thus lies internal to the anterior ends of those anterior extensions of the trunk muscles that fill the grooves. In *Amia* the corresponding part of the canal lies external to the morphological plane of the dorsal surface of the trunk muscles, although these muscles do not extend far enough forward to come into direct relations with the canal. In *Scomber* those parts of the parietal, squamosal, and exoccipitale that form the floor of these same grooves all have the same relations to the muscles that the frontals have, that is, they lie internal to them. In *Amia*, the anterior extension of the trunk muscles lies internal to the parietal and inter-

nal to the dermal part of the squamosal, but external to the small V-shaped process that is beginning to grow downward from the latter bone along the outer surface of the cartilage of the skull. In both fishes the extrascapulars lie external to the muscles. Since the hind ends of the frontals, in both fishes, lodge portions of the lateral canals, they must be, in both, of similar origin, and this is doubtless true also of the parietals. The conditions presented by the two fishes thus seem most decidedly to indicate different lines of descent from some fish in which the trunk muscles had not as yet invaded the dorsal surface of the skull. In *Scomber* the muscles have pushed upward and forward between the front end of the extrascapular and the hind ends of the parietal and frontal; in *Amia* they have pushed forward below the latter bones. In the dilatator groove, the dilatator operculi, which also invades the dorsal surface of the skull in *Scomber,* pushes forward wholly external to the frontal but internal to the dorsal end of the suborbital part of the main infraorbital canal.

The Postorbital Ossification (*PST*) is an irregular ossification of the dorso-lateral corner of the postorbital process of the skull. It has three exposed faces, an anterior, a lateral and a dorsal one. The anterior face looks forward and downward, and forms part of the hind wall of the orbit. The lateral face looks downward and laterally, and lies nearly at right angles to the anterior one. The lateral, and larger part of the dorsal face of the bone forms the lateral part of the middle portion of the floor of the dilatator groove, lying between the frontal in front and the squamosal behind. The remaining, mesial portion of the dorsal face of the bone is thin, forms part of the roof of the cranial cavity, and is almost entirely covered by parts of the frontal, parietal and squamosal. That small portion of it that is not so covered lies in the floor of the temporal groove, where it forms the lateral part of the ledge that separates the antero-superior portion of the groove from its posterior, depressed portion. A large anterior process of the squamosal lies between this little exposed surface of the bone and that part of the bone that is exposed in the bottom of the dilatator groove.

A broad, shallow and tapering groove runs mesially and forward across the dorsal face of the ossification immediately lateral

to the overlapping anterior process of the squamosal. This wide groove forms, as already stated, a postero-mesial, slightly depressed portion of the dilatator groove, and the hind end of its antero-lateral edge usually projects upward as a small angular process, the process and edge marking the line of insertion of a median tendon of the dilatator operculi muscle. Immediately ventral to the hind end of the anterior edge of the groove, on the lateral surface of the ossification, there is a shallow but relatively large depression which forms the articular facet for the anterior articular head of the hyomandibular. The long axis of this facet inclines upward and backward at about 45°, and the facet, although lying entirely in the postorbital ossification, extends backward almost, or quite, to the anterior edge of the squamosal.

The postorbital ossification is not traversed by any portion of the lateral canals. The main infraorbital canal, as it leaves the open groove between the adjoining edges of the frontal and squamosal and runs forward and downward behind the eye, passes first through the dermal or subdermal tissues that lie immediately dorsal to the dilatator operculi muscle, and then enters a series of thin and delicate bones that lie wholly external to the muscles of this part of the head. The first, or most dorsal of these bones, which is quite certainly the homologue of the postfrontal bone of *Amia,* lies directly superficial to the dorsal surface of the postorbital ossification but is separated from it by the anterior portion of the dilatator operculi. The postorbital ossification of *Scomber* thus has no dermal component, and is, accordingly, the exact homologue of the postorbital ossification of my descriptions of *Amia.* It has, however, in *Scomber,* invaded the anterior part of the region that gives articulation to the hyomandibular; lies, to a considerable extent, ventro-internal to the squamosal; and has, as seen in Fig. 4, left, entirely, the general outer level of the dorsal surface of the head. It thus seems to be moving downward along the side of the skull, toward a position corresponding to that occupied by the prootic part of the temporal bone of man (No. 5).

The ossification adjoins the squamosal behind, the petrosal ventrally and postero-ventrally, and the alisphenoid antero-mesially. Dorsally it is separated from the adjoining edges of these bones by distinct, but narrow lines of cartilage; ventrally these lines of

cartilage become indistinct, or disappear entirely. The dorso-mesial edge of the bone is edged with cartilage and bounds, in its middle portion, the large dorso-lateral fontanelle of the chondrocranium. Posteriorly this edge of the bone bounds the temporal interspace of cartilage.

On the anterior, or orbital face of the ossification there is always a large and deep pit (*ofc*, Figs. 5, 9), from the hind end of which one or two canals lead upward to the dorsal surface of the bone, near its lateral edge. The pit, and one or both of the canals, transmit the ramus oticus facialis from the orbit to the dorsal surface of the skull, but the pit is much larger than need be simply for the passage of the nerve. On the lateral surface of the ossification there is usually, but not always, an opening, often large, which leads into the hind end of this pit, but no nerve or vessel could be found traversing it. Its position, so similar to that of the ventral opening of the spiracular canal in *Amia*, and its relation to a canal that transmits the otic nerve, both seem to indicate that it, or it and the otic canal together, represent rudiments of the spiracular canal of the fish.

The internal, or cerebral surface of the ossification is relatively small. It presents two recesses, or pit-like depressions, separated by a narrow, nearly vertical ridge of bone which projects backward and mesially into the cranial cavity and represents a part of the anterior bounding wall of the labyrinth recess. Both depressions are, in the recent state, filled with fatty tissue. The anterior and larger one has, in the adult, no apparent relations to any of the organs contained in the cranial cavity. The posterior one apparently lodged, in larvæ, the anterior end of the anterior semicircular canal of the ear. In the adult it does not, however, lodge that canal, the canal turning upward considerably posterior to the bottom of the recess. At the bottom of one or both of the recesses a small foramen was sometimes found from which a short canal leads toward or even into the large pit that transmits the otic nerve. Although this canal, when found, did not seem to have been artificially produced, there was nothing whatever to indicate its significance.

The Alisphenoid (*AS*) is a nearly rectangular bone, forming somewhat more than half of the hind wall of the orbit. It inclines

forward, upward and but slightly laterally, at an angle of about 45° to a horizontal plane. The dorsal end of its antero-mesial edge is thickened and slightly notched with a V-shaped notch, thus giving to the dorsal edge of the bone somewhat the shape of a Y with a long shank and very short arms. The dorsal end of the postero-lateral edge of the bone is bent slightly backward, and lies in a nearly vertical position. The entire dorsal edge of the bone is edged with cartilage and is slightly tenonned its full length, both on its external and internal surfaces. This tenoned end of the bone, with its cap of cartilage, fits into the Y-shaped space between the three laminar processes that form the Y-shaped ridge on the ventral surface of the frontal.

Laterally the alisphenoid abuts against the postorbital ossification, and ventrally against the petrosal and basisphenoid. Anteromesially it has a free edge which presents a large, shallow, reentrant angle. This edge of the bone forms the ventral and larger part of the lateral boundary of the large, median, orbital opening of the brain case. The dorsal part of the lateral edge of this opening, and part of its dorsal edge also, are formed, on each side, as already stated, by the ventral edge of the anterior part of the anterior arm of the Y-shaped ridge of the frontal. Its ventral edge is formed by the anterior edge of the median basisphenoid. The dorsal and smaller part of the opening lies immediately ventral to the lobi olfactorii; its larger, ventral portion lying immediately ventral to the fore brain and the optic chiasma. The opening is, in the recent state, entirely closed by membrane excepting in its extreme dorsal portion, where it transmits the olfactory nerves, as already described. Through its larger, ventral portion it transmits, on each side, the nervi opticus and trochlearis, both of which pierce the membrane that closes the opening and issue directly from the cranial cavity into the hind end of the orbit. The opticus pierces the membrane close to the middle line of the head, between the anterior edge of the basisphenoid and the hind end of the tough fibrous nodule that gives origin to the eye-stalks. It lies, as it issues, postero-ventral to the eye-stalk, slightly in front of the extreme hind end of the orbit and about midway in height between the floor and roof of the orbit. It issues through the extreme hind edge of the interorbital septum as much as, or even

more than, through the membrane that closes the orbital opening of the brain case. The trochlearis pierces the orbital membrane dorso-lateral to the opticus, at its extreme lateral edge, lying, as it issues, at the apex of the large reëntrant angle in the antero-mesial edge of the alisphenoid. This apex of the angle, which is rounded, is accordingly the partly formed foramen of the nerve (*trfr*). A blood vessel perforates the bone near its antero-mesial edge, slightly dorso-anterior to the trochlearis notch. The foramen (*acvfr*) is an exceedingly small one, and corresponds in position to the foramen that, in *Amia,* transmits the anterior cerebral vein. No attempt was made to trace the vein in *Scomber.*

Between the antero-ventral corner of the alisphenoid, the lateral edge of the basisphenoid and the anterior edge of the petrosal, there is a relatively large foramen (*ocmfr*), through which the nervus oculomotorius leaves the cranial cavity and enters the extreme anterior end of the eye-muscle canal.

The Basisphenoid (*BS*) of *Scomber,* is, as in most teleosts, a small, median, Y-shaped bone. The shank of the Y is thin, slender and slightly curved, and lies nearly vertically in the middle plane of the head. Its upper and lower ends turn slightly backward, the latter end being strongly attached to the dorsal surface of the parasphenoid in a slight, median depression of that bone, about opposite the anterior edges of its lateral wings. The depression usually lodges a tiny bit of cartilage, which represents a small remnant of the cartilaginous interorbital septum. The arms of the bone are much broader and stronger than the shank. They project laterally and slightly upward, and lie in an inclined position, their flat dorsal surfaces being presented upward, backward and mesially. Their outer ends are about twice as wide as their bases, are serrated, and connect by suture, on each side, with the alisphenoid and petrosal. In the middle of the outer edge of each arm, usually directly opposite the sutural line between the alisphenoid and petrosal, there is a deep, rounded indentation, which forms, with the adjoining bones, the foramen for the nervus oculomotorius. This foramen varies slightly in position in different specimens, and is said by Stannius (No. 70, p. 16) to lie in the " Knöchernen Keilbeinflügel."

Immediately behind the arms, or wings, of the basisphenoid, between them and the united anterior edges of the mesial, horizontal processes of the petrosals, lies the relatively large, oval or subtriangular opening of the pituitary fossa. Through this opening the hypophysis cerebri and saccus vasculosus, enclosed in a shallow sac of the dura mater, project downward into the anterior end of the eye-muscle canal.

The internal carotid arteries run upward immediately in front of the front edge of the basisphenoid, as they do, in larvæ of *Amia,* in front of the dorso-anterior edge of the cartilaginous transverse bar of the chondrocranium (No. 4, p. 497, and No. 5). There, in *Scomber,* they pierce the membranes that close the orbital opening of the brain case, close to the middle line of the head, and enter the cranial cavity.

The anterior edge of the shank of the basisphenoid gives attachment to the hind edge of the ventral half, approximately, of the membranous interorbital septum, the anterior edges of the wings of the bone giving attachment, on each side, to the lower end of the membrane that closes the orbital opening of the brain case.

No Orbitosphenoid is found in *Scomber.*

The Interorbital Septum is membranous throughout its entire extent excepting only in those parts that are represented in the shank of the basisphenoid, in the short dorsal and ventral processes of the antorbital cartilage, and in the cartilaginous ridge that connects those processes with each other along the middle line of the posterior surface of the cartilage. Posterior to the shank of the basisphenoid there is a median membranous septum that extends backward from the shank of the bone to the hind end of the eye-muscle canal, and it would seem to be, in certain specimens and in part of its extent, a posterior extension of the interorbital septum.

The dorsal edge of the middle portion of the interorbital septum encloses the proximal ends of the olfactory nerves. This part of the septum thus belongs to the interorbital side walls of the skull rather than to an unpaired interorbital septum, and the canal or chamber that it encloses is, according to Sagemehl's descriptions, an anterior part of the cranial cavity. Posterior to the hind end of this canal, the dorsal, or dorso-posterior edge of the septum

is, as already stated, thickened and runs downward and backward to the anterior edge of the basisphenoid. Starting from the anterior portion of the olfactory extension of the cranial cavity there are always, in the interorbital membrane, fibrous lines, which run downward and forward toward the ventral process of the antorbital cartilage, and there gradually disappear. In many of the specimens examined, a small opening pierced the septum, immediately in front of these fibrous lines. It did not seem to have been artificially produced, in any of the specimens where it was found, but it seemed to have no relation whatever to any of the orbital structures.

The optic nerves, as already stated, pierce the hind edge of the interorbital septum immediately in front of the basisphenoid; and about midway between these nerves and the hind end of the membranous olfactory chamber, the eye-stalks have their origin, arising from a semicartilaginous nodule in the thickened hind edge of the septum. The eye-stalk, on each side, runs forward and laterally, along the dorso-anterior surface of the opticus, and is inserted on the eye-ball close to the place where the opticus enters it. In section the eye-stalk is round. It has a tough, fibrous, peripheral covering, and a somewhat gelatinous interior which resembles, in general appearance, the tissue that fills the spaces between adjoining vertebræ. In alcoholic preparations the entire stalk becomes semi-cartilaginous in appearance.

From the anterior part of the interorbital septum, immediately in front of the fibrous lines that run downward and forward from the olfactory extension of the cranial cavity, the obliqui muscles have their origin. The surface of origin of these muscles is oval, with its long axis directed upward and backward, and it lies immediately ventral to that part of the olfactorius that lies free in the orbit. As the muscles arise entirely from the interorbital membrane, the existence of an anterior eye-muscle canal in *Scomber* may perhaps be questioned, although the large recess that lies between the septum and the orbital rib of the preorbital ossification, or the smaller ventral part alone of that recess, occupy the position of such a canal. If this recess is the representative, in *Scomber,* of the so-called anterior eye-muscle canal of certain teleosts, it is evident that the canal must, in this fish, owe its origin

to inheritance, or to other causes than a simple invasion of the obliqui muscles of the adult animal.

The olfactory nerve, after it leaves the anterior olfactory extension of the cranial cavity, traverses the anterior part of the orbit and so reaches the olfactory canal through the antorbital process, which it traverses accompanied by two veins. In *Amia* the olfactory nerve does not so enter the orbit. In that fish it simply runs across a relatively large opening that lies ventro-lateral to the nerve and opens directly from the long olfactory canal of the fish into the extreme anterior end of the orbit (No. 4, p. 513). This opening in *Amia* gives passage to a vein coming from the nasal pit, and was considered by me as the homologue of the posterior opening of the orbito-nasal canal of Selachians. I accordingly called it the orbito-nasal opening. Immediately ventral to it, in *Amia,* the obliqui muscles have their origin, arising in a slight depression in the cartilage of the chondrocranium.

The orbito-nasal opening of *Amia* is thus seen to be entirely wanting as a distinct and separate opening in *Scomber.* It may, in this latter fish, be simply fused with the posterior opening of the olfactory canal through the antorbital process, or, what seems much more probable, it may have become so greatly enlarged in *Scomber,* by the deepening of the orbit, that it has entirely disappeared as a separate feature of the skull. If this be so, the slight ridge that is always found on the orbital face of the pre-orbital ossification, close to the ventro-lateral edge of the posterior opening of the olfactory canal, may be a persisting part of the edge of the former opening; and as the lower end of this ridge lies approximately opposite the lower edge of the surface of origin of the obliqui muscles, the posterior outline of that surface may represent the former continuation of the edge of the opening. The olfactory nerve of *Scomber* would, in that case, simply run across the opening, as it does in *Amia,* the great enlargement of the opening and the concomitant narrowing of the interorbital septum leaving it free in the orbit.

The Petrosal (*PE*) is an irregular bone of somewhat variable shape. Its outline, as seen from the outer surface of the skull, is not at all that of the thick body of the bone, thin plates of bone, with serrated edges, projecting in several directions from its super-

ficial layers and giving to it a superficial outline somewhat different in every specimen. Roughly speaking it may be said to usually have six edges or sides, and to be composed of the usual two portions, a body and a mesial, horizontal process, or wing.

The body of the bone articulates posteriorly with the basioccipital and occipitale laterale; dorso-posteriorly with the squamosal; dorso-anteriorly with the postorbital ossification; and anteriorly with the alisphenoid. Antero-ventrally it is overlapped by the lateral wing of the parasphenoid; and ventrally by the body of the parasphenoid. Dorso-posteriorly, where it adjoins the sutural corner between the squamosal and occipitale laterale it is overlapped, externally, and to a variable extent, by the intercalar, this latter bone thus forming one of the bounding bones in external views of the skull. The mesial, horizontal process of the bone articulates with its fellow of the opposite side of the head, and with the alisphenoid and basisphenoid.

Of these several so-called articulations those with the basioccipital, occipitale laterale, squamosal, and postorbital ossification are in greater part simply juxtapositions, the two articulating bones being everywhere separated, excepting near the outer surface, by a narrow, but distinct line of tissue or cartilage. At the outer surface the thin, serrated plates that arise from the superficial layer of the bone project, as thin splint-like processes, and dovetail into corresponding processes or depressions on the edges of the adjoining bones, thus giving rise to what seem to be the beginnings of true sutural articulations.

Where the petrosal adjoins the parasphenoid the edge of the latter bone simply overlaps, superficially, the adjoining edge of the petrosal. That part of the edge of the petrosal that is so overlapped by the body of the parasphenoid, is edged with a broad band of cartilage, which, at the hind end of the petrosal, turns upward between that bone and the basioccipital, and is continued as a narrow cartilaginous line separating the two bones. The inferior edge of this band of cartilage is presented ventro-mesially, and is separated from the corresponding edge of the band of the opposite side of the head by the relatively wide hypophysial fenestra.

Where the petrosal is overlapped by the intercalar the extreme outer edge of the latter bone projects, in places, under short scale-like processes on the outer surface of the petrosal. Similar scale-like processes of the occipitale laterale overlap, also, the outer edge of that part of the intercalar that lies superficial to it. While all of these processes are excedingly delicate, and unimportant in size, they are always found, and hence may possibly represent a stage in that primary assimilation of the intercalar that Sagemehl believed in.

The mesial, horizontal process of the petrosal has, in *Scomber,* two portions, a posterior and an anterior one. The posterior portion lies posterior to the pituitary opening of the cranial cavity, the anterior portion anterior to that opening. The posterior portion thus corresponds to, and is the homologue of, the entire horizontal process of the petrosals of *Amia* and the Characinidæ, in all of which fishes the anterior edge of the process lies posterior to the pituitary body (No. 64, p. 214, and No. 65, p. 87). In most of the Cyprinidæ the same conditions and relations are found, but in certain of those fishes (No. 66, p. 575) an arrangement somewhat similar to that found in *Scomber* seems to exist. The descriptions of these latter fishes are, however, not concise in this particular, and what is bone in *Scomber* may, in the cyprinoids referred to, be simply membrane.

The posterior part of the process, in *Scomber,* adjoins posteriorly the anterior edge of the basioccipital, and medianly the corresponding edge of its fellow of the opposite side of the head. It is separated from the basioccipital by a narrow line of cartilage, which, in the middle line of the head, extends forward between the adjoining edges of the processes of the two sides of the head for about one half their length. The process forms, in *Scomber,* as in other fishes, a part of the floor of the cranial cavity, and a part of the roof of the eye-muscle canal. It is pierced, near its lateral edge, and somewhat in front of the middle of its length, by the foramen for the nervus abducens (*abfr,* Fig. 22). Its anterior edge forms the posterior edge of the pituitary opening, that opening occupying only about two thirds the width of the process (*pto,* Fig. 22). Lateral to the pituitary opening a narrow part of the process connects its posterior portion with the anterior portion,

the latter portion being only one third or one half as long, in an antero-posterior direction, as the former. The anterior portion is flat, projects mesially and slightly forward, and lies in a plane inclined upward at about 45° to the plane of the posterior portion. Its hind edge forms the lateral portion of the anterior edge of the pituitary opening, and its mesial edge articulates with the lateral edge of the basisphenoid. The mesial edge is deeply cut out, usually at about the middle of its length, by the foramen for the nervus oculomotorius. This portion of the process forms, as does the posterior portion, a part of the floor of the cranial cavity and a corresponding part of the roof of the eye-muscle canal. Its dorso-anterior edge lies in a nearly horizontal position, is directed mesially and but slightly forward, and forms that part of the petrosal that articulates with the alisphenoid. The petrosal thus articulates with the alisphenoid by a part of its mesial, horizontal process, and not by a part of the body of the bone. The ventral, or ventro-anterior surface of the anterior process forms a direct continuation of the external surface of the alisphenoid, the two bones being separated by a nearly horizontal line, which may be considered as marking the indefinite limit between the hind wall of the orbit and the roof of the eye-muscle canal. The anterior process can be called, for convenience, the basisphenoid process of the bone, the term horizontal process, or wing, being retained for the posterior portion alone.

Ventral to the horizontal process of the petrosal, the body of the bone is as thin as the process itself, and has as much the appearance of being a process of the bone, as the so-called process. The ventral half of the entire bone, in fact, presents decidedly the appearance of a thick bone, the ventral edge of which has been deeply hollowed out by the strongly developed eye-muscle canal. In *Salmo,* the ventral part of the body of the petrosal is said by Parker (No. 50, p. 102) to be preformed as a cartilaginous lamella, which grows downward, on each side, from the investing mass, "thus forming a covered archway." The horizontal process of the petrosal is thus preformed, in *Salmo,* before the ventral part of the body of the bone. In *Amia,* on the contrary, the body of the bone is preformed before the first appearance of its horizontal process (No. 4, p. 505).

On the outer surface of the petrosal, there is a depressed region, narrow and shallow in front, but wide and deep behind. It forms the anterior portion of the large depressed region, of which mention has already been made, on the hind end of the lateral surface of the skull. It lies opposite or immediately dorsal to the line where, on the inner surface of the petrosal, the mesial, horizontal process of the bone is given off. In the anterior half of the bone, immediately dorsal to the bottom of this depression and immediately beneath the external surface of the bone, there is a short but relatively large, nearly horizontal canal, or chamber (Fig. 11). This chamber is always slightly curved, the hollow of the curve presented upward, and it is wider at its middle point than at its ends. The ventro-mesial portion of the chamber is separated from the dorso-lateral corner of the eye-muscle canal by only a thin layer of bone. The external wall of the chamber is also formed by a thin layer only of bone, which, at the anterior end of the chamber, usually lies nearly flush with the outer surface of the petrosal, but at its posterior end rises in a gentle curve slightly above the level of the adjacent portions of the bone.

The anterior opening of this chamber is much larger than the posterior one, and lies so close to the thick, anterior edge of the petrosal that it can be considered as cut out of that edge, and as opening onto it rather than onto the outer surface of the bone. It is a long and relatively narrow opening, the long axis of which lies in a nearly horizontal position. It extends forward and mesially to the sutural line between the alisphenoid and petrosal, and there lies directly lateral to the oculomotorius foramen, which foramen, as already stated, lies between the basisphenoid and the basisphenoidal process of the petrosal. The middle point of the opening lies directly below the ventral end of the sutural line between the alisphenoid and postorbital ossification; and on the outer surfaces of the adjoining edges of those two bones there is a wide, but very shallow, hour-glass-shaped depression, not always distinctly marked, which continues the line of the canal in the petrosal upward and forward to the lower edge of the ventral, laminar process of the frontal, where it disappears. The depression is filled, in the recent state, with tough membranous tissue which is continuous, anteriorly, with the membranes lining the orbit; pos-

teriorly it is connected with a tendinous membrane which seems to represent, as will be later shown, the first and second divisions of the levator maxillæ superioris muscle of the fish.

The anterior opening of the chamber thus lies ventro-posterior to the alisphenoid. It transmits, among other structures, the rami ophthalmicus superficialis and buccalis facialis, the ramus ophthalmicus superficialis trigemini, the truncus maxillaris trigemini, and the truncus ciliaris profundi. It is accordingly, in a measure, the fused external opening of the foramina of those several structures. In *Amia* the radix profundi, from which the ciliary nerves arise, is transmitted through an opening that lies anterior to the alisphenoid, the ophthalmic and maxillary branches of the trigeminus and the ophthalmic and buccal branches of the facialis issuing by foramina that lie posterior to that bone. The position of the single opening which, in *Scomber,* transmits all these nerves, indicates that they have become so associated by mutually approaching each other along the ventral edge of the alisphenoid, in the sutural line between that bone and the basisphenoid and petrosal, and not by traversing the alisphenoid. There is, accordingly, nothing here to indicate that a nerve found in front of a certain element of the skull in one animal can traverse that element in another animal, and attain, in that manner, a position behind it. The arrangement in *Scomber* seems, on the contrary, to show that when a nerve changes its position relative to a bone it does so by passing around it instead of through it.

The posterior opening of the chamber is flat, looks backward and slightly upward, and lies approximately in the mid-vertical line of the outer surface of the petrosal, slightly dorsal to its middle point. A slight ridge runs backward, on the outer surface of the bone, from each edge of the opening, the ventral ridge being much more pronounced than the dorsal one. The slight groove that lies between the two ridges marks the course of certain of the structures that are transmitted by the opening.

The chamber gives passage to a sympathetic nerve, to a communicating branch from the truncus maxillaris trigemini to the truncus facialis, to the orbital branch of the jugular vein, and to the external carotid artery. On the sympathetic nerve a large ganglion is formed, which lies partly in the chamber and in part immediately beyond its anterior opening.

Inside the chamber there are four openings leading into canals in the petrosal. Three of these canals are simply foramina that lead through the side wall of the skull into the cranial cavity, and serve, one for the exit of the truncus ciliaris, and the other two for the exits of the anterior and posterior trunks of the trigemino-facial ganglion. As the truncus ciliaris arises from the profundus ganglion, the foramen by which it issues from the cranial cavity is the profundus foramen of the fish. It usually lies slightly ventral, or ventro-anterior to the anterior one of the other two foramina, which are respectively the trigeminal and facial foramina. Whether these three openings leading from the cranial cavity into the trigemino-facial chamber, or the two external openings of the latter chamber, are the strict homologues of the corresponding foramina described in other fishes seems open to some question. The fourth opening in the chamber leads into a small, but relatively long canal, which traverses the thin, ventral portion of the body of the petrosal to its antero-ventral edge, and there opens into the eye-muscle canal immediately at or slightly behind the hind edge of the lateral wing of the parasphenoid. It transmits the ramus palatinus facialis, and can accordingly be called the palatine canal. It is, however, the approximate homologue of the palatine foramen of *Amia,* and not at all the homologue of the canal described by me as the palatine canal in that fish.

The trigemino-facial chamber of *Scomber* was apparently not recognized by Stannius, or possibly, though it seems hardly probable, it did not exist in the specimens examined by him. Whether, in the latter case, it had not been formed at all, or had been formed and then separated into two parts by the later formation of a bony partition between the openings of the canals that trasmit the facial and trigeminal nerves, is impossible to tell from the descriptions; for, while the communicating branch from the truncus trigemini to the truncus facialis is said by Stannius to lie outside the skull (No. 70, p. 47), the canal for the palatinus facialis is said to be a branch of the canal that transmits the nervus facialis, and to lie "zwischen den gesonderten Austrittstellen des *N. trigeminus* und *N. facialis*" (No. 70, p. 55). The profundus canal and foramen are not mentioned by Stannius.

In *Alepocephalus,* Gegenbaur (No. 29) describes a bridge of bone that separates the facial foramen into two parts. The trigeminal foramen is said to lie in front of the anterior one of these so-formed facial foramina, near the anterior edge of the petrosal, on what is described as the orbital surface of that bone. This disposition of the three foramina seems to indicate that the anterior of the two facial foramina described serves for the passage of the united ophthalmicus facialis and buccalis facialis; the posterior opening serving for the passage of the truncus hyoideo-mandibularis facialis. Such being the case, the space enclosed beneath the bridge of bone in *Alepocephalus* seems to be the exact homologue of the trigemino-facial chamber of *Scomber,* excepting that, in being smaller, the trigeminal foramen is not enclosed within it.

The internal surface of the petrosal of *Scomber* is concave and irregular. Starting, approximately, at the base of the hind edge of the horizontal process of the bone and running across the bone, from behind, upward and forward, there is a ridge, more or less developed in different specimens, which separates the surface into two nearly equal regions. The several foramina that pierce the bone all lie in front of, or antero-mesial to, this ridge; the labyrinth lies behind, or postero-lateral to it. It is, accordingly, a remnant of the anterior wall of the labyrinth chamber, and is strictly homologous with the more pronounced ridge that marks the position of that wall in *Amia* (No. 4, Fig. 11, Pl. XXI). Immediately lateral to the posterior third of this ridge there is a deep, sharp groove (Fig. 63), which forms the anterior portion of a long groove that lodges the sacculus. The extreme anterior end of the groove runs forward a little beyond the anterior edge of its cerebral opening, and ends blindly in the body of the petrosal a little below the middle point of the bone. Dorso-lateral to the anterior end of the ridge there is a deep, oval depression which lodges the ventral end of the anterior semicircular canal. This depression is connected with the anterior end of the saccular groove by a shallow groove or depression which lodges that part of the membranous ear from which the external semicircular canal takes its origin. Immediately dorsal to this last depression the thick dorsal edge of the petrosal is deeply cut out, on its cerebral margin, a

large and almost completely enclosed circular opening being formed which gives passage to the external semicircular canal.

The ventral edge of the petrosal is cut out by a semicircular opening, the internal carotid incisure, which lies opposite the angle formed where the hind edge of the lateral wing of the parasphenoid joins the lateral edge of the body of that bone. Through this opening, the internal carotid artery enters the eye-muscle canal, where it runs forward to the anterior edge of the basisphenoid, there turning upward to enter the cranial cavity through the orbital opening of the brain case.

The Parasphenoid (*PS*) covers the ventral surface of the primordial cranium through nearly its entire length, extending from close to the hind end of the basioccipital bone forward almost to the anterior end of the antorbital cartilage. The bone consists of a long, thin body and two lateral ascending processes or wings, one on either side. The lateral processes lie at about the posterior third of the bone. Immediately in front of them the bone is narrow and stout, widening gradually, and becoming gradually flatter and thinner, toward its anterior end. Between and behind the wings the bone is broader, curves gradually upward and backward to its hind end, and upward and laterally, on each side, to its lateral edges. This part of the bone is thus strongly convex on its ventral surface and concave on its dorsal surface. In the median line of the posterior half of this posterior portion, on its dorsal surface, there is a deep longitudinal channel the nearly parallel sides of which correspond approximately with the edges of the hypophysial fenestra. It is deepest in its middle portion, gradually disappearing both anteriorly and posteriorly. It forms the bottom of the eye-muscle canal. At the hind end of the parasphenoid the channel occupies nearly the full width of the bone. The hind edge of the bone is thin and usually frayed.

The lateral wings of the parasphenoid are flat, curved, and sharply pointed processes, directed upward, forward and laterally. The anterior edge of each process is concave, its posterior edge convex. The hind edge overlaps externally the anterior part of the ventral edge of the petrosal, the sharp dorsal point of the process not quite reaching the level of the ventral surface of the horizontal process of the petrosal. The concave anterior edge

of the process forms the ventral part of the hind edge of the orbit and the larger part of the lateral edge of the orbital opening of the eye-muscle canal. Between the petrosal and the hind edge of the process, in the angle between that hind edge and the lateral edge of the body of the bone, lies the internal carotid foramen (*icfr*, Figs. 7, 18). A small process of bone sometimes separates the anterior edge of this foramen from the hind edge of the lateral wing of the bone, the foramen thus being partly enclosed in the parasphenoid.

The anterior end of the parasphenoid is thin and is overlapped ventrally for a considerable distance by the hind end of the vomer, a depressed region on its external surface receiving the latter bone. On the dorsal surface of this part of the parasphenoid, there is a long median ridge which fits into a corresponding groove on the ventral surface of the chondrocranium. Posteriorly, toward the middle of the orbit, the ridge gradually disappears. This ridge may represent the beginning of the formation of the vomer bone of mammals from the parasphenoid of fishes (No. 7, p. 458).

On the ventral surface of the parasphenoid, between its lateral wings, there is a strong median ridge which separates the surface of insertion of the adductor arcus palatini of one side of the head from that of the corresponding muscle of the other side.

The Eye-Muscle Canal is large, extending from the basisphenoid, backward, almost to the extreme hind end of the skull. Its anterior end is wide, its posterior end narrow, the canal tapering gradually from one end to the other. Its orbital opening, on each side, is formed by the anterior edge of the lateral wing of the parasphenoid, by a part of the anterior edge of the petrosal and a part of the basisphenoidal process of that bone, by the inferior surface of the horizontal wing of the basisphenoid, and by the shank of the latter bone. The shank of the basisphenoid separates the anterior end of the canal into its two parts or openings.

The roof of the eye-muscle canal is formed by the wings of the basisphenoid, by the membrane that closes the pituitary opening of the cranial cavity, by both the anterior and posterior portions of the mesial, horizontal processes of the petrosals, and by a

corresponding median, horizontal portion of the basioccipital. Its sides are formed by the thin, ventral, laminar portions of the bodies of the petrosals, and by corresponding ventral portions of the basioccipital. These latter portions of these three bones are concave internally and convex externally, and the portions of opposite sides of the head approach each other, but do not meet, in the mid-ventral line. A relatively wide, median, longitudinal opening is thus left between the ventral ends of the bones, the opening extending the full length of the bottom of the canal. This median opening, which is not closed anteriorly, is the hypophysial fenestra of Sagemehl's descriptions of other teleosts. It is covered and closed ventrally by the parasphenoid, a median portion of the dorsal surface of that bone forming the floor of the eye-muscle canal.

Arising from the hind edge of the shank of the basisphenoid there is a median membrane which extends backward to the hind end of the eye-muscle canal and has its insertion there. Its ventral edge is free, excepting, perhaps, at its anterior end. Its dorsal edge is inserted on the ventral surface of a stronger, horizontal membrane, which also extends the full length of the eye-muscle canal. The lateral edges of this horizontal membrane are free in the anterior quarter, approximately, of its length. In the posterior three fourth of its length they are inserted on the lateral walls of the canal; that is on the internal surfaces of the petrosals and the basioccipital. The horizontal membrane separates the eye-muscle canal into two parts, a dorsal and a ventral one, the dorsal part being much the larger of the two. The median, vertical membrane partly separates the ventral part of the canal into two lateral halves. The horizontal membrane gives insertion at its anterior end to the rectus superior muscle, and, on a part of its ventral surface, to the rectus internus. It lies ventral to the rectus externus, that muscle arising entirely from the side-walls of the eye-muscle canal and not from the dorsal surface of the membrane. The vertical membrane lies between the two recti interni, but does not give origin to any important part of their fibers. The horizontal membrane thus seems to be developed in some connection with the tendinous insertions of certain of the recti muscles, the vertical membrane being, perhaps, a posterior continuation of the interorbital membrane.

The orbital openings of the eye-muscle canal give passage, on each side, to two of the recti muscles, the externus and internus, to the internal carotid artery, to the ramus palatinus facialis, and to a large venous vessel. The rectus superior arises at the edge of the opening. The large venous vessel is formed by the union of two veins that come from the nasal pit, through the olfactory canal in the antorbital process, with a third vein that comes from the eye-ball. The course of this vessel after it entered the eye-muscle canal was not traced. As it is evidently, in part at least, the homologue of the vein described by me in *Amia* as the vein *vo* (No. 4) it probably communicates, in the eye-muscle canal, with the corresponding vein of the opposite side of the head, and receives, or gives a branch to the hypophysis and saccus vasculosus. The internal carotid artery, on each side, turns upward immediately in front of the basisphenoid and enters the cranial cavity, receiving, as it turns upward, a delicate communicating branch from the efferent artery of the opercular gill, which is the arteria ophthalmica magna of the fish. This same communicating branch is found in *Amia* (No. 4).

The orbital opening of the eye-muscle canal of *Scomber* is thus the morphological equivalent, in the structures it transmits, of the ventral part, and that part only, of the orbital opening of the canal in *Amia*. The internal carotid artery and the ramus palatinus facialis which, in *Scomber,* enter the eye-muscle canal, and issue from it by its orbital opening, form no exceptions to this statement, for both these structures would, in *Amia,* of necessity lie in, and issue from the orbital opening of, the eye-muscle canal, if the hypophysial fenestra of *Amia* were to be enlarged, and the cartilage of the basis cranii in front of it disappear, as it has in *Scomber*.

In *Amia,* the dorsal part of the orbital opening of the eye-muscle canal, which lies anterior to the shank of the alisphenoid, gives passage to the nervus trochlearis, radix profundi, nervus oculomotorius, and an orbital extension of the jugular vein, the two latter structures lying near the middle of the opening, ventral to the other two. In *Scomber,* the trochlearis issues from the cranial cavity along the anterior edge of the alisphenoid, through the lateral edge of the large orbital opening of the brain

case; the oculomotorius through a special foramen between the lateral wing of the basisphenoid and the adjoining edges of the alisphenoid and petrosal; and the truncus ciliaris profundi through the anterior opening of the trigemino-facial chamber, after having first perforated the cranial wall by a special foramen. The trochlearis of *Scomber* thus has the same relations to the alisphenoid that the trochlearis of *Amia* has. The oculomotorius of *Scomber,* lying between the edges of the bones that separate the orbital opening of the brain case from the orbital opening of the eye-muscle canal, has simply been caught between those bones as they, in their development, cut the single opening of *Amia* into the two or more parts found in *Scomber* and certain other teleosts (No. 5). The truncus ciliaris profundi of *Scomber* has been similarly caught in the region between the alisphenoid and petrosal, but has been somewhat displaced from the position it has in *Amia.* In embryos of *Amia,* where it alone was traced, the orbital extension of the jugular vein is connected, just as it leaves the orbit, by a short commissure with the vein described as the vein *vo.* Having entered the upper lateral chamber of the eye-muscle canal it traverses that chamber and issues posteriorly by the facial foramen. In *Scomber,* where the anterior extension of the jugular vein traverses the trigemino-facial chamber, no commissure connecting it with the apparent homologue of the vein *vo* could be found in the specimens examined, none of which however had been injected.

The trigemino-facial chamber of *Scomber* is thus seen to be the homologue of the upper lateral chamber of the eye-muscle canal of *Amia* in that it is traversed by the anterior extension of the jugular vein, and that from it the facial, trigeminal and profundus nerves have their ultimate exits from the skull. In other respects it differs greatly from the chamber of *Amia,* and, if any homology exists, it can certainly be the exact homologue of a small part only of that chamber.

In *Acanthias* embryos Sewertzoff (No. 69) describes an alisphenoid cartilage that is said to lie, in the earliest stage described by him, between the nervi facialis and trigeminus behind, and the nervi oculomotorius and opticus in front. The relation of the cartilage to the nervus trochlearis is not given. At a later stage,

represented by an embryo 47 mm. long, the facialis and trigeminus are said to have become separated from each other by an outgrowth of the ear capsule, and the oculomotorius and opticus to be enclosed, in separate foramina, between the coalesced edges of the alisphenoid and trabecular cartilages. That part of the trabecula that so forms the ventral half of the oculomotorius foramen is said to be formed by the hind end of the trabecula, and is said to represent the "so-called clinoid wall," that is, that part of the cartilaginous skull in which the basisphenoid of fishes is developed. The relations of the alisphenoid cartilage of *Acanthias* to the nervi trigeminus, oculomotorius, and opticus is thus exactly the same as that of the bony alisphenoid of *Scomber* to the corresponding nerves of that fish. The alisphenoid cartilage of *Acanthias* is, however, said to give insertion to the four recti muscles and the obliquus superior of the fish, and to have probably owed its development to this circumstance. This is certainly not true of the alisphenoid bones of either *Scomber* or *Amia,* whatever the cause of the development of the corresponding cartilages may have been. In *Amia,* in fact, it is the so-called basisphenoid that is developed in connection with the insertions of certain of the recti muscles (No. 5, p. 5).

The Squamosal (*SQ*) lies at the dorso-lateral corner of the hind end of the skull. It forms part of the lateral surface of the brain case, parts of the floors of the temporal and dilatator grooves, and a part of the ridge that separates those two grooves one from the other. It adjoins, anteriorly, the frontal bone and the postorbital ossification; antero-inferiorly the petrosal; postero-inferiorly the occipitale laterale; mesially the exoccipitale; and between the postorbital ossification and the exoccipitale it bounds, posteriorly, the temporal interspace of cartilage. The postero-inferior portion of its lateral surface is covered externally by the thin, scale-like intercalar, which bone covers also the entire lateral portion of the suture between the squamosal and the occipitale laterale, and part of that between the squamosal and petrosal. That part of the surface of the squamosal that is covered by the intercalar lies slightly depressed below the level of the adjoining portions of the bone, its limiting edge being, in most places, sharply marked and defined.

The squamosal consists, as already stated in an earlier work (No. 9), of two parts, an inferior portion, or body, and a superior portion which has the appearance of being a large, plate-like piece of bone applied to the dorsal surface of the body of the bone.

The body of the bone is thick and stout, and its edges are everywhere separated from the adjoining primary ossifications of the skull by lines of cartilage or tissue, excepting only where it is overlapped externally by the splint-like processes of the petrosal. It lies in an inclined position, inclining upward and laterally, approximately at 30° to a horizontal plane, and it may be said to have four exposed surfaces; one presented ventro-laterally, one dorso-laterally, one dorso-mesially and one posteriorly. The ventro-lateral surface forms the dorso-posterior portion of the side wall of the skull; the dorso-lateral surface forms a small part of the floor of the dilatator groove and bears on its mesial edge the superior, laminar portion of the bone; the dorso-mesial surface forms the lateral and larger portion of the posterior, depressed portion of the temporal groove; and the posterior surface, or hind end of the bone, forms the dorso-lateral part of the hind end of the skull. From its hind edge a long, thin, triangular process projects backward and laterally, its sharp, pointed, outer end forming the extreme dorso-lateral point or corner of the hind end of the skull.

The superior, laminar portion of the squamosal is a broad, flat piece of bone which has the appearance of being applied, somewhat crosswise, by the posterior half of its ventral edge, to the anterior half of the mesial portion of the dorso-lateral surface of the body of the bone. The plane in which the piece or process lies is directed forward and mesially, and it inclines upward and laterally at a considerable angle to the plane of the body of the bone. The process forms the posterior portion of the ridge that separates the temporal and dilatator grooves, and its anterior half projects horizontally, forward, and mesially beyond the anterior end of the body of the squamosal. The inferior edge of this projecting, anterior portion of the process is flattened, and the small ventral surface so formed rests upon the dorsal surface of the postorbital ossification, immediately mesial to the slight groove on that surface that forms the postero-mesial, depressed portion

of the dilatator groove. The mesial edge of this inferior surface of the process connects by suture with a part of the lateral edge of the parietal.

On the lateral surface of the body of the bone, close to its dorsal edge, there is a long, deep, oval facet, which gives articulation to the posterior of the two articular heads of the hyomandibular. This facet begins, posteriorly, at the base of the posterior process of the squamosal, and runs forward and slightly downward almost to the anterior edge of the body of the bone. The edge of the bone, immediately in front of and below the anterior end of the facet, is overlapped by the splint-like sutural processes of the petrosal, the points of the splints almost reaching to the edge of the facet. The axis of this facet inclines downward considerably less than the facet on the postorbital ossification.

The body of the squamosal is traversed by the external semicircular canal, which enters and leaves the bone on its thick inferior edge. This edge of the bone is united by suture or synchondrosis with the adjoining bones, and no part of it is exposed on the inner surface of the skull. Parts of it can, however, be seen, from the cerebral cavity, at the bottoms of the two openings, one of which leads into the anterior end of the external semicircular canal, and the other into the recess that lodges the sinus utriculi posterior.

The superior laminar process of the squamosal is traversed by the otic section, and by what Ewart (No. 24) calls the temporal section of the main infraorbital lateral canal, and it represents, as already stated in one of my earlier works (No. 9), that part of the bone that is developed in relation to that canal. The posterior process of the bone gives insertion to a ligamentous fascia that covers externally a part of the anterior surface of the first muscle segment of the trunk. It is developed in connection with that fascia, and represents a fibrous or membranous component of the bone. The body of the bone is of perichondrial or endochondrial origin, whichever it may be, and is undoubtedly developed in some relation to the external semi-circular canal. There are, thus, in the squamosal of *Scomber,* three separate components; a so-called primary one represented in the body of the bone, a dermal one represented in that part of the bone that encloses the lateral canal, and a fibrous or membranous one represented in its posterior process.

The Parietal (*PA*) is an irregular and somewhat oval bone, on the dorsal surface of which there is a tall, thin ridge. This ridge, which projects backward behind the body of the bone, forms the middle part of the bony ridge that separates the temporal and supratemporal grooves. The mesial edge of the bone overlaps slightly the lateral edge of the supraoccipital. Its anterior edge connects with the hind edge of the frontal, partly overlapping and being partly overlapped by it. Its lateral edge overlaps considerably, and lies upon, the dorsal surface of the postorbital ossification, connecting there with the mesial edge of one of the posterior processes of the frontal, and with the mesial edge of the anterior part of the dorsal process of the squamosal. The mesial part of its hind edge overlaps and rests upon the exoccipitale. The lateral part of its hind edge turns downward over the ledge that separates the anterior and posterior portions of the temporal groove, and there overlaps, in part by delicate processes, the squamosal, the exoccipitale, and the small temporal interspace of cartilage. The body of the parietal rests upon cartilage in a small part only of its extent, the larger part of the ventral surface of the bone taking direct part in the formation of the roof of the cranial cavity.

The Exoccipitale (*EO*) is a somewhat conical bone, the point of which forms a pronounced process on the dorsal edge of the hind end of the skull, lying about midway between the posterior process of the squamosal and the spina occipitalis. The bone has dorsal, lateral and posterior surfaces, the dorsal surface being separated from the other two by sharp edges, and the other two separated from each other by a strong rounded edge. The bone adjoins the supraoccipital mesially and antero-mesially, the squamosal ventro-laterally, and the occipitale laterale ventro-posteriorly. The mesial edge of its posterior surface almost touches the corresponding edge of the bone of the opposite side of the head, the adjoining edges of the two bones there being overlapped, externally, by the postero-inferior portion of the supraoccipital. The anterior corner of the bone bounds the posterior edge of the temporal interspace of cartilage, and is overlapped, for about one third the length of the bone, by the hind end of the parietal.

The dorso-posterior point or summit of the exoccipitale is directed dorsally, laterally and posteriorly, and is prolonged into a

short, flat process which projects laterally and backward, its flat surface being presented upward and slightly backward. This flat surface is continued forward and mesially along the dorsal surface of the bone, close to its dorso-posterior edge, and extends beyond the exoccipitale on to the adjoining portion of the supra-occipital. It gives support to the long, antero-mesial process of the suprascapular, that process having a sliding motion upon it. At about the middle of the hind edge of this flat surface there is, on the exoccipitale, a slight, irregular eminence which gives origin to a short round ligament which is inserted on the under surface of the suprascapular. Beginning at the base of the short, flat, posterior process above described, and continuous with it, a thin, laminar process, or ridge, runs forward and slightly mesially along the dorso-lateral edge of the exoccipitale, and slightly overlaps, laterally, the corresponding ridge on the dorsal surface of the parietal. It projects dorso-laterally and forms the hind end of the ridge that separates the temporal and supratemporal grooves.

The lateral face of the exoccipitale forms the mesial wall of the posterior portion of the temporal groove, and is deeply hollowed out by that groove. The posterior face of the bone, has, on its mesial half, a depressed region, which is often sharply marked off from the rest of the bone by a rounded edge, or slight ridge, which runs upward, forward and slightly laterally.

The internal surface of the bone is concave. On the internal portion of its inferior edge there is a semicircular indentation which forms the dorsal half of the circular opening of a recess of the cranial cavity. This recess is directed backward and laterally, is greatly enlarged at its distal end, and there lies between the thick, inferior edge of the exoccipitale, and the adjoining part of the occipitale laterale. The recess lodges the hind end of the sinus utriculi posterior, and from its enlarged distal end the external and posterior semicircular canals take their origins. The external canal runs laterally, forward and slightly upward, passing at once into the canal already described in the squamosal. The posterior canal runs upward and mesially, and then forward, in the exoccipitale, and reënters the cranial cavity by a large opening near the dorsal edge of the cerebral surface of the exoccipitale. A groove on the cerebral surface of the skull,

at first on the internal surface of the exoccipitale, then between that bone and the supraoccipital, then on the temporal interspace of cartilage, and finally on the cerebral surface of the petrosal marks the further course of this canal, and also, beyond it, that of the anterior semicircular canal.

The Supraoccipital (*SO*) forms the median portion of the hind end of the dorsal surface of the skull and the dorso-median portion of its posterior surface; its two portions, one dorso-superior and the other postero-inferior, lying at an angle of about 135° to each other.

The dorsal portion of the bone is convex on it outer surface, which forms part of the dorsal surface of the skull, and concave on its inner surface, which forms part of the roof of the cerebral cavity. The posterior half of this part of the bone is somewhat semicircular in outline, and is considerably wider than the anterior half, from which it is separated by sharp reëntrant angles. The lateral edge of each of the processes formed by these reëntrant angles bounds the mesial edge of the anterior portion of the corresponding temporal interspace of cartilage. The anterior half of the dorsal surface of the bone usually has three separate edges, the anterior one of which is transverse in position and nearly straight, and bounds the hind end of the median, post-epiphysial interspace of cartilage. Postero-mesial to the hind end of the temporal interspace of cartilage the supraoccipital adjoins, on either side, the antero-mesial edge of the exoccipitale, from which it is separated by a line of cartilage. Between the temporal and post-epiphysial cartilaginous interspaces the lateral edge of the supraoccipital, on each side, is free, being separated from the mesial edge of the postorbital ossification by a large opening in the roof of the primordial cranium. This opening, or fontanelle, extends forward almost to the anterior end of the alisphenoid, its anterior portion lying between the alisphenoid, laterally, and the post-epiphysial interspace of cartilage, mesially. The anterior portion of the fontanelle is covered externally by the hind end of the frontal, the posterior portion being similarly covered by the parietal; the edges of those two bones both overlapping externally the dorsal surface of the supraoccipital.

The postero-inferior portion of the supraoccipital is narrow, and is pointed at its lower end. It lies in the middle line of the posterior surface of the skull, and overlaps externally the adjoining edges of the exoccipitalia and occipitalia lateralia.

Along the middle line of the dorsal portion of the bone there is a strong, longitudinal ridge, which separates the supratemporal groove of one side of the head from that of the other side. This ridge is continued downward along the middle line of the posterior portion of the supraoccipital, and the entire ridge, so formed, is produced posteriorly into a long, thin, spina occipitalis. This spina is usually triangular in lateral outline, and its dorsal edge, which lies in the general level of the dorsal surface of the skull and head, ends in a sharp point directed backward and upward.

The supraoccipital takes no part whatever in the formation of the enclosed portions of the bony semicircular canals, but that part of the edge of its dorsal portion that adjoins the exoccipitale, forms, on the inside of the skull, a part of the mesial wall of the cerebral groove that lodges the unenclosed portion of the posterior membranous semi-circular canal, and, in front of the dorsal end of that canal, the anterior membranous canal.

The Basioccipital (*BO*) is about twice as long as it is wide and thick. Its hind end is solid and vertebra-like in shape, and of somewhat greater diameter than that part of the bone that lies immediately in front of it. The dorsal surface of this vertebra-like hind end of the bone is much longer than its ventral surface, the latter being reduced to little more than a narrow transverse edge. Its posterior surface, which is also the posterior surface of the basioccipital itself, is entirely occupied by a deep conical depression, a narrow outer edge of the hind end of the bone alone remaining. The depth of the depression, in some specimens, almost equals its diameter. A similar depression is found on the anterior end of the first vertebra, the two depressions enclosing a large bi-conical space, which is filled with a soft and somewhat gelatinous mass.

Immediately in front of its solid, vertebra-like hind end the basioccipital is contracted laterally and dorsally, but not ventrally. It then expands gradually to its anterior end, which is somewhat larger in diameter than its solid hind end. This part of the bone

is deeply hollowed out, throughout its entire length, by the posterior portion of the eye-muscle canal, the hind end of which lies at the level of the ventral surface of the basioccipital, and not at the level of the center of the vertebral column. The ventral surface of the basioccipital is cut away in the middle line, throughout its entire length, by a wide rectangular opening, which extends backward to the narrow, ventral edge of the solid vertebra-like hind end of the bone, and forms the posterior portion of the hypophysial fenestra (*hfn,* Fig. 25). The ventral edges of the basioccipital, at each side of the fenestra, are thin, and are overlapped externally by the lateral edges of the hind end of the parasphenoid, the latter bone entirely closing the fenestra.

The anterior edge of the basioccipital presents three splint-like processes, a dorso-median one and two lateral ones, the dorso-median one being much the stronger of the three. All three processes adjoin, or connect suturally with, the hind ends of the petrosals, the median process overlapping dorsally the adjoining, mesial edges of the mesial, horizontal wings of the petrosals, and the lateral ones each overlapping externally the ventral part of the petrosal of its side. Between the median process and each lateral process, on the dorsal, cerebral surface of the basioccipital, a deep groove begins, and extends from the front edge of the body of the bone backward through about one half its length. The two grooves lie so near the lateral edges of the dorsal surface of the element that only a thin ridge of bone is left, on each side, to form their lateral boundaries. Each groove forms the hind end of the saccular recess (*scr,* Fig. 24) of its side of the cranial cavity, the anterior end of the recess lying, as already described, on the cerebral surface of the petrosal.

Between the hind ends of the saccular grooves, beginning at about the middle of that part of the groove that lies in the basioccipital, there is, on the dorsal surface of the latter bone a slight groove. At about the level of the hind ends of the saccular grooves, this median groove becomes a short, median canal, or pit, extending backward and slightly downward into the bone, and ending blindly (Fig. 8). In longitudinal sections cut through this part of the bone a line is seen, which continues the line of the canal backward and downward to the dorsal surface of the conical,

vertebral depression in the hind end of the bone, reaching that surface slightly dorso-posterior to the bottom of the depression. This line was not examined microscopically. Macroscopically it has the same general appearance as the lines that form the axes of the vertebræ and connect the depressions on their opposite faces. It seems to indicate that the anterior end of the chorda here turned upward, or was pushed upward, above the hind end of the eye-muscle canal; and the canal or pit in the basioccipital looks as if it might be the remnant of the anterior, conical depression of a vertebral body, the posterior depression of which was represented in the depression on the hind end of the basioccipital.

The basioccipital supports, on each side of its dorsal surface, the occipitale laterale of the corresponding side of the head. The anterior part of the latter bone, on each side, rests upon the thin ridge that forms the lateral boundary of the saccular groove. Its posterior portion rests upon an inclined surface on the dorsal surface of the basioccipital, and the lower, lateral edge of this little surface projects as a slight process or ridge on the lateral surface of the solid, vertebra-like hind end of the bone. The little surface looks dorsally, anteriorly and laterally, and between the two surfaces of opposite sides of the head there is a small, flattened, median surface, which forms the floor of the foramen magnum. The posterior part of this median surface is wide. The anterior part may be reduced to a narrow line or even entirely disappear, the two occipitalia lateralia then here covering the entire dorsal surface of the basioccipital.

At the extreme postero-ventral end of the lateral surface of the basioccipital there is a slight, but well-marked depression which marks the surface of origin of a ligament that runs outward and backward and is inserted on the inner surface of the supraclavicular.

The Occipitale Laterale (*OL*) adjoins the petrosal anteriorly, the squamosal dorso-antero-laterally, and the exoccipitale dorsally. The dorsal part of its lateral surface is covered by the intercalar. The dorsal part of its mesial edge adjoins its fellow of the opposite side of the head, the adjoining edges of the two bones being covered externally by the lower end of the postero-inferior portion of the supraoccipital. The edge of the bone is

here thick and articulates dorsally with a correspondingly thickened part of the exoccipitale. The edges of both bones are hollowed out, and enclose, with the bones of the opposite side of the head, a median nodule of cartilage (Fig. 8).

The outer surface of the occipitale laterale presents three portions lying in planes nearly at right angles one to the other. The anterior portion is presented ventro-laterally, the middle one dorso-posteriorly, and the posterior one dorso-laterally. These three surfaces are not well shown in the figures, but will be readily understood by comparing Figs. 7 and 10. Fig. 7 shows the anterior and posterior surfaces, Fig. 10 the middle one, this last surface wrongly appearing in Fig. 7 as the posterior edge of a slight ridge. The ventro-lateral surface is flat and triangular in shape. Its ventral edge is nearly horizontal in position, and the bone is here thin in front and thick behind. The thin anterior portion rests upon the thin lateral edge of the saccular groove on the dorsal surface of the basioccipital, and forms the dorsal part of the lateral bounding wall of the groove. The thick posterior portion rests upon the small, inclined and slightly raised surface on the solid hind end of the basioccipital. From the anterior end of the mesial edge of this posterior portion a delicate spine-like process runs directly forward, and, resting upon the dorsal surface of the basioccipital, forms a small part of the mesial wall of the hind end of the saccular groove. The central part of the inferior surface of the thick hind end of the bone seems to be partly cartilage, as if the ossification of the bone were not complete. This condition is still more marked on two thickened portions of the anterior edge of the bone, the bone in all these places presenting somewhat the appearance described by Vrolik as perichondrosteal (No. 76, p. 237).

The anterior edge of the ventro-lateral surface of the bone is slightly convex, the centre of the circle being approximately the vagus foramen; that foramen lying slightly in front of the ventro-posterior corner of the surface, and at about the middle of the total length of the bone. Along the dorso-posterior edge of this foramen there is a short, sharp ridge, and the foramen itself is sometimes separated into two parts by a thin bony partition. A little in front of, and usually slightly below the vagus foramen is

the small foramen for the glossopharyngeus, the cerebral opening of which always lies in the lateral surface of the saccular groove. In front of and above these two foramina, and occupying a large part of the anterior edge of the lateral surface of the bone, is the sharply defined and slightly depressed region that lodges the overlapping intercalar. The lower edge of the latter bone is, in turn, overlapped externally by a thin, but relatively long and broad, splint-like process of the occipitale laterale.

The dorso-posterior surface of the bone lies nearly at right angles to the ventro-lateral surface, the two being separated by the strong, postero-lateral edge of the bone and skull. The surface is traversed, at about its mesial third, by a ridge, which runs upward, forward, and slightly laterally, and separates the surface into two regions, a lateral and a mesial one. This ridge rises but little above the outer level of the lateral portion of the surface, but lies considerably above the level of the mesial portion, the latter portion forming, accordingly, a depressed region, or groove, which is continuous with the groove already described on the posterior surface of the exoccipitale. The ridge marks the position of the posterior semicircular canal of the ear.

The dorso-lateral surface of the bone is continuous with the mesial edge of the dorso-posterior surface, and lies approximately at right angles to it. It is slightly convex, and that part of the bone that forms its dorsal half is simply a thin shell which arches over the anterior, intracranial end of the spinal cord, and forms, with its hind edge, the dorsal and lateral boundaries of the foramen magnum. The ventral edge of this part of the bone, lateral to and below the foramen magnum, is thickened, looks postero-ventrally, and rests upon the basioccipital, as already described. At the upper end of this thickened portion, at about the middle of the hind edge of the bone, and at the level of the dorsal surface of the vertebral column, there is a long, oval articular facet, which occupies the ventro-postero-lateral surface of a slight condylar eminence. The long axis of the facet inclines downward, forward and laterally, and the facet itself, which is presented ventrally and postero-laterally, articulates with a corresponding surface on an anterior process of the first vertebra. It is covered with a thin layer of tissue which is, to all appearance, fibro-cartilage. Dorso-

anterior to this articular facet there is a small ridge of bone, usually ending posteriorly in a sharp process. The ridge projects downward, backward and laterally, and slightly overhangs a slight groove in which lie from two to five small foramina. These foramina, which transmit the roots of the three occipital nerves, have already been referred to in one of my earlier works (No. 6) and will be again referred to in describing the occipital nerves. The posterior process of the ridge gives insertion to the third intermuscular septum of the trunk muscle. A slight process often found near the anterior edge of the ridge gives insertion to the second intermuscular septum. These processes are, so far as can be judged from their general appearance, simply membranous formations developed in connection with the septa to which they give insertion. Nothing, excepting the fact that they give attachment to intermuscular septa, indicates, in any way, that they are the homologues of the two occipital arches of *Amia*. On the contrary, they seem, in every respect, to replace or mark, in *Scomber*, those eminences on the cartilaginous occipitale laterale of larvæ of *Amia*, which, in that fish, were said by me (No. 4, pp. 725–727) to mark, as they do also in *Scomber*, the lines of insertion of the second and third intermuscular septa.

The anterior edge of the occipitale laterale is irregular in outline. In certain places it is thick, in others thin, being, in the latter places, cut away by the recess for the hind end of the sinus utriculi posterior, and by those ends of the external and posterior semicircular canals that take their origins from that sinus. The recess for the sinus utriculi lies immediately dorso-anterior to the vagus foramen, and is separated from that foramen by only a thin plate of bone. The hind end of the external semicircular canal cuts into that thick edge of the occipitale laterale that separates its ventro-lateral and dorso-posterior surfaces. The ventral end of the posterior semicircular canal lies directly internal to the ridge that separates the dorso-posterior surface of the bone into two parts or regions. The thick parts of the edge of the bone are somewhat cartilaginous in their central portions, the mesial end of the anterior edge of the bone enclosing, with the adjoining bones, a distinct nodule of cartilage.

The Intercalar (*IC*) is a thin, scale-like bone of irregular and variable shape. Its hind edge, which is its thickest portion, is usually straight or slightly concave, and has, at about the middle of its length, a more or less pronounced eminence, which gives articulation to the lower end of the leg of the suprascapular. From the base of this process a more or less pronounced ridge runs forward across the outer surface of the bone, and marks the upper limit of the surface of insertion of certain of the levator muscles of the branchial arches. The bone lies upon the lateral surface of the adjoining portions of the squamosal, petrosal and occipitale laterale, fits into slightly depressed regions on those bones, and a part of its outer edge fits under thin, laminar, splint-like processes of the petrosal and occipitale laterale, as already stated in describing those bones. The intercalar extends posteriorly, in its middle portion, beyond the adjoining hind edges of the squamosal and occipitale laterale, and so has a small, somewhat crescent-shaped surface presented dorso-mesially. It takes no part whatever in the formation of any of the semicircular canals.

The intercalar of *Scomber* is thus, to all appearance, simply a membrane bone, as it is in *Amia* (No. 4, p. 688). It accordingly offers no support whatever to Sagemehl's statements regarding the primary character of the bone in other teleosts (No. 65, p. 45), but supports, on the contrary, in every particular, Vrolik's earlier statements and conclusions regarding it (No. 76, p. 285). That the bone, in *Scomber,* can have, or can have had, any primary relation whatever to any part of the ear capsule seems even more improbable than in *Amia.*

The Extrascapular (*ESC,* Fig. 5) is a delicate, slender, Y-shaped bone lying in the deeper layers of the skin on the dorsal surface of the posterior portion of that anterior extension of the trunk muscles that fills the temporal groove. The shank of the Y-shaped bone is directed backward, and overlaps the antero-lateral edge of the suprascapular at about the middle of the total length of that bone. The shank and lateral arm of the Y form a nearly straight line, which runs almost directly forward and ends immediately behind the enlarged hind end of the dorsal ridge of the squamosal. The mesial arm of the Y runs forward and mesially, superficial to one or two anterior, splint-like processes

of the suprascapular, and almost reaches the outer edge of that dorsal ridge of the skull that separates the temporal and supratemporal grooves. The bone is thus limited, in position, to that part of the dorsal surface of the head that lies directly superficial to, or superficial and posterior to, the hind end of the temporal groove. The shank and lateral arm of the bone are traversed, their full length, by the main infraorbital lateral canal; the mesial arm being traversed by the supratemporal branch of the same canal. The bone is developed in relation to the canals by which it is traversed, and is imperfectly or incompletely formed, the openings on its dorsal surface being more numerous than the primary tubes that lead outward from the enclosed canals.

The Suprascapular (*SS*, Fig. 5) is an irregular bone lying immediately behind and partly internal to the extrascapular. It consists of a relatively large, flat and stout, scale-like body, a strong antero-mesial process, and a strong inferior process, or pedicle. It lies, in general direction, obliquely to the body, extending forward, upward and mesially from its hind end. Its hind end overlaps the supraclavicular, while its anterior end is overlapped by the shank and mesial arm of the extrascapular.

The body of the bone lies in the dermal tissues superficial to the trunk muscles. Posteriorly it ends in a delicate scale-like edge, and anteriorly there arise from it two splint-like processes which project forward and slightly downward in the temporal groove. These two processes are often fused for a considerable distance from their bases, a single process with two pointed ends being thus formed. These ends may extend forward to the point where the temporal groove is crossed by the ledge that separates it into its two portions or levels, but they do not usually quite reach that point. The posterior two thirds or three quarters of the body of the bone is traversed by the posttemporal part of the main infraorbital lateral canal.

The antero-mesial process of the bone arises from the ventral surface of the mesial edge of the anterior half of the body of the bone, and runs horizontally forward and mesially across the dorso-posterior process of the exoccipitale, its anterior end almost reaching the base of the spina occipitalis. This process of the bone thus lies partly superficial to the temporal groove, near its hind end,

and partly superficial to the supratemporal groove. As it crosses the exoccipitale it is bound by ligament to it, as already described in describing that bone.

The leg or pedicle of the suprascapular arise from the ventral surface of the body of the bone, at the hind end of the antero-mesial process, with which process, on the ventral surface of the bone, it forms a large strong V. It is broad at its base, runs downward and almost directly forward, tapers gradually to a blunt end, and rests upon and is attached by ligament to the posterior process of the intercalar. The lateral corner of its base forms a short process directed laterally and downward, and the anterior end of the supraclavicular fits in, and is held between, the dorsal edge of this process and the internal surface of the body of the bone.

The two anterior, splint-like processes of the body of the bone plunge slightly into the muscle-mass that fills the temporal groove, the two processes lying in the lateral and mesial ones of three septal lines that separate the muscles, that fill the groove, into four superficial parts. These two septa are longitudinal in direction and both belong, as will be later shown, to the first intermuscular septum of the trunk muscles of the fish.

The antero-mesial process of the bone lies dorsal to the muscles that fill the temporal groove, but it passes into the trunk muscles as it reaches the line between the temporal and supratemporal grooves, and lies ventral to the muscles that fill the latter groove. It here penetrates the trunk muscles, as will be later shown, at the dorsal edge of the first intermuscular septum, at the point where that septum and the second septum are both attached to the hind end of the skull. The second septum is continued forward, along the bottom of the supratemporal groove, dorsal to the process, and there is also an anterior pocket of the third septum that lies dorsal to it in the same groove.

The antero-ventral process, or leg, of the suprascapular lies in the first intermuscular septum, and is attached, with that septum, to the hind end of the intercalar.

The four processes of the suprascapular thus seem to have been developed in some relation to the first intermuscular septum of the muscles of the trunk; and parts of the second and third septa seem to have been pushed or pulled forward dorsal to the antero-

mesial process of the bone after that process had been so developed. As the hind edge of the body of the bone lies approximately in the line of the superficial edge of the second septum, the bone thus only covers, approximately, one muscle segment, the second segment of the trunk.

The Supraclavicular has the general shape shown in Fig. 27, but it is often much more diamond-shaped than there shown. The antero-ventral half of the diamond is always considerably narrower and thicker than the dorso-posterior half, and a strong ridge crosses the bone from angle to angle between the two portions. The postero-ventral half of the bone lies superficial to, and is bound by fibrous or ligamentous tissue to, the dorsal end of the clavicle. The bone ends postero-ventrally in a sharp point, which, when in position, lies slightly dorsal to an eminence on the antero-lateral edge of the clavicle. The antero-dorsal end of the bone is usually blunt, but may have a short process directed somewhat forward. The dorsal third or half of the bone is overlapped externally by the hind end of the suprascapular, the anterior edge of the supraclavicular fitting into the space between the internal surface of the body of the suprascapular and the short process that projects laterally and ventrally from the base of the leg of that bone.

On the inner surface of the posterior half of the supraclavicular, immediately dorsal to the dorsal edge of the clavicle, and sometimes also partly on the latter bone, a large ligament coming from the hind end of the lateral surface of the basioccipital has its insertion. This ligament, at its distal end, usually separates into three parts, one of which turns upward and one downward immediately posterior to the thickened central part of the supraclavicular, the third one running backward toward the posterior corner of the bone. The bone is traversed, near its dorso-posterior edge, by the hind end of the main infraorbital lateral canal.

The Infraorbital Chain of bones is a series of thin and delicate bones, usually ten or twelve in number. The anterior bone of the series is much larger and stouter than the others, and corresponds, in general position, to the lachrymal of other fishes. The hind edges of all the bones, the lachrymal included, overlap, or are overlapped by, the anterior edges of numerous scale-like

bones that cover the cheek of the fish. Posterior to the middle part of the postorbital part of the infraorbital series these scale-like bones are firmly bound to each other and to the infraorbital bones by fibrous tissue, and so form a sort of bony armor covering the cheek. Posterior to the dorsal and ventral parts of the postorbital series they are less firmly connected with each other and look like ordinary scales, although they are much larger and stouter than the scales on the trunk of the fish. Posteriorly these scales or scale-like bones extend backward beyond the anterior edge of the preoperculum onto the outer surface of the operculum, becoming gradually smaller and more delicate.

The orbital edges of the infraorbital bones all turn inward. Immediately distal to this turned-in portion they are all traversed by the circumorbital part of the main infraorbital lateral canal. One of the bones of the series, usually the second or fourth from the dorso-posterior end of the chain, does not usually reach the edge of the orbit, being excluded from it by the adjoining edges of the two bones between which it lies.

The dorso-posterior bone of the series is somewhat larger and stouter than the bones that immediately adjoin it, and seems, unquestionably, the homologue of the postfrontal bone of *Amia*. It lies partly superficial to the anterior end of the dilatator operculi muscle; and partly superficial to the dorsal end of the levator arcus palatini. Its dorsal edge lies superficial to the lateral edge of the dilatator groove, and is nearly parallel to, but separated by a considerable space from, the dorsal edge of the ridge of bone that separates the dilatator groove from the temporal groove. The antero-dorsal corner of the bone reaches almost to the anterior end of the dilatator groove; and the orbital edge of the bone, which is presented ventro-anteriorly, rests upon the orbital edges of the frontal bone and the postorbital ossification.

Ventral to the postfrontal bone, between it and the lachrymal, lie the postorbital and suborbital bones of the fish. The four or five most dorsal ones are relatively slender bones, often with pointed posterior ends. The next bone, the sixth or seventh from the dorsal end of the series, is, after the lachrymal, the largest bone of the series. It lies directly behind the eye and has an irregularly rounded hind edge, which, in large fishes, extends

backward beyond the anterior edge of the preoperculum, overlapping that bone externally to a greater or less extent. The second bone distal to this large bone is the second one posterior to the lachrymal. It is always much more convex externally than any of the other bones of the series, and seems to mark a definite place in the infraorbital chain. Just what its significance is I am unable to determine, but it seems to hold a certain definite relation to a part of the infraorbital lateral canal and will be again referred to in describing that canal. Its dorsal edge simply touches and is bound to the edge of the adjoining bone, the adjoining edges of the other, more dorsal bones of the series being similarly related to each other. Its ventral edge, on the contrary, is overlapped by the dorsal edge of the bone next distal to it and that bone has a slight sliding motion upon it. The latter bone is, in turn, overlapped by the dorso-posterior corner of the lachrymal, and so bound to that bone that a slight turning, rather than sliding motion is possible between them. This bone, the first one posterior to the lachrymal, I have considered as a suborbital bone, the other bones of the series being considered as postorbital.

The Lachrymal (*LA*) is a large four-sided bone, directed forward and upward. The anterior end of the bone is considerably wider than the posterior end, and the antero-ventral edge considerably longer than the dorso-posterior edge. Immediately behind the antero-dorsal corner of the bone there is, in its dorso-posterior edge, a semicircular indentation, the edges of which are thickened so as to form an articular surface. It articulates with the antero-ventral surface of the outer end of the palatal process of the preorbital ossification, and is firmly bound to that process by fibrous tissues. The anterior end of the bone extends forward ventral to the curved, anterior end of the palatine, and is attached by fibrous or ligamentous tissues to the anterior end of the maxillary, the attachment being mainly to that short process of the maxillary that overlaps externally the premaxillary and serves for the insertion also of the ligaments that arise from the ethmoid and nasal bones. Where the lachrymal passes ventral to the head of the palatine it is often slightly cut out so as to fit against that bone. The lower edge of the bone is thin, like the outer edges of all the infraorbital bones, and extends ventrally slightly beyond the ven-

tral edges of the maxillary and premaxillary bones, so that these bones are completely covered and hidden from view by the lachrymal, excepting only at their anterior ends. As a result of its connection with the maxillary and premaxillary bones, the lachrymal has, when the mouth is opened or shut, an oscillating motion around its articular facet as a centre, its motion being in an opposite direction to that of the two bones to which it is attached. This motion is communicated in part to the first post-lachrymal bone, but not to the second, the sliding joint between that bone and the first post-lachrymal one preventing a transmission of the motion. The lachrymal is traversed by the sub- and antorbital parts of the main infraorbital lateral canal, the canal ending near the antero-dorsal edge of the bone, somewhat in front of the articular facet.

2. Vertebræ.

The First Six Vertebræ of *Scomber* increase slightly in size and length from the first to the last. They are all strongly biconcave, and about once and a half as long as wide. The ventral half of each vertebra (Fig. 26) has a smooth lateral surface, without process of any kind, and has the ordinary hour-glass shape. The dorsal half is irregular, due to the fusion of the dorsal arch with the body of the vertebra. On the dorsal surface of the body of the vertebra there is a large median depression, the middle and deepest point of which reaches almost to the center of the vertebra, the vertebra having accordingly, in median vertical sections, a decidedly hour-glass shape. From the sides of the median dorsal depression the dorsal arches arise, each arch consisting of a slender spine, on both sides of the base of which there is a broad, thin and delicate web of bone. The spine on the first vertebra is much shorter than those on the others. The base of each spine is thickened and broadened, and forms, on the outer surface of the webbed part of its arch, a strong projecting ridge. The web, on each side of this ridge, extends the full length of the vertebra, and arches upward and mesially, to form, with the web of the opposite side, the sides and top of the spinal canal. At the anterior and posterior ends of the vertebra delicate spicules of bone may unite the webs of opposite sides across the mid-dorsal

line. The middle portions of the webs, especially those portions that lie immediately in front of the spines, are not so united, being always separated by a wide open space. The spine-like portions of the arches of opposite sides are not connected with each other at the level of the dorsal surface of the spinal canal. Somewhat above that canal they fuse to form a single median spine, which extends upward and backward, curving slightly, and ending in a sharp point. The spines incline backward, progressively more and more strongly from the first to the sixth vertebra.

Posterior to the base of the spine of each vertebra the webbed part of the arch is pierced by one or two foramina, which transmit the roots of the associated spinal nerve. These foramina, on the posterior vertebræ examined, lie immediately posterior to the base of the spine of their vertebræ, while on the anterior vertebræ, excepting only the first vertebra, they lie slightly distant from it. The ventral foramen on the first vertebra lies in the base of the spine, itself, that base on this vertebra spreading much more than on the posterior ones. Ordinarily there are two foramina in each vertebra, one for the dorsal root of the spinal nerve that innervates the muscle segment that lies between the vertebra in question and the next posterior one, and the other for the ventral root of the same nerve.

On the anterior edge of the first vertebra there is a large, strong process, directed forward, or forward and slightly upward. It arises from that part of the edge of the vertebra that lies between the mid-lateral line of the body of the vertebra and the lateral edge of the spinal canal. Its mesial edge is strongly bevelled, a broad surface being formed which looks mesially, forward and slightly upward. It is lined with what seems to be fibro-cartilage and it articulates with the long, oval articular surface on the hind end of the occipitale laterale. On each of the other vertebræ a corresponding process is also found, but it is less strongly developed and lies more dorsally on its vertebra. It overlaps externally the dorso-lateral surface of the next preceding vertebra, and articulates both with that surface and with the dorsal edge of a posterior process of the same vertebra. This latter process arises from the hind edge of the vertebra concerned, is a small, somewhat pointed process directed backward and laterally, and fits into or

against a slight depression on the anterior edge of the next posterior vertebra, immediately ventral to the anterior process of that vertebra.

On the lateral surface of the first vertebra, immediately posterior to the anterior edge of the spreading base of the spine-like portion of its dorsal arch, there is a deep depression, which receives and gives articulation to the proximal end of the associated horizontal rib. The foramen for the ventral root of the associated spinal nerve lies immediately posterior to this depression, in another, smaller but often even deeper depression. On the second vertebra the depression that lodges the articular end of the associated horizontal rib lies in the spreading base of the spine of the arch, the foramen for the ventral root of the associated nerve lying in a depression immediately posterior to the base of the spine. The next four vertebræ resemble the second excepting that there is, immediately anterior to the depression at the base of the spine of each vertebra, a second, but only slightly marked, depression. On all of these latter vertebræ the large depression lodges the proximal end of the ventral rib of the vertebra, and not that of the horizontal one, as it does on the first two vertebræ. The small anterior depression lodges the articular end of the horizontal rib.

On the first and second vertebræ there were, in all the specimens examined excepting one, but a single rib, the horizontal rib, on each side. The articular ends of these ribs are enlarged, and each fits into and fills the articular depression on the vertebra with which it articulates. On all the other vertebræ examined there were two ribs on each side, a horizontal one and a ventral one. The articular end of the ventral rib was enlarged and articulated with its vertebra in the large posterior articular depression. The articular end of the horizontal rib was reduced to a flat line and articulated with the vertebra in the shallow, anterior articular depression. The flat articular end of the horizontal rib, on these vertebræ, lies against the anterior surface of the corresponding ventral rib, the articular ends of the horizontal ribs on the posterior vertebræ lying relatively more ventral than on the anterior ones. On the second vertebra of one specimen there was a short ventral rib on each side, the rib being only one third or one quarter as long as the next following ventral rib.

The ventral ribs lie wholly in the lining membranes of the inner surface of the body wall, opposite the mesial edges of the associated intermuscular septa; the rib that is associated with the third vertebra lying opposite the sixth septum. The horizontal ribs lie in the intermuscular septa at the points where those septa cross the horizontal muscle septum, the first or most anterior rib lying in the fourth septum.

Associated with each of the ventral ribs there is a triangular ligament which lies in and fills the obtuse angle formed between the anterior edge of the basal portion of the rib and a horizontal line on the adjoining anterior part of the lateral surface of the vertebra. The ligament is horizontal in position, lies ventral to the horizontal rib, and extends to the anterior edge of its vertebra. Associated with the horizontal rib there is a similar but smaller ligament, lying vertically instead of horizontally, and extending from the dorsal surface of the rib, near its base, to the lower portion of the spine-like part of the dorsal arch of the vertebra.

In *Scomber* there is no slightest external trace, either on the vertebræ or on the ventral surface of the occipital part of the skull, of the ventral cartilaginous processes found in *Amia*.

The first two horizontal ribs, in *Scomber*, seem to be, as will be later shown, the serial homologues of the occipito-supraclavicular ligament of the fish. In *Amia* the corresponding ligaments seemed to be the serial homologues of the single ribs of that fish. If therefore the first two ribs of *Scomber*, which have the vertebral articular relations of ventral ones, are the serial homologues of the horizontal ribs of the fish, as their position indicates, the horizontal ribs of *Scomber*, and not the ventral ones, may be the homologues of the single ribs of *Amia*. Neither the horizontal nor the ventral ribs were examined in section, and one or the other of them may be simply "Fleischgräten." The position of the horizontal ribs seems to indicate, conclusively, that they are the homologues of the "Seitengräten" of *Monacanthus*, and hence, according to Goette and Goeppert (No. 30, p. 162), the homologues of the upper ribs of the Crossopterygii and Selachii. If they be such, *Scomber* closely resembles *Polypterus* and *Calamoichthys* excepting only in the total absence, on the vertebræ examined, of associated supporting basal processes. And if the

ribs of *Amia* be true upper ribs, as I was led to suggest in an earlier work (No. 4, p. 715), the horizontal ribs of *Scomber* would naturally be the homologues of the ribs of that fish, as their serial relations to the occipito-supraclavicular ligament indicate. In *Monacanthus,* Goeppert says there are no ventral ribs (Pleuralbögen), that fish differing radically in this from *Scomber.*

3. The Visceral Arches.

1. Gill Filaments.

Scomber has four branchial arches, each with a double row of gill filaments, a fifth incomplete arch, without gill filaments, and an opercular demibranch.

The opercular demibranch lies near the dorsal end of the inner surface of the gill cover, partly on that cover and partly superficial to the thick hind edge of the adductor hyomandibularis muscle. The anterior end of its ventral edge lies immediately above the proximal and dorsal end of the infrapharyngobranchial of the first arch. From there the ventral edge of the gill extends at first outward and backward slightly dorsal to the ventral edge of the wide posterior surface of the adductor hyomandibularis, and then, beyond that muscle, upward and backward along the inner surface of the operculum. From this curved ventral line the filaments of the demibranch extend upward and slightly backward, being longest in their middle portion and thus giving to the whole structure a somewhat oval form. The demibranch covers almost completely the thick, posterior surface of the adductor hyomandibularis, and, beyond that muscle, a part of the inner surface of the operculum. It is attached (Fig. 39) to the mucous membranes that cover the muscle and the operculum, the surface of attachment being so wide that the ventral halves, approximately, of the filaments are included in it. The dorsal halves of the filaments are thus the only parts left free, the demibranch resembling, in this, but not in its surface of attachment, the demibranch of *Salmo salar* (No. 45, p. 243).

The gill filaments of the demibranch, and also those on all the branchial arches, all contain a central, bony, supporting ray. These rays (Fig. 44) are V-shaped at their proximal ends, the V

being placed longitudinally in the gill, and hence transversely to the width of the filament. On the four branchial arches there are two rows of these rays, corresponding to the two rows of filaments, the V-shaped ends of the rays of each row resting longitudinally upon the corresponding edge of the related bony element of the arch. Distal to its V-shaped end each gill ray is formed of a median cylindrical portion, or shaft, bordered on each side, for some distance from its base, by a thinner, flattened portion, the distal edge of which is approximately parallel to the corresponding part of the V at its proximal end. Each ray thus has the shape and appearance of a feathered arrow, the feathers of the arrow lying in the plane of the arch, and the notch at its proximal end lying transversely to the feathers. The rays of the two rows of filaments on each arch are placed alternately to each other, the rays of one row lying opposite the spaces between the rays of the other. Each ray gives insertion on its inner surface, beyond its feathered portion, to a delicate, spindle-shaped muscle, which arises, by a long, double-headed tendon, from the outer surfaces of the two rays that lie opposite it and adjoin each other in the other row of filaments, the surfaces of origin lying immediately beyond the V-shaped ends of the rays. The surface of insertion of the tendon is relatively long, and the gill filaments are, naturally, free, or detached from each other, only in that part that lies distal to this surface; that is, for about two thirds their full length. By the contraction of these muscles, the filaments of one row are made to approach those of the other, and even to pass partly between them, with a scissor-like movement. On the demibranch no trace of these muscles could be found.

On both sides of each of the first four arches, toward the oral surface of the arch, there is a row of flat, bony processes of dermal origin. These processes (Figs. 38–42), on the antero-lateral surface of the first arch, are long and pointed, but elsewhere have the short, blunt form shown in Fig. 41. On the antero-lateral surface of the first arch they project forward, or forward and orally. On the antero-lateral surfaces of all the other arches they project almost directly laterally. On the postero-mesial surfaces of all the arches they project almost directly backward. The oral surfaces of all the arches are reduced to a narrow line, and the

oral ends of the curved bases of the processes reach this line. As the number of processes on the two sides of each arch is not exactly the same, the processes are not all placed in pairs, though many of them are approximately so arranged. The processes on the antero-lateral surface of the first arch are placed much more upon the oral surface of their arch than the other processes are, and their flat surfaces are presented, approximately, dorsally and ventrally. The flat surfaces of the other processes are presented anteriorly and posteriorly, or laterally and mesially, according as they lie on the anterior or posterior surfaces of an arch. The oral edges of all the processes are lined with bristles that seem to be of the same bony composition as the supporting rays of the gill filaments. They are jointed, at their bases, with a rod of similar composition, which extends into the substance of the process (Figs. 40 and 43). The bristle and rod are both hollow, and a blood vessel or capillary space could be traced into them under the microscope. The oral surfaces of the pharyngeal bones are covered with similar bristles, but their edges are not furnished either with processes or bristles. The bristles on these pharyngeal bones are stronger than those on the processes of the arches, and they are strongly curved and horn-shaped, the hollow of the curve being serrated. By this arrangement of processes and bristles the arches of the fish become a veritable sieve through which all the water that traverses the gill chamber is strained.

Between the dorso-anterior end of the first branchial arch and the demibranch, there is a narrow space, or line, along which the lining membrane of the gill chamber lies directly upon the lateral surface of the skull. This line lies immediately in front of the internal carotid foramen, and extends from near the ventral edge of the skull upward and slightly backward to the lower edge of the facial foramen. Its ventral end is connected with the corresponding end of the line of the opposite side of the head by a transverse groove on the dorsal surface of the mouth cavity, the groove lying immediately in front of the superior pharyngeal bones. The upper end of the line, on each side of the head, lies slightly in front of the plane of the blind, anterior end of the saccular recess of the cranial cavity. Immediately ventral to its upper end the line lies approximately external to the anterior edge of the depression that

lodges the anterior end of the utriculus. The ventral portion of the line lies external to the eye-muscle canal. That part of the branchial chamber that lies opposite the dorsal part of the line may, accordingly, serve for the transmission of vibrations to the ear, as Sagemehl claims for the corresponding part of the branchial chamber in *Amia* and other fishes (No. 64, p. 208). It is important, however, to note that there is in *Scomber* no true bulla acustica nor bulla lagena, and that, excepting in the narrow line above described, which lies mainly in front of and below the ear, the branchial chamber is everywhere separated from the ear by muscles or other tissues.

2. Basal Line.

The basal line (Figs. 29 to 34) contains five pieces, the anterior and posterior of which are detached from the other three which together form a single piece. The anterior piece is the basihyal; the other four are the basibranchials. The anterior basibranchial is sometimes found in two separate parts or pieces, as will be described below.

The Basihyal (*BH*) is a lanceolate piece lying in the tongue of the fish. Its dorsal surface is flat, its ventral surface convex. The anterior third or two fifths of the piece is of cartilage. Its posterior end, more or less rounded in different specimens, is not capped with cartilage. Its hind edge is slightly thickened and rests upon the dorsal edges of the distal ends of the bodies of the hypohyals and upon the adjoining and corresponding edges of the mesial processes of those elements. It overlaps, considerably, the anterior end of the first basibranchial. It is firmly bound by fibrous tissues to the hypohyals, the tissues arising mainly from the lateral edges and ventral surface of the basihyal, and being inserted on the middle portion of the lateral surface of the distal end of the hypohyal of either side. These tissues form the ventral portion and the base of the tongue of the fish.

The First Basibranchial (BB^1) occupies about one quarter of the length of the middle, united portion of the basal line. Its anterior end is capped with cartilage, and its hind end united by synchondrosis with the second element of the line. From the hind edge of its dorsal surface a wide splint process projects backward

onto the dorsal surface of the anterior end of the second basibranchial, and entirely covers the dorsal surface of the line of cartilage that separates the two elements. The basibranchial is much compressed laterally, especially in its middle portion, and is everywhere about twice as deep as it is wide. Its hind end is nearly twice as wide and twice as deep as its anterior end. Its anterior end lies between the anterior ends of the hypohyals, ventral to the mesial processes on the dorsal edges of those bones, and gives articulation to them. It is overlapped dorsally by the hind end of the basihyal. The articular facet, on each side, that gives articulation to the distal end of the first branchial arch lies wholly posterior to the bony part of this element. The element is thus, functionally, a basihyal rather than a basibranchial. In two of the several specimens examined it was formed of two pieces, the bone being separated into two parts by an irregular, transverse, suturallike line at about the middle of its length. In one of the two specimens in which this separating line was found it seemed artificial, and was so considered; in the other specimen, which was the one used for the drawings, the line was certainly natural, though it may, of course, have been due to some accident to the fish.

The Second Basibranchial (BB^2) has the same length as the first, and is connected with the two adjoining elements by synchondrosis, the separating interspaces of cartilage both being thicker at their ventral than at their dorsal edges. Like the first basibranchial it is deeper at its two ends than in its middle portion. Each end is about twice as deep as it is wide. The dorsal edge of the element is smooth and rounded; its ventral edge is narrow, rough and irregular. The anterior end of its dorsal edge is overlapped externally by the splint process of the first basibranchial; and at its posterior end a similar process, arising from it, overlaps slightly the anterior edge of the third basibranchial. On its lateral surface there is a deep, triangular depression, which starts from each end of its ventral edge and reaches almost to the dorsal surface of the bone. This depression is not sufficiently indicated in the drawings. Its anterior edge and portion is occupied by a long articular facet which receives the articular edge of the hypobranchial of the first arch, the facet being directed from above downward and forward at an angle of

about 45°. The antero-inferior end of the facet passes onto the cartilaginous interspace in front of the element, and almost touches the postero-ventral corner of the first basibranchial. That part of the depression portion of the bone that lies posterior to this facet lodges that part of the first hypobranchial that lies immediately posterior to its articular edge. The lateral surface of the piece, posterior to the depression, is roughened, and gives insertion to fibrous or semi-ligamentous tissues that bind the first hypobranchial to the basal line, and at the same time connect the first and second hypobranchials.

The Third Basibranchial (BB^3) is as long as the first two together, and about one half as deep. It is connected with the second basibranchial by synchondrosis, and ends posteriorly in cartilage. Its dorsal surface is rounded and smooth. The anterior quarter of its lateral surface is deeply cut away by the articular facet for the hypobranchial of the second arch, this facet resembling in every respect the articular facet on the second basibranchial, but being somewhat smaller than that facet and somewhat less strongly inclined downward. Posterior to the facet there is, as on the second basibranchial, a roughened surface, but it lies much more on the ventral than on the lateral aspect of the bone. It gives insertion to fibrous or semi-ligamentous tissues that bind the second hypobranchial to the basal line, and at the same time connect that hypobranchial with the hypobranchial of the third arch. The dorsal surface of the bone, between the dorso-posterior ends of the facets of opposite sides of the head, is narrow, and the ventral surface, between the ventro-anterior ends of the facets, is reduced to a narrow line. The antero-inferior end of the facet, like that of the facet on the second basibranchial, extends onto the cartilaginous interspace in front of the element, but not onto the bony element in front of that interspace. Both of these facets thus belong to a basal element numerically, in the nomenclature used, one posterior to the branchial arch to which they give articulation.

Posterior to the roughened surface that lies immediately behind the articular facet for the second hypobranchial, the third basibranchial is deeply grooved on its ventral surface through about one half the remainder of its length. The anterior end of this

groove extends forward into the bone and ends blindly. Toward its hind end the groove widens and then disappears, the bone at this point being slightly wider than it is immediately in front of it. Opposite the hind end of the groove the bone narrows somewhat abruptly, and then ends in a relatively long, cylindrical and bluntly pointed tip of cartilage, which turns gradually downward and, at its extreme hind end, lies in an almost vertical position. The distal end of this tip of cartilage lies in, and gives attachment to, the median, posterior portion of a U-shaped tendon, from which the obliqui ventrales of the fourth arch arise. The anterior ends of this U-shaped tendon are inserted, on each side, on the ventral edge of the third hypobranchial. The truncus arteriosus reaches the ventral surface of the basal line immediately in front of the hollow of the U, thus lying immediately ventro-anterior to the curved cartilaginous end of the third basibranchial.

The posterior portion of the third basibranchial, and the related part of the truncus arteriosus, are both enclosed between the scooped-out anterior ends of the hypobranchials of the third pair of arches. These third hypobranchials do not articulate with the main, central piece of the basal line, but do articulate with the anterior edge of a separate median piece of cartilage that lies immediately dorsal to the cartilaginous end of the third basibranchial. The fourth ceratobranchials also articulate with this median cartilaginous piece, and this, together with its general position, seems to indicate that it represents the fused hypobranchials of the fourth arch rather than a part of the basal line, and I have so considered it.

The Fourth Basibranchial (BB^4) is a small piece of cartilage that lies between the adjoining anterior ends of the fifth ceratobranchials, the anterior ends of those ceratobranchials lying between the scooped-out anterior ends of the fourth ceratobranchials, slightly behind, and slightly dorsal to the median cartilaginous piece with which those ceratobranchials and the third hypobranchials articulate.

3. Branchial Arches.

The first branchial arch (Figs. 29 and 30) contains five pieces, which seem to be the five elements said by van Wijhe to belong to a complete and perfect arch (No. 4, p. 662). That piece, how-

ever, that must, in that case, be the suprapharyngobranchial element lies ventral to instead of dorsal to the efferent artery of the arch. Its relation to the dorsal end of the afferent artery was not determined, and as that artery, at its dorsal end, lies somewhat ventral to the efferent artery it may lie ventral also to the suprapharyngobranchial. If this be so, which I consider doubtful, van Wijhe's expression "Kiemenvene" would refer to this artery and not to the efferent one as I was led to conclude in my work on *Amia* (No. 4, p. 662). If, as seems probable, both arteries lie dorsal to the element, van Wijhe's definition cannot apply to this piece in *Scomber*. It will, however, be treated as a suprapharyngobranchial.

In the second and third arches all the normal elements are found excepting only the suprapharyngobranchials, which are wanting. In the fourth arch both the suprapharyngobranchial and hypobranchial are wanting, unless the latter element is represented in that small median piece of cartilage with which the ceratobranchial of the arch articulates, in which case the little cartilage represents, as already stated, the fused hypobranchials of opposite sides of the head. The fifth arch contains only a ceratobranchial and a small detached piece similar to the one, which, in *Amia* (No. 4, p. 649), I considered as the epibranchial rather than the suprapharyngobranchial of the arch. The third and fourth infrapharyngobranchials are firmly united to form a single piece.

The gill opening between the fourth and fifth arches lies, as in *Amia*, entirely on the ventral aspect of the arches, and does not extend to their outer or posterior angles.

The Three Hypobranchials decrease regularly in length from the first to the third arch.

The First Hypobranchial (*HB, I*) may be said to consist of a shank; a large, flat, somewhat triangular portion, on which is found the articular edge of the piece; and a pointed anterior end, or process. The shank of the bone is semicylindrical, occupies somewhat more than the posterior half of the element, and is deeply grooved on its ventral surface. The ventral edge of the triangular articular portion is formed by the anterior part of the true ventral surface of the element, is grooved, though less deeply so than the shank posterior to it, and is separated from the

shank by the deep anterior end of the groove that lodges the afferent artery of the arch. This ventral edge forms the base of the triangular articular portion of the element. The summit of the triangle, which lies directly dorsal to it, projects upward and slightly mesially, is usually somewhat rounded, and fits into the triangular depression on the lateral surface of the second basibranchial. The anterior edge of the triangle is not seen in the figures, being hidden from view by the projecting anterior process of the element. It is presented antero-dorsally, is slightly rounded both longitudinally and transversely, is capped with cartilage, and forms the distal articular surface of the piece. The ventral end of the strip of cartilage that caps this edge forms the anterior end of the true ventral surface of the entire element, and is seen in Fig. 30. It touches, or almost touches, in the mid-ventral line, the corresponding part of the hypobranchial of the opposite side of the head. The pointed anterior process of the element is formed by an anterior prolongation of the superficial layers of the lateral and dorso-lateral surfaces of the piece, and its ventral edge forms a direct prolongation of the lateral bounding edge of the groove on the ventral surface of the element. It is slightly concave internally, and extends forward, nearly parallel to the dorsal part of the lateral surface of the first basibranchial, but separated from it by a certain space.

Where the triangular portion of the element joins the shank, the mesial edge of the grooved ventral surface of the piece is cut away by a groove which, beginning on the hind end of the mesial surface of the triangular portion, leads backward onto the ventral surface of the shank of the element. It lodges the ventral end of the afferent artery of the arch.

The proximal end of the element articulates with the ceratobranchial of its arch, and is capped with cartilage.

The Second Hypobranchial (*HB, II*) resembles the first excepting that its triangular articular portion is stouter, and that the element has no anterior process projecting beyond its articular edge. The entire anterior edge of this hypobranchial is capped with cartilage, and forms the articular head of the piece. The groove on the ventral surface of the shank of the element lies at a deeper or more dorsal level than the continuation of the groove

along the ventral surface of the triangular portion, a sort of pocket being often formed between the two portions. Opposite this pocket the mesial edge of the groove is cut away, as on the first arch, and the afferent artery of the arch here reaches the ventral surface of the hypobranchial. Anterior to the pocket, the mesial edge of the ventral surface of the element often projects posteriorly in a nearly longitudinal position, and forms a more or less developed process which lies immediately ventral to the artery of the arch. In the specimen used for illustration this process was but slightly developed, and, by error, the line marking its hind end has been omitted in the figure. In all the figures the hypobranchials are pulled somewhat apart so as better to show the basal line. In its natural position this part of the second hypobranchial closely adjoins, in the mid-ventral line, the corresponding edge of its fellow of the opposite side of the head, a slit-like space only being left between the two edges. The opposing surfaces of the two elements here partly enclose the truncus arteriosus.

The proximal end of the element is capped with cartilage and articulates with the ceratobranchial of its arch.

The Third Hypobranchial (*HB, III*) may be said to consist of a body, and one or two thin laminar processes. The body of the piece has a wide and thick posterior end, from which it tapers rapidly forward, in curved lines, into a long and slender anterior end. The lateral edge of its posterior third is thin; the corresponding portion of its mesial edge being thickened. The dorso-mesial corner of the hind end of the element projects upward and mesially, as a relatively stout eminence, which nearly meets in the middle line, dorsal to the line of basal elements, the corresponding part of the hypobranchial of the opposite side of the head. The external surface of the element is convex, and is presented dorso-laterally. The internal surface is concave and is presented ventro-mesially. The hind edge of the bony part of the element is rounded, and is capped with a thick cap of cartilage, the free, posterior edge of which presents three regions separated by more or less pronounced angles. The lateral and mesial ones of these three regions are larger than the middle one, and articulate, respectively, with the ceratobranchial of the third arch, and with the antero-lateral edge of the small median piece of cartilage that seems to represent the fused hypobranchials of the fourth pair of arches.

The middle portion usually articulates with the lateral corner of the anterior articular cap of the ceratobranchial of the fourth arch, and is often reduced to a small surface which simply forms the outer, rounded end of a strong angle that separates the other two articular regions. This latter form is the one shown in the figures, the fourth ceratobranchials being pulled backward considerably out of their natural position, and out of all contact with the third hypobranchials. In some specimens the articulation with the fourth ceratobranchial seemed not to exist at all. The antero-mesial end of the surface that articulates with the small median cartilage, forms the extreme dorso-mesial corner of the element, which thus lies in front of the median cartilage.

The one or two laminar processes of the piece arise from its internal surface. The larger of these two processes, where there are two, or the single process, where there is but one, arises in a line which extends backward, from the lateral edge of the anterior half of the piece, along its internal surface. Its ventral edge is a direct continuation of the lateral edge of the anterior part of the element, the continuous edge so formed projecting ventro-mesially and lying nearly parallel to the basal line. Its hind end projects backward, beyond its base of origin from the internal surface of the element, and ends in a point approximately opposite the hind end of the entire element. The second process, when found, lies about midway between the first process and the dorso-mesial edge of the element. In some specimens it is a pronounced laminar process, in others simply a slight ridge. It begins at the hind edge of the bone, opposite that angle of the cartilaginous cap of the piece that separates the lateral articular region from the middle one, and runs forward, parallel to the first process, to a point slightly anterior to the hind edge of the base of that process. Its ventro-mesial surface represents the anterior continuation of the grooved ventral surface of the ceratobranchial of the arch.

The small, anterior end of the element turns slightly outward and is capped with cartilage. The element does not articulate directly, at any place, with the basal line.

The third hypobranchials of opposite sides of the head enclose between them the posterior portion of the third basibranchial and the posterior half of the truncus arteriosus; the artery and basi-

branchial lying between the dorso-mesial surfaces of the larger laminar processes of the hypobranchials, and that part of the ventro-mesial surface of the body of each hypobranchial that lies dorsal to that process. The ventro-mesial edge of the large laminar process of each element is nearly horizontal in position, lies ventral to the truncus arteriosus and not far from the corresponding edge of the hypobranchial of the opposite side of the head. The afferent artery of the second arch turns outward and backward dorsal to the anterior end of the third hypobranchial, between it and the ventral surface of the basal line. The arteries to the third and fourth arches are given off immediately in front of the turned-down posterior end of the third basibranchial, and run outward and backward dorsal to the projecting hind end of the laminar process of the third hypobranchial.

The Fourth Hypobranchial seems, as already stated, to be fused with its fellow of the opposite side of the head, and to be represented in that small, median piece of cartilage that lies immediately dorsal to the cartilaginous hind end of the third basibranchial. It gives articulation to the proximal ends of the third hypobranchials and to the distal ends of the fourth ceratobranchials, as already described.

The First Three Ceratobranchials (*CB, I–III*) are practically alike in shape, but they decrease more or less in length from the first to the third. They are all slightly curved, semicylindrical rods of bone, the ventral surfaces of which are deeply grooved their full length. The third ceratobranchial is somewhat more curved than the second, and the second somewhat more than the first. The hollows of the curves are directed orally, that is, toward the branchial chamber. Both ends of all three elements are capped with cartilage. The distal end of the third ceratobranchial has usually, on its postero-mesial corner, a small process which takes part in the formation of the articular end of the piece, thus giving it an articular surface somewhat larger than those of the other two bones.

The Fourth Ceratobranchial (*CB, IV*) has almost exactly the length of the second, and is accordingly somewhat longer than the third. It is more curved than the anterior bones, and is also somewhat flattened. The distal third, approximately, of the bone

is somewhat wider than the posterior two thirds, and is scoop-shaped, the hollow of the scoop directed mesially. The inferior edge of the scoop projects ventrally and mesially as a thin ridge of bone, and the groove on the ventral surface of the element continues forward, antero-lateral to it, that is, along the posterior half of the ventro-lateral, or external surface of the scoop. Between the hind edge of the scoop and the postero-mesial edge of the shank of the bone there is a groove which leads from the main groove on the ventral surface of the element into the hollow of the scoop. It transmits the nerve and artery of the arch. Both ends of the bone are capped with cartilage, the anterior end articulating, as already stated, with the small median piece of cartilage that represents the fused hypobranchials of the fourth pair of arches, and also often with the middle portion of the posterior articular cap of the third hypobranchial. The dorsal corner of the anterior cap touches, or nearly touches, in the middle line the corresponding corner of the element of the opposite side of the head.

The Fifth Ceratobranchial (*CB, V*) is usually slightly shorter than the anterior ones. It may be said to consist of three parts, a slender, curved, rod-like part, somewhat similar to the anterior ceratobranchials, and two processes, one directed ventrally and the other mesially. The rod-like part of the bone is doubly curved, the hollow of one curve presented antero-laterally, that of the other presented dorsally. Both ends of the rod are capped with cartilage, the end of the anterior cap touching or almost touching, in the middle line of the head, its fellow of the opposite side. Between these anterior ends of the two elements lies the small cartilaginous fourth basibranchial, with which both of the ceratobranchials articulate. The ventral process of the piece arises from the middle three fifths of the ventral surface of the rod. Its antero-lateral surface is slightly concave; its postero-mesial surface slightly convex. Its ventral edge is thin and rounded. The mesial process of the piece is a thick, somewhat triangular plate, the base of the triangle rounded and directed posteriorly. The dorsal surface of the plate is slightly concave, the ventral surface slightly convex. The process arises from the dorsal edge, or dorsal surface of the rod of the piece, the extent of the region of origin corresponding approximately to that of the ventral

process, but extending somewhat farther along the rod-like part of the bone, both anteriorly and posteriorly. The posterior, rounded, free end of the process lies at a higher, more dorsal level than the posterior end of the rod of the piece. The entire dorsal surface of the process, and the adjoining dorsal surface of the rod, are both covered with a layer of dermal bone, from which rise numerous, strong, curved bristles. A bristly pad is thus formed which is the inferior pharyngeal pad of the fish. The anterior third of the piece lies, with its fellow of the opposite side of the head, between the scoop-shaped ends of the fourth ceratobranchials, the anterior ends of the two fifth ceratobranchials being enclosed in fibrous tissue and attached to, but not articulating with, the hind edge of the median piece of cartilage that represents, apparently, the fused fourth hypobranchials.

The Epibranchials of the first four arches decrease in length from the first to the fourth.

The First Epibranchial (*EB, I*) is a slender, semicylindrical rod of bone, curved in two directions, the hollow of one curve being presented dorsally, that of the other postero-mesially. It has, slightly proximal to the middle of its length, a short, stout, somewhat cylindrical process, directed mesially, or mesially and forward, from the postero-mesial surface of the element. The dorsal surface of the element is deeply grooved, the groove extending from the distal end of the bone forward to the anterior edge of the postero-mesial process, where it turns mesially, and leaves the bone, on its postero-mesial surface, in the angle between the process and the anterior end of the shank of the bone. Both ends of the bone are capped with cartilage, as is also the outer end of its postero-mesial process. The anterior end of the element articulates with the infrapharyngobranchial of the arch, the postero-mesial process articulates with the suprapharyngobranchial of the arch, and the hind end of the element articulates with the corresponding ceratobranchial.

The Second Epibranchial (*EB, II*) is a strongly curved bone with an enlarged, flat, triangular, proximal end. Both ends of the bone are capped with cartilage, the cap on the enlarged proximal end having the shape of an elongated and solid figure 8. The antero-lateral end of this 8-shaped cap articulates with the second

infrapharyngobranchial, the postero-mesial end articulating with the third infrapharyngobranchial. Slightly distal to the triangular articular head of the piece, on the postero-mesial edge of the bone, there is a strong, angular or triangular process, directed at first postero-mesially, perpendicularly to the shank of the bone, and then distally parallel to that shank. The hind end of the process gives insertion to the third interarcualis dorsalis; its anterior edge giving insertion to the external levator of the second arch. Immediately distal to this process the bone has its narrowest portion. The dorsal surface of the bone is deeply grooved, the groove running forward to the proximal edge of the postero-mesial process, where it disappears.

The Third Epibranchial (*EB, III*) has a short, straight shank, and much enlarged, somewhat triangular proximal end, which lies nearly at right angles to the shank. Both ends of the bone are capped with cartilage, the proximal articular head articulating with a process of the third infrapharyngobranchial that projects backward onto the dorsal surface of the adjoining fourth infrapharyngobranchial. This process of the third infrapharyngobranchial is capped with cartilage, the large articular surface thus formed lying directly dorsal to, and extending across, the line that separates the third infrapharyngobranchial from the fourth. At the angle between the shank and the proximal articular head of the third epibranchial, from the postero-mesial edge of the bone, there is a strong, irregular process, which lies approximately at right angles both to the shank of the bone and to its enlarged articular head. It is directed backward, mesially and slightly upward. Its outer end is large and capped with cartilage; and it articulates with a process on the antero-lateral edge of the fourth epibranchial. Its anterior edge projects somewhat upward as a sharp ridge which gives insertion to a part of the third obliquus dorsalis. The outer end of the process gives insertion to the external levator of the third arch; and from the lateral end of its outer, or posterior edge there is a process directed backward and laterally, approximately parallel to the shank of the piece, which gives insertion to the fourth interarcualis dorsalis. The outer end of the process articulates with the antero-lateral edge of the fourth epibranchial. Between the hind edge of the process and the edge

of the shank there is sometimes a deep rounded groove which looks like a partly enclosed foramen. It is lined, in the natural condition, with a thin mucous membrane and marks the upper limit of the gill opening between the two arches. The shank of the bone is grooved on its dorsal surface, the groove turning mesially around the anterior edge of the postero-mesial process of the element and running off the postero-mesial edge of the base of the large articular head.

The Fourth Epibranchial (*EB, IV*) is a short bone bent at right angles between its shank and its flat, irregularly triangular, proximal end. The shank of the bone is but slightly or not at all grooved on its dorsal surface, but it has, along its postero-mesial edge, a rough, irregular ridge. Both ends of the piece are capped with cartilage, the proximal cap being usually separated into two portions, a large anterior one and a small posterior one. The anterior cap articulates with the fourth infrapharyngobranchial, lying transversely to an articular strip of cartilage on the dorsal surface of that element. The posterior cap lies on a more or less distinct process of the element, and articulates, without the intermediation of a cartilaginous facet, directly with the dorsal surface of the fourth infrapharyngobranchial immediately posterior to the cartilage that gives articulation to the main articular head of the piece. This posterior process of the epibranchial, and the fourth infrapharyngobranchial, are strongly but loosely connected with each other by ligament, the attachment of the ligament to the infrapharyngobranchial being on a part of that bone that is of cartilaginous origin and not on the adjoining dermal part.

At the angle between the head and the shank of the epibranchial, on its antero-lateral edge, there is a small process directed anteriorly and capped with cartilage. It articulates with the postero-mesial process of the third epibranchial. The proximal head of the element is, in its natural position, directed downward, backward and mesially.

The First Infrapharyngobranchial (*IPB, I*) is a small, conical, curved bone with a large cartilaginous cap at its larger, distal end, and a small one at its pointed, proximal end. It is directed upward, laterally, and slightly backward along the ventral

portion of the lateral surface of the skull, lying, when at rest, immediately in front of, or immediately external to, the internal carotid foramen, and immediately behind the posterior edge of the surface of insertion of a part of the united and continuous adductor hyomandibularis and adductor arcus palatini muscles. The lateral surfaces of the parasphenoid and petrosal are here slightly grooved, where the infrapharyngobranchial rests against them, the proximal end of the latter bone reaching about to the inferior edge of the facial foramen, where it is bound to, and articulates with, the skull. The proximal end of the bone lies immediately ventral to the ventral edge of the opercular demibranch, and, when pulled backward, encloses the internal carotid artery between itself and the side wall of the skull. The external carotid lies wholly dorsal to it. The cartilaginous, inferior end of the element is hollowed slightly, and articulates with the rounded proximal end of the first epibranchial, the hollow of the infrapharyngobranchial being presented ventrally, laterally and posteriorly.

In *Amia* (No. 4) the common carotid artery runs forward ventral to the first infrapharyngobranchial, and separates, beyond that bone, into its external and internal portions. The internal carotid alone of *Scomber* retains this relation to the infrapharyngobranchial, the external carotid having apparently slipped upward, between the infrapharyngobranchial and the side wall of the skull,

In my notes I find reference to some fish, I can not recall which, in which a ridge is described on the lateral surface of the skull, in a position corresponding to that of the first infrapharyngobranchial of *Scomber,* and which might accordingly be that bone fused with the skull.

The Second Infrapharyngobranchial (*IPB, II*) is a flat, irregular bone, which, in its natural position, lies in a plane inclining downward, forward and laterally. In Fig. 29 it has been pulled somewhat out of its natural position and is shown inclining downward and backward instead of downward and laterally. Its inferior edge is slightly curved and is covered with dermal bone which is furnished with numerous bristles. It forms the anterior one of the two superior pharyngeal bones on each side of the head of the fish. The bristles it bears are smaller and shorter than those on the posterior bone. The superior, or antero-lateral sur-

face of the bone is deeply hollowed, near the middle of its superior edge, and there gives insertion to the anterior division of the internal levator of the arches, and to the obliquus dorsalis of the first arch. The inferior, or postero-mesial surface of the bone is deeply hollowed in its anterior half, and the dorsal edge of the bone, above the hollow, gives insertion to parts of the obliquus dorsalis of the second arch, and of the transversus dorsalis anterior. The inferior surface of the bone, behind the depression, is overlapped mesially by the anterior pointed end of the third infrapharyngobranchial.

The dorsal edge of the anterior portion of the element is cartilaginous, the cartilage extending backward to about the middle point of the dorsal edge of the element, where it ends, presenting a free hind end which gives articulation to the proximal end of the suprapharyngobranchial of the first arch. This cartilaginous edge of the infrapharyngobranchial lies parallel to and ventro-postero-mesial to the anterior end of the first epibranchial; and the anterior ends of the two elements are bound together by fibrous tissues.

At about the middle of the posterior half of the dorsal edge of the infrapharyngobranchial, and immediately posterior to the depressed region on its inferior surface, there is another piece of cartilage, the outer surface of which is presented backward, dorsally and laterally. It gives articulation to the anterior part of the proximal articular head of the second epibranchial.

The Third and Fourth Infrapharyngobranchial (*IPB III–IV*) are firmly united to form the posterior and larger of the two superior pharyngeal bones of each side of the head. The two elements are however not fused, and can be easily separated without fracture. Both bones have a large dermal portion which covers their ventral surfaces and bears the bristles with which the bones are furnished. Both bones are strongly convex on their ventral surfaces, and their bristles form a large, longitudinal, convex pad on the dorsal surface of the branchial cavity. The pads of opposite side of the head are separated from each other by a deep, wide, median groove. The postero-lateral ends of the anterior pharyngeal pads touch the lateral edges of the anterior ends of the posterior pads, and, from there, run forward and

mesially enclosing a triangular, depressed portion of the roof of the branchial cavity. The dermal portions of all these bones have not the some color and texture as the underlying cartilage bones, but they cannot be separated from them without facture.

The third infrapharyngobranchial has a pointed anterior end and a straight posterior edge. From the mesial portion of the latter edge a strong process projects posteriorly. The pointed anterior end of the element is capped with cartilage and overlaps and lies against the postero-mesial surface of the second infrapharyngobranchial. Starting from this end of the element, and running backward across its entire dorsal surface, there is a strongly raised portion, the hind end of which forms the lateral edge of the posterior process of the element. At about the middle of the length of the ridge there is a slight eminence, and at its hind end a large and strong one. The outer surfaces of both eminences are directed upward, backward, and slightly laterally, and are capped with cartilage. The anterior one gives articulation to the posterior portion of the articular head of the second epibranchial. The posterior one lies lateral to the posterior process of the element and gives articulation to the epibranchial of the third arch. The posterior process of the element is capped with cartilage and overlaps dorsally the fourth infrapharyngobranchial, the cartilaginous cap of the process resting upon a cartilaginous portion of the fourth infrapharyngobranchial. It does not give articulation to any structure.

The fourth infrapharyngobranchial has a straight anterior edge, and from there tapers gradually backward, with slightly convex edges, to a bluntly rounded posterior end. From the mesial corner of its anterior edge a long and slender process projects forward and overlaps the mesial edge of the hind part of the third infrapharyngobranchial. Slightly posterior to the anterior edge of the piece there is, on its dorsal surface a wide transverse, raised strip of cartilage. The mesial end of this strip is hollowed out, and receives the overlapping end of the posterior process of the third infrapharyngobranchial. The hind edge of the strip of cartilage on the fourth infrapharyngobranchial is usually here exposed. The lateral and larger part of the strip is concave dorsally and gives articulation to the anterior portion of the prox-

imal articular head of the fourth epibranchial. The posterior portion of the articular head of the latter element, which is usually, as already described, found as a separate process with a separate cartilaginous cap, does not articulate with the cartilaginous strip on the fourth infrapharyngobranchial, but rests upon the dorsal surface of that element posterior to the cartilaginous strip.

In addition to the two superior and one inferior pharyngeal pads above described, there is, on each side of the head, a small fourth pad, which lies on the lateral surface of the pharynx between the hind end of the inferior pad and that of the large, posterior, superior one. It is furnished with bristles, like the other pads, and consists of a dermal cement component and a small underlying, comma-shaped piece of cartilage. The cartilage underlies the anterior end of the piece, and touches, with its enlarged end, and is bound to, the ceratobranchial and epibranchial of the fourth arch at the adjoining articular ends of those two elements. The small end of the cartilage is directed toward the posterior end of the fifth ceratobranchial, but is separated from that element by a considerable interval. It gives insertion to the adductor muscles of the fifth arch. From its association with this muscle it would seem to be the epibranchial of the fifth arch. Its formation of two components, one cartilaginous and the other dermal, the latter furnished with bristles, would, on the contrary seem to indicate that it is an infrapharyngobranchial. What seems to be a corresponding cartilage in *Alepocephalus* is considered by Gegenbaur (No. 29, p. 24) as a detached process of the fourth arch. A somewhat similar piece in *Clupea* is considered by the same author as a rare instance of the "Erhaltung der Rudimentes eines zweiten oder obere Gliedstückes am fünften Kiemenbogen."

Between this lateral pharyngeal pad and the inferior and superior pads, there are usually three small detached pieces of dermal bone, furished with bristles similar to those on the other larger pads. They all lie approximately superficial to the hind end of the rod-like part of the fifth ceratobranchial.

The First Suprapharyngobranchial (*SPB, I*) is a short cylindrical rod of cartilage that runs downward, forward and mesially from the anterior end of the postero-mesial process of the first epibranchial to the small facet on the hind end of the

anterior cartilaginous portion of the dorsal edge of the second infrapharyngobranchial. It lies, as already stated, ventral to the efferent artery of its arch, and probably ventral also to the dorsal end of the afferent artery, but its relations to the latter artery were not satisfactorily traced.

No suprapharyngeal elements were found on the other arches. The postero-mesial processes of the second and third epibranchials are, however, like the corresponding processes in *Amia* (No. 4, p. 663), suprapharyngeal in position.

4. Hyoid Arch.

The hyoid arch of *Scomber* contains, in addition to the so-called basihyal, three separate pieces, which articulate one with the other, the proximal piece articulating with the lateral surface of the skull by two articular heads. This proximal piece contains two ossifications, the hyomandibular and symplectic, connected with each other by a small interspace of cartilage. The middle one of the three separate pieces of the arch, the interhyal, articulates with the interspace of cartilage between the hyomandibular and symplectic, and has, as in *Amia* (No. 4, p. 653), the position of an epal element of the arch. The distal one of the three separate pieces is large, long and flat, with its long axis lying in a nearly horizontal position and its transverse axis inclining downward and slightly mesially. The anterior end of its superior edge lies slightly dorsal to the corresponding edge of the first branchial arch; the posterior end somewhat ventral to the outer end of the same arch. It contains four separate ossifications, two of which form the hypohyal of current nomenclature, and the other two the ceratohyal and epihyal. For reasons given in my work on *Amia* (No. 4, p. 654), I consider the last two ossifications as the proximal and distal ossifications of the ceratohyal. Between the hypohyal and the ceratohyal, as thus defined, there is a definite surface of separation, but tough fibrous tissue, which is apparently in part the periosteum or perichondrium of the structure, passes over the separating line, and so firmly unites the two pieces that only a slight movement is possible between them. The surfaces by which the two elements thus articulate are each separated into three parts, two of which are transverse to the piece and the other

one oblique, or even longitudinal. The oblique portion lies between, and connects, the other two, which are one dorsal and the other ventral to it, the dorsal one lying proximal, or posterior, to the ventral one. The transverse surfaces on both bones are capped with cartilage. The oblique portion is not so capped.

The Hypohyal (*HH*) contains, as above stated, two separate ossifications. They are united by a narrow line of cartilage which starts from near the dorsal edge of the proximal, posterior end of the piece and runs distally to about the middle of its distal end. The dorsal ossification is thus the smaller of the two. At the dorsal corner of its distal end it has, on its mesial surface, a strong process, usually conical in shape, with a pointed end directed mesially and backward. It is strongly but loosely bound by fibrous or ligamentous tissue to its fellow of the opposite side of the head, the two processes, so united, lying antero-dorsal to the cartilaginous anterior end of the first basibranchial, and ventral to the hind end of the basihyal. On their ventral surfaces both processes are slightly hollowed, and there articulate with the end of the first basibranchial.

At the inferior corner of the distal end of the ventral ossification, there is a rounded eminence, and slightly proximal to it, on the ventral edge of the ossification, another eminence. The latter eminence gives insertion to a ligament that has its origin from the anterior end of the sternum, and that corresponds to the tendinous end of the sterno-hyoideus muscle of *Amia*. The anterior eminence is capped with cartilage and articulates, in the middle line of the head, ventral to the anterior end of the basal line, with the corresponding process of the hypohyal of the opposite side. On the lateral surface of this same ossification, adjoining the process that gives insertion to the ligament from the sternum, there is a slight depression which indicates the surface of insertion of the anterior tendinous end of the hyohyoideus muscle of the opposite side of the head. On the mesial surface of the entire element, in the cartilaginous line that separates its two ossifications, and somewhat distal to the middle point of the line, there is a round foramen. It is the internal aperture of a canal that leads backward and laterally through the element, between its two ossifications, and that gives passage to the arteria hyoidea. Having reached the external

surface of the element, this closed canal becomes an open channel which runs proximally to the end of the piece, lying always in the line between the two ossifications.

A laminar process, arising from the superficial layers of the bone, projects backward from the proximal end of the lateral surface of the ventral ossification, and usually overlaps to a certain extent, the adjoining edge of the ceratohyal.

The two ossifications of the Ceratohyal (*CH*) are one distal and the other proximal. They are separated by a transverse interspace of cartilage which is partly or wholly interrupted, near its middle portion, by long, splint processes, which project from the ends of both ossifications and firmly interlock. The distal ossification is somewhat longer than the proximal one, and the two together form a single piece with a flat, blade-like portion and a somewhat stouter, but relatively broad, handle. The proximal end of the piece is bluntly pointed, and has, slightly distal to the blunt end, on the dorsal edge of the piece, a slight depression which forms an articular facet for the distal end of the epihyal. It lies somewhat on the lateral surface of the piece, and is lined with what seems to be fibrous or fibro-cartilaginous tissue, and not with true cartilage. Slightly distal to it, near the middle line of the lateral surface of the piece, there is a more or less pronounced depression which forms the surface of origin not only of a short strong ligament that has its insertion on the inner surface of the dorsal edge of the interoperculum, but also of fibrous tissue that has its insertion mainly on the inner surface of the interoperculum near its anterior end. From this latter point a fibrous band runs downward and forward to the inner surface of the hind end of the angular. The strongly developed ligamentum mandibulo-hyoideum of *Amia* is thus either wholly wanting in *Scomber,* or it is represented in fibrous tissues a part of which arise from the ceratohyal and are inserted on the interoperculum, while the other parts arise from the interoperculum and are inserted on the angular.

Dorsal to the depression that gives insertion to the fibrous and ligamentous tissues above described, there is, along the outer surface of the ceratohyal, a deep longitudinal groove. Running distally this groove crosses the interspace of cartilage between the

two ossifications of the ceratohyal, there lying dorsal to the splint processes that connect those ossifications, and, having reached the distal end of the element, joins the end of the groove that lies between the two ossifications of the hypohyal. It lodges the arteria hyoidea, after that artery issues from the canal through the hypohyal.

The adjoining edges of the two ossifications of the ceratohyal are slightly rounded, this being most marked toward the ventral edge of the element. In the middle line of the cartilaginous interspace that lies between the two ossifications there is some slight indication of the beginning of the formation, or the end of the existence, of a separating line.

The Epihyal (*EH*), or interhyal, is a small bone the distal end of which is large and flat, the proximal end small and rounded. In its natural position it lies directed dorsally and slightly forward, approximately at right angles to the long axis of the ceratohyal, and in the direction of a ventral continuation of the axis of the ventral end of the hyomandibular. By its dorsal end it articulates with a facet in the interspace of cartilage that lies between the hyomandibular and symplectic. On the posterior half or two thirds of its ventral end there is a rounded cartilaginous eminence which articulates with the facet on the dorsal edge of the proximal end of the ceratohyal. The anterior half or third of its ventral end is not capped with cartilage and forms a sort of process which abuts against the edge of the ceratohyal and so limits the motion of the joint. The process gives attachment to a part of the articular ligament of the joint.

The Hyomandibular (*HMD*) is, roughly, a strong rod of bone lying inclined downward and slightly backward, and having, close to its dorsal end, two strong processes, one directed forward and slightly upward, and the other almost directly backward. The dorsal end of the rod itself, and the ends of both its processes, are capped with cartilage and form articular heads. The articular surface on the dorsal end of the rod itself is oval in form, the long axis of the oval directed downward, forward and mesially. It articulates with the lateral surface of the skull, near its dorsal edge, in the long facet on the ventro-lateral surface of the squamosal. The articular surface on the anterior process is

smaller than the dorsal one and articulates with the lateral surface of the skull in the facet on the lateral surface of the postorbital ossification. The articular surface on the posterior process gives articulation to the operculum.

Between the ventral edge of the anterior process of the hyomandibular and the anterior edge of the shank of the bone below it, there is a wide, thin plate, apparently of membranous origin. It lies on a level with the internal surface of the hyomandibular and gives to that aspect of the bone a large and nearly flat surface. The lateral aspect of the bone, on the contrary, is an irregular surface. It is separated into anterior and posterior portions by a strong ridge of bone which extends from the ventral end of the element upward and forward, in a slightly curved line, almost to its dorsal end. The ridge projects laterally and backward, and its posterior surface forms, with the posterior portion of the lateral surface of the bone, a deep groove, which is practically a groove on the posterior or dorso-posterior edge of the element. The dorsal end of the preoperculum fits into the dorsal part of this groove, the dorsal end of that bone coming to, or extending slightly above, the dorsal end of the ridge on the hyomandibular, the two bones being firmly united by fibrous tissues. Ventral to its dorsal end the anterior edge of the preoperculum curves downward and forward and lies at first external to the ventral end of the hyomandibular, and then, ventral to that bone, external to the adjoining dorsal end of the symplectic.

The middle portion of the anterior surface of the ridge on the hyomandibular fits against the dorsal portion of the hind edge of the metopterygoid, the latter bone lying external to that thin plate-like portion of the hyomandibular that fills the angle between the ridge and the anterior process of the bone. A short process on the posterior edge of the metapterygoid projects backward, internal to this plate-like portion of the hyomandibular, and also internal to the shank of the bone beyond it. The two bones are thus here firmly held together by bony processes, as well as by the fibrous tissues that connect them, the hyomandibular becoming, in appearance, a part of the palato-quadrate arch.

Between the hind edge of the hyomandibular and the anterior edge of the preoperculum, where the latter bone turns forward

and downward across the external surface of the ventral end of the former, there is a narrow slit, which transmits the truncus mandibularis facialis, from the groove on the dorso-posterior surface of the hyomandibular to the external surface of the hyomandibulo-symplectic. In the groove on the dorso-posterior surface of the hyomandibular, somewhat above the middle point of the bone, a canal leads forward and upward into the bone itself, and issues on its mesial surface near the ventral edge of the base of the anterior articular process. This canal transmits the truncus hyoideo-mandibularis facialis from the internal surface of the hyomandibular to the groove on its dorso-posterior edge. The facial nerve thus has, in a part of its course, much the same relations to the hyomandibular that the branchial nerves have to the proximal elements of their respective arches.

The ramus hyoideus facialis leaves the truncus hyoideo-mandibularis near the ventral end of the groove on the dorso-posterior surface of the hyomandibular, and, passing backward and inward between the adjoining edges of the hyomandibular and preoperculum, issues on the internal surface of the latter bone slightly dorsal to the dorsal end of the epihyal.

From the canal that transmits the facial nerve through the hyomandibular, near its dorso-internal end, a small canal leads backward and laterally in the bone. It soon separates into two parts both of which traverse the bone and issue in the groove on its dorso-posterior surface, one at the level of the dorsal edge and the other at the level of the ventral edge of the base of the opercular process (Fig. 36). The openings of both of these canals lie internal to the preoperculum, between it and the hyomandibular, and they both give passage to branches of the facialis destined to supply the one or more lateral sense organs that lie in the dorsal part of the canal that traverses the preoperculum.

The ventral end of the hyomandibular is united by a small interspace of cartilage with the dorsal end of the symplectic. Adjoining the ventral end of the hyomandibular a part of this cartilage seems to belong much more to that bone than to the rest of the interspace, the histological condition being such that the hyomandibular could almost always be separated with a rounded cartilaginous end attached to it, this end fitting into a corresponding

concavity in the remainder of the interspace. The general appearance of the cartilage here, when cut and examined under low powers, was exactly the same as that found in sections of the cartilaginous basal line of larvæ of *Amia* at the points where, later, the line separates into its several parts.

Goronowitsch (No. 32, pp. 32–34) considers the anterior, or postorbital articular head of the hyomandibular of teleosts, as the primary dorsal end of the element, the posterior, squamosal head being of secondary and later origin. A lamellar wing is said by him to be developed along the posterior edge of the axial part of the hyomandibular, very probably as a surface of insertion for the Mm. operculare, and the dorsal edge of this wing is said to acquire articular relations with the squamosal. This, and other considerations, are then said by him to indicate that the cranio-hyoid articulation has, in the higher fishes, first shifted forward, from a posterior position, onto the postorbital process, and then reacquired a secondary, posterior, squamosal articulation in the manner indicated. *Amia* and *Scomber* certainly do not support this proposition; for in both these fishes the squamosal part of the articular end of the hyomandibular seems to belong to the axial part of the element fully as much as the postorbital articular end, and in neither fish does the hind edge of the hyomandibular give insertion to the Mm. operculares, those muscles arising directly from the lateral surface of the skull. Why a special plate should be especially developed on the hyomandibular to give to these muscles the disadvantageous point of origin they would necessarily have upon that bone, is not easily imagined; more especially as, in their apparent derivation from the adductor hyomandibularis, they had from the start a more advantageous position.

The Symplectic (*SY*) is a long, narrow, tapering bone directed downward and forward from the interspace of cartilage that unites it with and separates it from the hyomandibular. The dorsal part of the bone lies between a long, dorso-posterior process of the quadrate and a narrow line of cartilage that edges the ventral part of the hind edge of the metapterygoid, being separated from the process of the quadrate by a narrow space, but lying directly against the strip of cartilage. The ventral part of the bone lies in a deep groove on the inner surface of the quadrate,

near the ventro-posterior edge of that bone, the groove extending downward and forward to the base of the articular head of the element. The inferior end of the symplectic is pointed with cartilage. The internal surface of the bone lies flush with the internal surface of the quadrate. The external surface of its dorsal end lies flush with the external surface of the metapterygoid. The line of cartilage that edges the latter bone fits into a groove on the anterior edge of the symplectic, the mesial edge of this groove being produced as a flat process, which overlaps internally the strip of cartilage and also the hind edge of the metapterygoid beyond it.

Between the hind edge of the dorsal end of the symplectic and the anterior edge of the dorsal end of the postero-dorsal process of the quadrate, there is a space, which transmits the ramus mandibularis externus facialis from the outer surface of the hyomandibulo-symplectic to the inner surface of the palato-quadrate. Between the hind edge of the remaining, ventral portion of the symplectic and the hind edge of the groove of the quadrate in which it lies, there is a narrow space, which forms a channel in which the mandibularis externus facialis lies in the beginning of its course along the inner surface of the palato-quadrate. The mandibularis internus facialis reaches the inner surface of the palato-quadrate through a canal (*miffr*, Fig. 36) that lies between the anterior edge of the symplectic and the adjoining portions of the metapterygoid and quadrate. The symplectic thus lies between the two nerves, as it does in *Amia*.

The Interspace of Cartilage between the hyomandibular and symplectic is small, and is deeply hollowed on its postero-ventral edge by the articular facet for the epihyal. At its anterior edge it is continuous with the line of cartilage that first edges the hind edge of the metapterygoid and then lies between that bone and the quadrate. The hyomandibulo-symplectic cartilage is thus, in the adult *Scomber*, fused with the palato-quadrate, as Pollard says it is in the young of certain other teleosts (No. 60).

The Preoperculum (*POP*) is a large, somewhat crescent-shaped bone, with the hollow of the crescent directed forward and upward. The dorsal portion of its anterior edge lies in the groove on the hind edge of the hyomandibular, the bluntly pointed

dorsal end of the bone reaching to, or slightly beyond, the dorsal end of the groove. The ventral portion of its anterior edge lies in a groove on the ventro-posterior edge of the quadrate, the lower end of the preoperculum reaching almost to the base of the articular head of that bone. The middle portion of its anterior edge lies external to the hyomandibulo-symplectic, and there is here, on the internal surface of the edge of the preoperculum, a relatively deep depression. It lodges the interspace of cartilage that lies between the hyomandibular and symplectic, the adjoining ends of those two bones, the articulating end of the epihyal, and the dorsal end of the dorso-posterior process of the quadrate.

The preoperculum is firmly bound by fibrous tissue to the hyomandibular and quadrate and to the hyomandibulo-symplectic interspace of cartilage, but it is not so bound to the symplectic, a space being left between it and the latter bone for the passage of the mandibularis externus facialis.

The preoperculum is traversed its full length by the preopercular lateral canal.

The Operculum (*OP*) is a somewhat fan-shaped bone, the handle of the fan being thickened, and having, on its end, a round articular facet which articulates with the opercular process of the hyomandibular. This facet, like the corresponding facet in *Amia,* is not lined with cartilage, and no indication of cartilage could be found in any other part of the bone. *Scomber* and *Amia* thus both differ in this respect from the condition described by Gegenbaur (No. 29) in *Alepocephalus.*

Immediately external, that is, lateral, to the edge of the articular facet of the operculum there is, in *Scomber,* a strong process, which gives insertion to the tendon of the dilatator operculi muscle. The summit of this process lies approximately on a level with, and a little posterior to, the dorsal end of the preoperculum. On the internal surface of the operculum, dorso-posterior to the articular facet, there is a deep depression which forms the surface of insertion for the levator operculi. In the posterior edge of the bone, dorsal to its middle point, there is an indentation of variable form, and across it a layer of degenerate muscle fibers extend. The indentation thus seems to represent the remnant of a space that fomerly existed here between two branchiostegal rays that have fused to form a part, or all, of the operculum. The ventral edge

of the indentation forms a point, more or less sharp, near the middle of the hind edge of the bone. Ventral to this point the hind edge of the bone is concave and overlaps externally, through its entire length, the anterior edge of the suboperculum, the two bones being firmly bound together by tissue. The antero-ventral edge of the operculum is overlapped externally by, and bound to, the hind edge of the preoperculum.

The Suboperculum (*SOP*) lies with its greatest length directly nearly vertically, and forms a large part of the posterior edge of the gill cover. The dorsal portion of its anterior edge is overlapped externally by the hind edge of the ventral part of the operculum; the ventral portion of the edge being overlapped by the hind edge of the interoperculum. Between these two overlapped portions, the bone has a strong process directed dorsally and forward and ending in a sharp point. The process lies immediately antero-ventral to the antero-ventral edge of the operculum, and internal to the preoperculum, to which latter bone it is firmly bound by fibrous tissues.

The Interoperculum (*IOP*) is large and somewhat oval in shape. Its long axis lies in a nearly horizontal position. Its ventral edge is nearly straight, runs forward and slightly upward, and forms the entire ventral edge of the gill cover. Its hind end is rounded, and overlaps externally the suboperculum, to which it is firmly bound. Its dorsal edge is also rounded and is considerably overlapped externally by the ventral edge of the preoperculum, which edge is sometimes nearly parallel with the ventral edge of the interoperculum. The anterior end of the bone is bluntly pointed and is bound by ligament to the hind end of the mandible.

At the middle point, approximately, of the dorsal edge of the interoperculum, the bone is firmly bound to the ceratohyal at or near the point where the latter bone gives articulation to the epihyal. The ventral edge of the bone extends ventrally beyond the ventral edge of the ceratohyal, and is there bent inward in an abrupt curve. The two or three most dorsal branchiostegal rays lie, when at rest, enclosed in this curved surface, the interoperculum having every appearance of being simply an enlarged ceratohyal, or epihyal, ray. Whether it is the homologue of the

interoperculum of *Amia,* or of the enlarged dorsal branchiostegal ray of that fish, seems an open question. Anterior to the point where it is bound by fibrous tissue to the ceratohyal, the two bones are connected by a wide and delicate membrane which forms part of the floor of the mouth cavity. The fibrous tissues that seem to represent the ligamentum mandibulo-hyoideum, lie in the tissues along the internal surface of the bone, but, as already stated, they are not the strongly developed ligament found in *Amia,* the interoperculum itself, of *Scomber,* and the ligamentous or fibrous tissues that bind and connect it with the ceratohyal and mandible, seeming to, in part or in whole, replace the ligament.

In Gegenbaur's figure of *Alepocephalus* (No. 29, Fig. 1) the interoperculum seems to lie external to the ventral edge of the preoperculum, differing in this from *Scomber.* There is nothing in the bone in *Scomber,* more than in that of *Alepocephalus,* to solve the question raised by Gegenbaur as to the arch to which the bone primarily belongs, the hyoid or the mandibular.

The Branchiostegal Rays (*BRG*) are usually seven or eight in number. The four proximal ones are attached to the lateral surface of the ceratohyal, near its inferior edge, varying somewhat in their position along that edge. Two are always attached to the proximal ossification of the element, the third one being sometimes attached to the same ossification, sometimes to the cartilaginous interspace between that ossification and the distal one, and sometimes to the latter ossification. The fourth ray was always attached to the distal ossification, near the distal end of the wider, blade-like portion of the piece. The three or four distal rays are always attached to the mesial surface of the inferior edge of the shank of the lower ossification. The bases of all the rays are flattened and enlarged, and slight depressions on the ceratohyal usually mark their places of attachment. In the recent state the two most dorsal rays lie internal to the interoperculum, the third ray lying along the ventral edge of that bone.

The ramus hyoideus facialis lies, as in *Amia,* internal to all the branchiostegal rays.

The Truncus Arteriosus reaches the ventral surface of the basal line immediately in front of the turned-down posterior end of of the third basibranchial. There, having turned slightly upward

and then directly forward, it gives off four branches, two on each side. Both of these branches, on each side, have their origin dorsal to the U-shaped ligament that connects the hind ends of the large laminar processes of the third hypobranchials, and both turn backward and laterally, one as the afferent artery of the fourth arch, and the other as the afferent artery of the third arch. The former is given off dorsal to the latter, the artery of the fourth arch thus having its origin from the truncus distal to the artery of the third arch. The artery of the fourth arch enters at once the space enclosed in the concave surface of the distal end of the fourth ceratobranchial, and, beyond the spoon-shaped end of that bone, reaches the groove on its ventral surface. The artery of the third arch runs backward and laterally along the mesial surface of the large laminar processes of the third hypobranchial, and passing dorsal to the posterior end of the process reaches the ventral surface of the third ceratobranchial.

The truncus, after giving off these two branches on each side, continues forward, between the ventral portions of the opposing mesial surfaces of the third hypobranchials, and, near the anterior ends of those bones, gives off, on each side, the afferent artery of the second arch. This artery, on each side, turns laterally, dorsal to the anterior end of the third hypobranchial, and passing through the indentation in the postero-mesial edge of the shank of the second hypobranchial, opposite the depressed region in that surface, reaches the groove in the ventral surface of the element.

The main truncus then continues forward, between the opposing mesial surfaces of the anterior ends of the second hypobranchials, and, at the anterior ends of those elements, separates into two parts, which turn laterally and backward, one on each side, and become the afferent arteries of the first arches. Each of these arteries reaches the groove on the ventral surface of the hypobranchial of its arch by passing through the indentation in the postero-mesial edge of the element at about the middle of its length.

No indication whatever of an afferent branch to the hyoid arch or to the gill cover could be found.

The efferent artery of the first (*ea, I,* Figs. 59 and 60), as it reaches the dorsal end of its arch, lies along the antero-dorsal aspect of the suprapharyngeal process of the epibranchial of its arch, immediately anterior both to the external levator of the first arch and to the anterior division of the internal levator of the arches. When it reaches the dorsal surface of the suprapharyngobranchial of the first arch it turns sharply backward, passes ventro-internal to the trunk of the first vagus nerve, and is joined by the efferent artery of the second arch. The single trunk formed by the two arteries so united then turns postero-mesially and joins the anterior end of the dorsal aorta. The efferent artery of the second arch, as it reaches the dorsal end of its arch, lies posterior to the first vagus nerve, anterior to the external levator of the second arch, and in the angle between the anterior and posterior divisions of the internal levators of the arches.

Opposite the proximal end of the epibranchial of the fourth arch the efferent arteries of the third and fourth arches join the dorsal aorta, the two arteries there being somewhat united in a common trunk. The artery of the third arch lies anterior to the external levator of its arch and ventral to the obliquus dorsalis of the arch. The artery of the fourth arch lies dorso-posterior to all the muscles of the arches excepting only the so-called fifth externus muscle.

The efferent artery of each of the arches receives, at the point where it leaves the proximal end of the grooved dorsal surface of the epibranchial of its related arch, a branch that comes from that part of the gill of the arch that lies anterior to that point. The cut ends of these branches are seen in the figures.

The common carotid artery (*cc,* Fig. 60) arises from the dorsal surface of the efferent artery of the first arch, at the point where that artery bends sharply backward to join the efferent artery of the second arch. Running upward and forward, in front of the nervus glossopharyngeus, it soon separates into its two portions, the external and internal carotids. The former continues for a short distance the direction of the common carotid, and then turns sharply forward, and, lying ventral to the jugular vein, enters the posterior opening of the trigemino-facial chamber in the petrosal, its further course not being traced. The internal carotid turns sharply downward and then forward, and, passing mesial and

hence ventral to the dorsal end of the infrapharyngobranchial of the first arch, traverses the internal carotid foramen and enters the eye-muscle canal. There it continues forward to the anterior edge of the basisphenoid, where, lying quite close to the middle line of the head and not far from its fellow of the opposite side, it turns upward, along the anterior edge of the basisphenoid, and enters the cranial cavity, its further course not being traced. Before leaving the eye-muscle canal it has a delicate commissural connection with the arteria ophthalmica magna, as already stated.

No branch could be found corresponding to the hyo-opercularis of my descriptions of *Amia*.

The arteria hyoidea arises, as in other teleosts, from the distal, or antero-ventral end of the efferent artery of the first arch, and is a direct anterior continuation of that artery. Running forward it traverses the canal that perforates the hypohyal between its two ossifications, and reaches the external, or ventro-lateral surface of that element. There it turns almost directly backward and laterally, and runs proximally along the hyoid arch, lying in the groove that begins on the hypohyal and continues backward along the ceratohyal near its dorsal edge. When the artery arrives near the proximal end of the ceratohyal it turns upward, slightly in front of the epihyal, and enters a fold of skin that extends from the ceratohyal to the inner surface of the palato-quadrate arch. Traversing this fold it enters the slit-like opening that is found between the hind edge of the symplectic and the anterior edges of the preoperculum and the dorso-posterior process of the quadrate, and, traversing it, reaches the outer surface of the adjoining ends of the symplectic and hyomandibular. There it sends a branch to the deeper part of the adductor mandibulæ muscle, and then traverses the opening between the anterior edge of the hyomandibular and the hind edge of the metapterygoid, and reaches the inner surface of the hyomandibular. There it runs upward, between the hyomandibular and the overlapping posterior process of the metapterygoid, and reaches and enters, as its afferent artery, the anterior end of the opercular demibranch.

From the anterior end of the opercular demibranch the efferent artery of that structure arises, and, as the arteria ophthalmica magna, runs forward along the lateral surface of the skull and

enters the eyeball. As it passes across the outer edge of the orbital opening of the eye-muscle canal it has, as in *Amia,* and as already stated, a short and delicate commissural connection with the internal carotid.

The arterial connections of the demibranch of *Scomber* are thus, so far as they were traced, exactly similar to those of *Salmo,* as given by Maurer (No. 45, p. 231, 243), excepting in that the efferent artery of the demibranch in *Scomber* has a commissural connection with the internal carotid not found by Maurer in *Salmo,* and that the arteria hyoidea passes upward in front of the hyomandibular instead of traversing it. The connections are also exactly the same as those in 12 mm. larvæ of *Amia,* as will be fully set forth in a work I have now in progress and that will undoubtedly be published before the present one.

It is to be noted that the dorsal end of the arteria hyoidea of *Scomber* lies between two posterior processes of the metapterygoid, in what might be considered as a grooved portion of the hind edge of that bone; that is, it has to the metapterygoid what might be considered as the relation of a branchial artery to its arch.

5. Mandibular and Palatine Arches.

The palato-quadrate apparatus of *Scomber* contains five bony elements, the mandible three. In the palato-quadrate three independent remnants of cartilage are found, in addition to three terminal cartilaginous caps; in the mandible a rod of cartilage, representing Meckel's cartilage, and one articular cap.

The Metapterygoid (*MP*) is somewhat triangular in shape, with one convex edge, one concave one, and one that has both convex and cancave portions. The convex edge of the piece forms its inferior edge, and is everywhere bounded by the posterior cartilaginous remnant of the apparatus. The concave edge is presented antero-dorsally; the third edge of the piece being presented posteriorly, its dorsal portion being convex, and its ventral portion concave. These last two edges of the element form with each other a sharp angle, the dorsal end of the bone here curving upward and forward and tapering to a point which is always capped with cartilage. This part of the element lies external to the thin, anterior portion of the hyomandibular. Its posterior edge

abuts against and is closely and firmly bound to the anterior surface of the rod-like body of the hyomandibular, but its inner surface does not touch the outer surface of the thin, anterior part of the latter bone, a narrow space being left, into which fibers of the levator arcus palatini pass. This space between the two bones is also traversed by the dorsal end of the arteria hyoidea. From the inner surface of this part of the bone, a little below its dorsal end, a strong process arises. It projects almost directly backward, lies closely against the inner surface of the rod-like part of the hyomandibular, and, behind that bone, slightly overlaps the anterior edge of the inner surface of the preoperculum. This process and the dorsal portion of the metapterygoid, lying respectively against the inner and the outer surface of the hyomandibular, hold that bone firmly and immovably between them. The hind edge of the metapterygoid is thus here, in a manner, grooved, and as the groove lodges an artery, the arteria hyoidea, it may be that this part of the metapterygoid corresponds to the grooved dorsal surface of the proximal elements of the other arches, as already stated.

The dorsal end of the metapterygoid seems, from its relation to the levator arcus palatini, and the fact of its being capped with cartilage, to correspond to the so-called dorsal process, or metapterygoid process, of the metapterygoid of *Amia*.

The inferior end of the hind edge of the metapterygoid abuts against the inferior end of the hyomandibular, and against the interspace of cartilage between that end and the dorsal end of the symplectic. Between this postero-inferior corner of the metapterygoid and the posterior process near its dorsal end, the hind edge of the bone does not touch the hyomandibular, a relatively large slit being left between the two bones. Through this slit, as already stated, the dorsal end of the arteria hyoidea passes inward and upward from the outer to the inner surface of the palato-quadrate arch.

The inferior edge of the metapterygoid has three regions or portions. One is directed backward and downward, one downward and somewhat forward, and one forward and somewhat downward. The middle one of the three portions is slightly concave, is concentric with the superior edge of the quadrate, and, in large fishes, is separated from that edge by only a narrow line

of cartilage. This line of cartilage is continued backward and upward along the posterior portion of the inferior edge of the metapterygoid, and, at its dorsal end, is continuous with the interspace of cartilage that lies between the hyomandibular and symplectic. Ventral to that interspace the line of cartilage fits into a groove on the antero-dorsal edge of the symplectic, the cartilage and bone here being simply contiguous, and not continuous one with the other. Anteriorly the line of cartilage that bounds the metapterygoid becomes enlarged into a somewhat trapezoidal interspace, which lies between the metapterygoid dorso-posteriorly, the quadrate ventro-posteriorly, the ectopterygoid ventro-anteriorly and the entopterygoid dorso-anteriorly.

The concave dorso-anterior edge of the metapterygoid is somewhat thickened, and has a more or less pronounced groove running obliquely across it from the outer surface of the bone backward to its inner surface. The groove forms the surface of insertion of the adductor arcus palatini. The outer surface of the bone, immediately postero-ventral to its dorso-anterior edge, is somewhat concave.

The Quadrate (*Q*) is, in shape, the sector of a circle the center of which lies at the inferior end of the bone. This latter end of the bone is enlarged, and presents, antero-ventrally, an articular surface which is convex in a longitudinal direction and concave transversely. It is lined with cartilage and articulates with a corresponding surface on the dorsal surface of the hind edge of the articular. Starting from this articular head, and running upward and backward near the ventro-posterior edge of the quadrate, there is a thickened portion, grooved on its inner surface, and often, but not always, strongly raised and convex on its outer surface. The dorsal end of this thickened portion, posterior to the groove on its inner surface, is continued dorso-posteriorly, beyond the body of the bone, as a strong process, the base of which may adjoin, in part, the cartilaginous line that separates the quadrate and metapterygoid. The dorsal end of this process is pointed, lies in the depression on the inner surface of the anterior edge of the preoperculum, and is covered or capped with what seemed, in certain specimens, to be simply fibrous tissue, but in others to be cartilage.

The groove on the inner surface of the quadrate lodges the symplectic, but, as already stated, it is not entirely filled by that bone, a narrow space being left between the symplectic and the anterior edge of the dorso-posterior process of the quadrate. This space transmits the ramus mandibularis externus facialis from the outer to the inner surface of the palato-quadrate arch; and the arteria hyoidea in the contrary direction. A small canal between the anterior edge of the symplectic and the adjoining part of the quadrate, in the angle between the body of the latter bone and the base of its dorso-posterior process, transmits the ramus mandibularis internus facialis from the outer to the inner surface of the arch.

The hind edge of the quadrate, posterior to the groove that lodges the symplectic, projects posteriorly as a flat process that lies in the level of the mesial surface of the element. The dorso-posterior process of the quadrate is a dorsal continuation of this flat process. Lateral, or superficial, to the flat process, the hind edge of the bone is slightly grooved. This groove lodges the anterior edge of the ventral end of the preoperculum, the two bones being firmly bound together.

Dorsally the quadrate is separated from the ventral edge of the metapterygoid by the line of cartilage already described, and antero-dorsally it bounds the interspace of cartilage in front of the latter bone. Its ventro-anterior edge is bevelled and fits against the outer surface of the hind edge of a part of the ectopterygoid.

The Ectopterygoid (*ECP*) is a somewhat Y-shaped bone, the shank of the Y forming the anterior end of the bone and lying in a nearly horizontal position. This shank is, in transverse section, convex on its antero-inferior edge and concave on its superior edge, the concavity becoming more pronounced toward the foot of the shank, that is toward the anterior end of the bone, the bone there being thin, and looking like a delicate gouge. The arms of the Y are flat and pointed, and lie at more than a right angle to each other. The lower arm is much the stouter of the two, is directed downward and backward, and extends nearly the full length of the antero-ventral edge of the quadrate. Its posterior edge is bevelled to receive the anterior edge of the latter bone, which it overlaps internally. The dorsal arm of the Y is directed backward and slightly upward,

and is only about one half as thick as the ventral arm. It lies along the inner surface of the cartilaginous interspace in front of the metapterygoid, and then along the inner surface of the latter bone, in a shallow but sharply marked triangular depression. The shank of the bone extends forward dorsal to the hind end of the palatine, lying between that bone and the large, middle cartilaginous remnant of the palato-quadrate arch.

The Entopterygoid (*ENP*) is a large, thin bone, shaped something like the bowl of a spoon. It lies in a nearly longitudinal and horizontal position, its mesial edge being free. The posterior portion of its lateral edge lies against and is firmly attached to the inner surface of the metapterygoid, concentric with and slightly below its concave dorso-anterior edge. In front of the metapterygoid the entopterygoid runs forward across the inner surface of the dorsal arm of the Y-shaped ectopterygoid; then along the mesial edge of the dorsal surface of the shank of the latter bone; and then along the corresponding edge of the palatine. Opposite the interspace of cartilage in front of the metapterygoid, the lateral edge of the entopterygoid is turned downward so that its lateral surface rests against the mesial surface of the cartilage. At its anterior end the bone lies against the ventro-mesial surface of the large middle cartilaginous remnant of the arch.

The Palatine (*P*) has a long pointed hind end, which rests against the ventral surface of the large middle cartilaginous remnant of the arch, and, posterior to that cartilage, against the ventral surface of the shank of the ectopterygoid. It bears, on part of its mesial edge, the anterior part of the lateral edge of the entopterygoid. That part of the bone that lies anterior to this long posterior end is stout and broad, and is united by synchondrosis with the anterior end of the large middle cartilaginous remnant of the apparatus. Its anterior end curves downward, and lies, at first, dorsal to, and then external to, the anterior end of the maxillary bone. Its anterior end is capped with cartilage and articulates with the maxillary in a depression on the outer surface of the latter bone. Immediately posterior to the base of this anterior curved end of the palatine, on the dorsal surface of the bone, there is a slightly raised transverse facet of cartilage which may or may not lie on a slight eminence in the bone. It forms the

anterior cartilaginous remnant of the arch, and articulates with the cartilage that caps the ventro-lateral, or septo-maxillary, process of the ethmoid. The anterior edge of the facet always projects upward as a short process, and gives insertion to part of the articular fibrous tissue that binds the palatine to the skull.

Along the ventral edge of the palatine there is a tall, flat, thin ridge, or fin of bone, the ventral edge of which is lined with small sharp teeth. This fin of bone occupies about the middle three fifths of the length of the palatine, is tallest at or near its anterior end and from there diminishes gradually in length until it disappears, at its posterior end, in the general level of the ventral surface of the bone.

The large middle cartilaginous remnant of the palato-quadrate arch is a flat block of cartilage with a straight, transverse, anterior end, and a shelving posterior end. The dorsal edge of the latter end rises as a flat, transverse, pointed process, which is directed upward, forward and laterally. It forms the hind edge of a large but shallow transverse articular surface, which is held up against the ventral edge of the postero-ventral arm of the preorbital ossification by a strong ligament that has its insertion on the cartilaginous process. This ligament arises from the posterior surface of the preorbital ossification, and allows a swinging and sliding, latero-mesial motion of the palato-quadrate. The fact that this strong ligament has its insertion on a cartilaginous process, and not on bone, should be noted as indicating that the ossifications of the palato-quadrate have probably not been developed in any relation to the attachments of muscles or ligaments.

The Mandible (Figs. 4 and 35) consists of three ossifications, the articular, angular and dentary, and a cylindrical rod of cartilage representing Meckel's cartilage.

The Articular (*ART*) has a broad, straight portion, convex externally and concave internally. From the hind end of this portion two large processes arise, one projecting dorso-anteriorly and the other ventro-anteriorly, giving to the whole bone a dart-like appearance. Into the angle between the ventral process and the body of the bone the hind end of the ventral arm of the dentary fits, a space usually being left between the ventro-posterior end of the dentary and the adjoining edge of the articular. The ven-

tral edge of the body of the articular overlaps mesially the dorsal edge of the ventral arm of the dentary, its anterior end extending forward beyond the base of the arm of the dentary into the hollow of the bone itself. On the dorsal edge of the hind end of the articular, which end often projects backward as a sort of posterior process, there is a transverse articular surface, concave in the longitudinal direction of the bone and convex in the transverse direction. The hind edge of this surface projects upward, as a hook-like process, and fits into a corresponding recess on the hind edge of the articular head of the quadrate. The articular surface is lined with cartilage. From the anterior edge of this cartilage, on the inner surface of the bone, a slight rounded line, or sometimes simply a surface marking on the bone, runs forward, and, beyond the bases of the two large dorsal and ventral processes of the bone, becomes a slight blunt process directed forward. The flat anterior end of this process abuts against and is continuous with the hind end of Meckel's cartilage, the rounded line thus probably indicating the position of an ossified portion of the cartilage.

The articular is traversed by the posterior part of the mandibular lateral canal.

The Angular (*ANG*) is a small irregular bone that fits against the mesial surface of the ventral edge of the articular, near its hind end and immediately antero-ventral to the articular facet for the quadrate. The ventral edge of the bone usually projects downward beyond the ventral edge of the articular, and at or near its hind end it is thickened and rounded into a blunt process which gives insertion to the ligament that connects the mandible with the interoperculum. The bone lies wholly ventral to the hind end of the line that indicates the posterior continuation of Meckel's cartilage, and is not traversed by any part of the lateral canal. It occupies, approximately, the position of ossicle *a* in *Amia;* but whether it is or is not, in *Scomber,* in part, or in whole, of cartilaginous origin was not investigated.

The Dentary (*D*) is a strong, V-shaped bone, the external margins of the adjoining edges of the V being connected for a certain distance by a thin web of bone. The dorsal edge of the dorsal arm of the V is lined with a single row of small, sharp teeth. The ventral edge of the same arm is grooved, the anterior end of

the groove extending forward into the anterior end of the bone and there forming a triangular recess, which lodges the anterior end of Meckel's cartilage. The anterior end of the bone turns slightly mesially, and articulates with its fellow of the opposite side by a straight and roughened edge which is not capped with cartilage. On the mesial surface of the anterior end of the bone there is a longitudinal depression which marks the line of insertion of the intermandibularis.

The ventral arm of the dentary is traversed by the anterior part of the mandibular lateral canal.

Meckel's Cartilage (*M*) is a cylindrical rod of cartilage which extends directly forward from the blunt process at the angle between the dorsal and ventral processes of the head of the articular into the angular space between the two arms of the V-shaped dentary. Its anterior end penetrates the dentary, and can be traced a considerable distance toward the anterior end of the bone. Beyond its anterior end the line of the cartilage is continued forward toward the tip of the mandible by a special portion of the bone, which can often be separated in dissection as a separate and somewhat spongy or porous rod. The cartilage lies, in its free portion, against the mesial surface of the longitudinal portion of the articular, and upon the dorsal surface of the ventral arm of the dentary.

4. *Shoulder Girdle, Sternum and Pectoral Fin.*

The Sternum (*S*, Fig. 49) is a long flat bone lying in the median plane of the body, between the two sternohyoid muscles. Its dorsal edge is nearly straight, its ventral edge convex. At its hind end it gives insertion to ligaments that connect it loosely with the ventro-anterior ends of the clavicles. At its anterior end it gives origin to two ligaments, each of which has its insertion on the hypohyal of its own side of the head, on an eminence, already described, near the ventral edge of the anterior end of the element. The dorsal edge of the bone is thin; the ventral edge is considerably thickened, lies immediately internal to the integuments of the ventral surface of the head, and has a median V-shaped groove extending longitudinally its full length.

The Clavicle (*CL*, Figs. 45–51) is a long, curved bone, the ventral and larger part of which may be described as a long flat oval and pointed piece of bone folded back upon itself, along its longest axis, in such a way as to form, on its posterior aspect, a deep angular groove, of about 70°, with a rounded bottom. That part of the bone that forms the mesial wall of this groove is directed almost directly backward. It is thinner and less strong than the part that forms the antero-lateral wall, which is directed outward and backward. The hind edge of the mesial wall is deeply cut out, near its dorsal end, and there forms part of the bounding wall of a large opening. This ventral, grooved part of the clavicle extends almost to the dorsal end of the bone; and opposite the dorsal end of the groove there is usually, on the lateral edge of the antero-lateral wall of the bone, which is here greatly reduced in height, a slight eminence which seems to mark the dorsal end of some definite morphological part of the bone. The ventral end of the supraclavicular, in its natural position, lies slightly above this eminence, and the two bones are here connected by fibrous tissues. The lateral edge of the clavicle, ventral to this point, is thickened and grooved for a certain distance, the groove giving attachment to the dermal tissues of the region.

That part of the clavicle that lies dorsal to its grooved part has much the appearance of a separate formation, added to and fused with the main ventral part. The dorsal edge of this apparently added portion is curved, and is, near its anterior end, deeply notched, the notch lodging the occipito-supraclavicular ligament as that ligament passes outward to its insertion on the inner surface of the supraclavicular. That portion of this part of the bone that lies in front of the notch, forms a short stout process directed upward and forward. It forms the actual proximal end of the clavicle, bears on its end a slender spine-like process directed dorsally or dorsally and backward, and lies internal to the ventral end of the thickened part of the supraclavicular. The part posterior to the notch forms a relatively large, flat process, which projects almost directly backward and is slightly convex on its outer, and concave on its inner surface. Its dorsal edge is strongly rounded, and presents a large, shallow, rounded indentation, which

gives to the edge a scalloped appearance. The edge is thin, and presents slight concentric markings similar to those found on the scales of the body. The ventral edge of the process is thickened, is slightly concave, and lies in a nearly horizontal position. The anterior, or basal half of this ventral edge of the process is connected by a strong web of bone with the dorsal part of the mesial wall of the grooved part of the bone, and so forms a continuation of that wall. A similar web of bone is found along the mesial edge of the proximal process of the bone. It is directed mesially, and is continued downward a short distance along the anterior edge of the grooved part of the bone. These two webs of bone, and the two dorsal processes with which they are associated, together form a part of the clavicle which presents internally a large concave surface. In the bottom of this concavity there is a depressed region bounded by a narrow curved wall, or surface, which lies perpendicular to the rest of the surface of the concavity, and nearly concentric with the anterior and dorsal edges of this part of the bone. It lodges, and forms the surface of attachment of, the dorsal part of the primary shoulder girdle. The dorsal end of the narrow wall that marks the limits of this surface extends backward to about one half the length of the large posterior process of the clavicle, varying in length in different specimens. Its ventral end extends downward to the dorsal edge of the large opening, already referred to, in the mesial wall of the grooved part of the bone. The ventral part of the posterior edge of the latter opening is formed by a pointed process of the clavicle which gives attachment, along its lateral surface, to the ventral end of the primary girdle.

The dorsal part of the clavicle is relatively straight. In its ventral third it curves somewhat sharply forward, and its pointed distal end, which is directed forward and mesially, lies close to and is firmly bound by fibrous tissue to the corresponding end of the bone of the opposite side of the head. The lateral and mesial surfaces of the bone here both give origin to parts of the sternohyoideus; the groove of the bone lodging certain of the muscles of the pectoral fin and parts of the muscles of the trunk. The extreme ventro-anterior end of the clavicle gives origin to a ligament that has its insertion on the hind end of the sternum. The

hind end of the sternum, in its natural position, lies slightly dorsal to the anterior end of the clavicle.

Associated with the clavicle there are two accessory bones. The smaller of the two is oblong in shape, with a convex external and a concave internal surface. Its superior edge is thin and rounded, with concentric scale-like markings. Its inferior edge is thickened and nearly straight. The bone is bound by fibrous tissue to the inner surface of the postero-dorsal process of the clavicle, and is so placed that its dorso-anterior end fills the scalloped indentation in the dorsal edge of that process. The larger accessory bone is somewhat shield-shaped in outline, its postero-ventral end being prolonged in a long and slender spine-like process. At about the dorsal third of its nearly straight antero-dorsal edge there is another process, also long and slender but much less so than the postero-ventral one. It lies along and is bound by fibrous tissue to the inner surface of the anterior accessory bone, near its ventral edge. This larger accessory bone is the oropterygium of certain authors.

The Primary Shoulder-Girdle contains six ossifications, all of which are surrounded, and united more or less completely with each other, by narrow lines of cartilage. The two largest of these six ossifications are the scapulare and procoracoid of Gegenbaur's descriptions (No. 28). The four smaller ones are the second, third, fourth and fifth basal, or carpal, bones of the same descriptions.

The Scapulare (*SC*) and Procoracoid (*PC*), which are separated from each other by only a narrow line of cartilage, together form a flat triangular or trapezoidal piece. The ventro-posterior edge of this piece is formed entirely by the procoracoid, and is free and not lined with cartilage. The anterior edge is formed by both the scapulare and the procoracoid, and is attached, throughout its entire length, to the clavicle, excepting only in that part that lies opposite the large opening cut out of the hind edge of the mesial plate of the grooved part of the latter bone. Opposite that opening the opposing edge of the procoracoid is also deeply cut out, a large oval fenestra thus being formed, which, in the natural state, is closed by membrane. Dorsal to this fenestra the articulating edge of the procoracoid, and dorsal to that bone the corresponding edge of the scapulare, are lined with cartilage.

Ventral to the fenestra, the procoracoid, which here alone articulates with the clavicle, is not so lined, excepting only at the extreme ventral tip of the bone which ends in a small bit of cartilage. Dorsal to the fenestra the scapulare and procoracoid articulate with the inner, or mesial surface of the mesial plate of the clavicle; ventral to the fenestra the procoracoid articulates with the outer, or lateral surface of the same plate.

The dorso-posterior edge of the united scapulare and procoracoid has a long rectangular piece cut out of it, the cut being considerably deeper at its ventro-posterior than at its dorso-anterior end. In the space thus cut out of the scapulare and procoracoid lie the four basal bones, their free dorso-posterior edges lying on a level with the corresponding and adjacent portions of the scapulare and procoracoid. The excision is lined with cartilage its full length, excepting only in that part that lies between the posterior edge of the posterior basal bone and the adjoining edge of the procoracoid. Cartilage also extends outward between the basal bones, and entirely around the anterior basal bone. Anterior to the anterior basal bone the edge of the scapulare is capped for a short distance with cartilage, and, anterior to this cap, the bone is cut away. A part of the edge of the scapulare is thus left which projects as a rectangular eminence and looks like an anterior continuation of the line of basal bones. In two of the three specimens examined this eminence gave articulation to the three anterior dermal rays of the pectoral fin; in the third specimen the articulation of the rays was as shown in the accompanying figures.

The scapulare is pierced by a foramen of variable size and position which gives passage to the nervus pterygialis and doubtless also to the artery that supplies the fin, though this was not traced.

The four basal bones are sub-rectangular pieces the adjoining edges of which are cut out in the middle so as to form three small and nearly circular openings. Between the posterior edge of the posterior bone and the adjoining edge of the procoracoid there is a similar but larger and more oval opening. Between the anterior edge of the anterior basal bone and the adjoining process of the scapulare there is no opening. The posterior basal bone lies entirely opposite the procoracoid; the next anterior one lies opposite the cartilaginous line between the procoracoid and scapulare; and the two anterior ones opposite the scapulare.

The number of dermal rays in the pectoral fin varied, in the different specimens examined, from seventeen to twenty. In two specimens, in which there were eighteen rays, three of them articulated directly with the scapulare; two articulated with the anterior basal bone; three with the next posterior bone; one between that bone and the third bone; four with the third bone; and five with the fourth bone. In one specimen, in which there were twenty rays, they articulated with the basal bones as shown in the figures.

The rays are all usually formed of two bones, a mesial and a lateral one, but the antero-dorsal, or propterygial ray was sometimes formed of a single bone. The two bones, each representing half a ray, are usually separated by a line of tissue which at the same time binds the bones together. They are easily separated one from the other.

The mesial half of the propterygial ray (Fig. 48) has an enlarged proximal end, from which a stout process projects backward, downward and mesially. This process gives insertion to one of the tendons of the ventral one of the two adductor profundus muscles of the fin, and to a tendon that extends forward and upward from the ray to the mesial surface of the dorso-posterior process of the dorsal end of the clavicle. The anterior surface of the proximal end of the mesial half of the ray gives insertion to the large tendon of the levator muscle of the fin. The lateral half of the ray did not, in the specimen examined, give insertion to any part of the muscles of the fin. The anterior surface of the proximal end of the entire ray is convex; the posterior surface concave.

In the rays that follow the propterygial one, the proximal end of each of the two bones that form the ray is produced backward and downward as a process, the ends of the bones here spreading and leaving a V-shaped angle between them. This angle is filled with tough tissue which rests upon the articular edge of the primary girdle. On the lateral half-ray, near the end of its produced, process-like proximal end, there is a large eminence which gives insertion to two tendons, one belonging to the abductor superficialis muscles of the fin, and the other to the abductor profundus. On the mesial half-ray a similar eminence

gives insertion to a tendon of the ventral one of the two adductor profundus muscles. Both of these eminences are often so strongly developed that they form the true end of the ray. On the mesial half-ray, at or slightly distal to the base of its proximal process, there is a second eminence. On the first five rays, approximately, it gives insertion to a tendon of the dorsal one of the two adductor profundus muscles, while on the remaining rays it gives insertion to a tendon of the adductor superficialis muscle. The rays are bound by strong fibrous tissues to the primary girdle, in such a manner that a somewhat limited movement is permitted them in the plane of the girdle, and a much more extended movement at right angles to that plane.

Lateral Line System.

The lateral line system of *Scomber* differs from that of *Amia* in that there are, apparently, fewer lines of surface pit organs, and that there is no connection whatever between the canals of the two sides of the head. The pit lines that are apparently wanting, as compared with *Amia,* are those found on the cheek, mandible and gular plate of the latter fish. The antorbital commissural canal, formed, in *Amia,* by a large and important anterior continuation of the infraorbital canal of each side of the head, and found in certain other fishes, in whole or in part, as a line of surface pit organs, has apparently been developed, in *Scomber,* as a short canal, on each side of the head, fused with and forming the anterior end of the supraorbital canal. The posterior, supratemporal cross-commissure of *Amia* is represented on each side of the head of *Scomber* by a canal which does not meet its fellow of the opposite side in the middle line of the head. Otherwise there are no important differences in the course and disposition of the main canals. The branch canals, or dendritic systems, on the contrary, differ greatly, in that they undergo much less frequent subdivision than in *Amia,* and that the subdivisions are in many cases carried so deep that the trunk of the system disappears, leaving the branches as separate tubes arising directly and independently from the main canal. Similar subdivisions were found, in *Amia,* only

in those so-called double systems that were formed where independent main canals had fused with each other.

The descriptive terms relating to the canals, adopted, mainly from earlier writers, in my works on *Amia,* are still retained, with but few slight changes, in the present descriptions, for, until the anatomy and development of the lateral system, and of the nerves related to it, are much better and more fully known than at present, I see no advantage whatever to be gained in changing them. I may, however, here state that what I have called the main infraorbital canal of the head is certainly formed by the fusion of several more or less independent canals, which should, in all probability, be carefully distinguished one from the other. This will be more especially referred to in describing the canal.

The single tubes that lead primarily from a main canal, between two successive organs of that canal, to the outer surface of the head, I here call primary tubes or trunks, as in my earlier work. Where there are several such tubes resulting from the subdivision of a single primary tube, or a number of branch canals, arising from a single trunk, they are called, collectively, a peripheral canal system. These peripheral systems, and the pores that form their surface openings, always arise, so far as my experience goes, by the repeated dichotomous division of a single primary pore and tube; by the fusion and subsequent dichotomous division of two such pores and tubes, one belonging to one canal and the other to another; or by a similar fusion and subsequent division of certain parts of two adjoining peripheral systems. In each of the two latter cases I have called the resulting system a double system. The systems at the ends of a principal canal are called terminal systems, or terminal tubes and pores.

1. *Main Infraorbital Canal.*

The main infraorbital canal of *Scomber* begins, anteriorly, at a surface pore which lies considerably below and a little behind the single nasal aperture of the fish, and a little in front of the anterior edge of the gelatine-like substance that surrounds and partly covers the eye. The canal leading inward from this pore enters the lachrymal near its antero-dorsal edge, and runs backward and

downward through that bone, leaving it near the hind end of its long postero-dorsal edge. It then enters the suborbital bone and runs nearly directly backward through it, entering the bone on its external surface, some little distance beyond its anterior edge, and usually leaving it on the same surface some little distance anterior to the posterior edge of the bone. It then lies in the skin for a short distance, turns sharply upward and enters the lower bone of the postorbital series. Turning backward and upward in this bone it leaves it at its upper edge, and then traverses the other postorbital bones and the postfrontal, running at first upward, or even upward and forward, then upward and backward, and then upward and forward, around the hind edge of the orbit.

At the dorsal edge of the postfrontal bone the canal enters and traverses the deeper layers of the strip of skin that lies between the postfrontal and the outer edge of that ridge of the frontal and squamosal that forms the boundary between the dilatator and temporal grooves. Having reached that ridge of bone it turns sharply backward, and lies for a short distance in an open groove on the outer edge of the ridge, the groove lying at first in the frontal and then between the adjoining, overlapping edges of the frontal and squamosal. At the hind end of the groove the canal turns inward and backward between the overlapping frontal and squamosal, and then enters that part of the ridge that is formed by the squamosal alone, not having entered the frontal in any part. Running backward in a curved line it reaches the deeper parts of the ridge, and then, turning outward, issues from the bone at the enlarged hind end of the ridge. There it enters the anterior end of the lateral arm of the Y-shaped extrascapular, traverses that arm, and then the shank of the bone, then the body of the suprascapular, and finally the supraclavicular, lying in a nearly horizontal position in this part of its course. On leaving the supraclavicular it enters the first scale of the lateral line and becomes the lateral canal of the body.

While lying in the open groove in the ridge that separates the dilatator and temporal grooves the canal forms an anastomosis with the supraorbital canal; near the hind end of the same ridge it is joined by and anastomoses with the dorsal end of the preopercular canal; and at the anterior end of the shank of the extra-

scapular it gives off, or is joined by, the supratemporal commissure.

As the canal traverses the lachrymal it has a wavy course and gives off several branch canals, all of which run downward and forward, downward, or downward and backward from the main canal. So far as can be judged from dissections of the adult alone these branch canals or tubes form parts of three dendritic systems, making, with the anterior terminal system of the line, four systems in all in the lachrymal.

The anterior, terminal system of the line was usually represented by a single tube and pore, but in certain specimens the first tube posterior to this terminal one could with almost equal reason be considered either as a part of the terminal system or as a part of the next adjoining one. The second system was usually found as a single trunk which soon separated into two tubes, each of which opened on the external surface by a single pore. This system was, however, sometimes found as a single tube, sometimes as two separate tubes with contiguous bases, and, in the specimen shown in Fig. 3, it seemed to be represented by three tubes and pores. What seemed to be the third system of the line was usually represented by three separate tubes and pores, the two anterior tubes being often united at their bases. In some fishes it was represented by two tubes only. The fourth system was usually found as two tubes somewhat widely separated.

The fifth system of the line is a single tube given off from the main canal as it passes through the skin between the lachrymal and suborbital bones. It is directed upward, or upward and backward from the main canal, and is the only tube in the suborbital part of the canal that is given off on its orbital side. The sixth system is a single tube directed backward, or backward and upward from the canal as it passes from the suborbital bone to the lowest bone of the postorbital series.

The seventh system is a single tube, or two tubes, given off near the middle of the lowest bone of the postorbital series; and the eighth system is a single tube lying in the second bone of the postorbital series near its ventral edge. The tubes of both of these systems leave the main canal internal to the ventral portion of the gelatine-like mass that surrounds the eye, and run down-

ward and backward to the ventral edge of the mass, where they each end in a single pore. Either the seventh or eighth system was wanting in the specimen shown in Figure 3.

Between the eighth system and the lower edge of the postfrontal bone there is no dendritic system. The innervation, however, shows that two systems at least, Nos. 9 and 10 of the line, should have been normally developed in this part of the canal, and, in one specimen, a short closed tube was found representing one of them. Both systems have doubtless disappeared as a result of the closing of their surface openings by the gelatine-like mass that surrounds the eye, the tubes thus having been rendered functionless. The associated nerves and organs were, however, retained. One of these nerves enters the second bone of the postorbital series, counting from below, the other the third, those two bones also lodging the related organs. In the small and delicate scale-like bones between the third postorbital bone and the postfrontal no indication of a nerve, organ, or dendritic system was found in any specimen.

System No. 11, the next system in the line, was represented, in all the specimens examined, by three tubes and pores. Two of these three tubes always left the main canal as it traversed the postfrontal and the dermal tissues dorsal to it, the other one arising at the point where the canal enters the open groove between the edges of the frontal and squamosal. The first two tubes are directed backward and slightly upward, one lying partly in the postfrontal, and the other wholly in the dermal tissues superficial to that bone. The third tube runs laterally and downward from the orbital surface of the canal, at the point where it is joined by the supraorbital canal. The external openings of all three tubes lie slightly dorsal to the gelatine-like mass around the eye. Although the development of this system was not traced from younger stages upward, it is sufficiently evident that it is a double system formed by the fusion of system 11 infraorbital with system 7 supraorbital, and that it corresponds to the double system 15 infraorbital—7 supraorbital of *Amia*. In the subdivision of this double system, in *Amia*, the separation of the two parts took place along the squamosal part of the line; in *Scomber* it takes place along the suborbital part. A variation in the tubes and canals,

found at this point in certain specimens, will be referred to in describing the supraorbital canal.

The next system on the main infraorbital line is No. 12. It is represented by a single tube and pore, the tube arising from the main canal as it traverses the squamosal, and running outward and forward in the ridge of that bone.

The next system, No. 13, lies near the hind end of the squamosal, and has fused with the terminal system, No. 11, of the preoperculo-mandibular canal to form a double system. It is represented by two tubes and pores. One of these tubes arises from the main infraorbital canal at or near the point where it is joined by the preopercular canal. The other arises from that part of the latter canal that lies in the skin between the squamosal and the upper end of the preoperculum. The first tube lies in the ridge of the squamosal, issuing from the bone by the anterior one of three openings in the thickened hind end of the ridge. By the second hole in this thickened hind end of the bone the preopercular canal enters the squamosal to join the main infraorbital canal. By the third hole the main infraorbital canal leaves the squamosal to enter the extrascapular. The double system, 13 infraorbital—11 preoperculo-mandibular of *Scomber,* corresponds to system 17 infraorbital—17 preoperculo-mandibular of *Amia.* In Figs. 1 and 2 the tubes and pores are shown in somewhat different relations to each other and to the main canal, the two figures representing arrangements found in different specimens.

The next system of the line, No. 14, is usually represented by two tubes and pores, the tubes issuing from the main canal as it traverses the lateral arm of the extrascapular. In Fig. 5 four holes are shown in this arm of the bone. It is however probable that they were not all traversed by sensory tubes, the bone here being exceedingly delicate, and certain of the holes probably simply representing places where the bone has been incompletely formed.

System No. 15 is represented by a single tube and pore, the tube leaving the main canal as it passes from the extrascapular to the suprascapular.

System No. 16 is found as one or two tubes and pores, the tubes arising from the main canal near the middle of the body of the suprascapular.

System No. 17 is a single tube and pore, the tube leaving the main canal as it passes from the suprascapular to the supraclavicular, or from near the hind edge of the former bone.

System No. 18 is a single tube arising from the canal as it passes from the supraclavicular into the first scale of the lateral line. It is accordingly also the first system of the lateral line of the body.

There are thus, normally, so far as can be judged from dissection of the adult, eighteen dendritic systems and seventeen sense organs along the main infraorbital canal of *Scomber*. Two of the eighteen dendritic systems are either rudimentary or have wholly disappeared; a third one is the anterior terminal tube of the line; and a fourth one a tube formed where the canal of the head joins the anterior end of the lateral canal of the body.

The lateral canal of the body, in its anterior portion, where it alone was examined, traverses each successive scale of the lateral line, entering each scale on its external surface and leaving it on its internal surface, as in *Amia*. At the hind end of the section of canal enclosed in each scale a single tube is sent to the outer surface, where it opens by a single pore.

The seventeen sense organs of the main infraorbital line are distributed as follows: four in the lachrymal, one in the suborbital bone, two in the first postorbital, one in the second postorbital, one in the third postorbital, one in the postfrontal, three in the squamosal, one in the extrascapular, two in the suprascapular, and one in the supraclavicular. These organs, the canal itself, and the various dendritic systems are all shown diagrammatically in Fig. 1*a*. The first twelve organs of the line are all innervated by branches of the nervus facialis. The next three organs are innervated by branches of a nerve that issues from the cranial cavity by the vagus foramen and that is, in so far as macroscopical examination could show, simply the most anterior branch of the nervus lineæ lateralis. The last two organs of the line are innervated by the second and third branches of the nervus lineæ lateralis. No organ of the line is innervated by a branch that issues from the skull with the nervus glossopharyngeus, but, as the posterior one of the three squamosal organs of *Scomber* is certainly the homologue of the correspondingly situated organ in *Amia*, it is

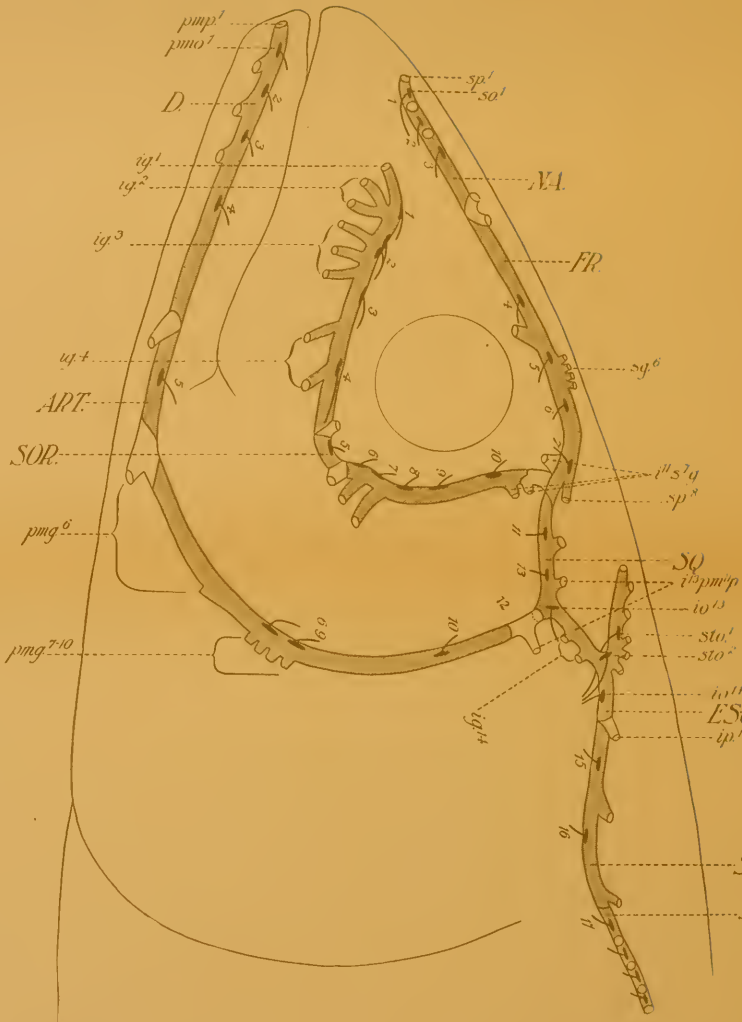

Fig. 1a. Diagrammatic side view of the head of *Scomber*, showing the lateral sensory canals, and the sense organs in those canals. × 4.

evident that the branches that innervate the organs in the two fishes must also be homologous. This I have already had occasion to refer to (No. 8), and it will be further discussed in describing the nerves. In *Polypterus* the arrangement, as deduced from Pollard's descriptions (No. 58, p. 397), is apparently the same as it is in *Amia,* excepting that the squamosal of *Polypterus* is fused with the parietal. In *Menidia* the first organ posterior to the preoperculo-mandibular canal is, according to Herrick (No. 36), innervated in the same way as the posterior squamosal organ of *Scomber* is, but whether this organ, in *Menidia,* lies in the squamosal or not is not stated. In the cod Cole (No. 16) says this organ is absent, but, as already stated in an earlier work (No. 8), it may be found to be represented in the organ called by him organ No. 3 of the lateralis canal.

The first twelve organs of the line in *Scomber* are separated, by their innervation, into three groups. The first group contains the first five organs of the line, four of which lie in the lachrymal and one in the suborbital bone. The second group contains the four organs that lie in the bones of the postorbital series. The third group contains the one organ that lies in the postfrontal and two of those that lie in the squamosal. The organs of the first two groups are innervated by branches of the buccalis facialis; the organs of the third group by branches of the oticus facialis.

Between the first and second groups of organs the main canal changes abruptly in direction, and the anterior organs of each group lie much closer to each other than the posterior ones. This is readily seen in the disposition of the dendritic systems, and, taken together with the manner of innervation, seems to indicate some independence in the development of the two parts of the canal. A similar independence of development was indicated by a similar grouping and innervation of the organs in *Amia* (No. 2, p. 514), but there was, in *Amia,* another group of infraorbital organs lying anterior to those found in *Scomber.* These anterior organs in *Amia* were four in number, on each side of the head, and formed the anterior cross commissure of the lateral system. Two of the organs lay in the antorbital bone and two in the corresponding half of the median ethmoid bone. Two of these organs, and possibly also the bone that encloses them, are appa-

rently wholly wanting in *Scomber;* but there is nothing to definitely indicate whether it is the ethmoidal organs and bone that have disappeared, or the antorbital ones. The other two organs of *Amia,* whichever two it may be, are certainly represented in the first organ of the supraorbital canal of *Scomber,* that organ being innervated by a branch that arises from the fused buccalis facialis and maxillaris superior trigemini, as will be fully described in describing those nerves. In *Gadus* this supraorbital organ of *Scomber* is apparently represented in a pit organ said by Cole to lie opposite the anterior extremity of sense organ 1 supraorbital. The course of the nerve that innervates this pit organ in *Gadus* seems to indicate, as I have already had occasion to state (No. 8, p. 366), that the single organ in *Gadus* represents the two canal organs in the ethmoid of *Amia.* The shape of that part of the nasal bone of *Scomber* that lodges the buccalis supraorbital organ, its relation to the other bones of the region, and the presence of an ascending process to the premaxillary, all indicate, on the contrary, that the anterior part of the nasal of *Scomber* is the homologue of the antorbital bone of *Amia,* the organ in the nasal bone of *Scomber* being, in that case, the homologue of the antorbital organs of *Amia.*

In *Gadus* the organs innervated by the facialis are separated by their innervation, as given by Cole, into four groups, as they are also in *Amia* and *Scomber.* Organ No. 1 forms the first one of these four groups, organs 2–6 the second, organs 7–10 the third, and organ 11 the fourth. Whether the organs assigned to the third and fourth of these groups, in these three fishes, do not, in reality, form but a single group, artificially separated into two groups because of the name oticus given to the branches that innervate certain of them, is open to question. The second and third groups, in all three fishes, seem, on the contrary, to be so definitely separated from each other by their innervation, and in *Amia* also by the manner in which they are enclosed in their canals, that there may be here an anatomical fact of some importance. They may represent, in teleosts, the two separate, ventral and dorsal, infraorbital lines of *Chimæra.*

The possibility, or even probability, of system 14 infraorbital of *Scomber* being a double and not a simple system will be discussed in describing the supratemporal commissure.

Just as I am sending this manuscript to press I have received No. 2, Vol. XV., of the Journal of Morphology, containing Cornelia M. Clapp's paper on "The Lateral Line System of *Batrachus Tau*." In this fish the first and second groups of infraorbital organs above referred to are still more definitely separated from each other than in *Amia;* and they are entirely separated from the third and fourth groups, which together form a single group. The first group is called by Clapp, as by me in *Amia*, the antorbital part of the infraorbital line; and the second group, because of its position, is called by her the maxillary branch of the same line. The bone to which this maxillary canal is related must, accordingly, be the lachrymal, or that bone plus the suborbitals; and it seems, from Clapp's Fig. 4, to have acquired articular relations with the skull.

The fibrous or semi-cartilaginous tube that encloses the temporal canal of her descriptions, and that is said to lie outside the muscles covering the squamosal and occipital bones, must represent another instance of that complete separation of the canal and membrane portions of the squamosal to which I have already referred in an earlier work (No. 9).

That the organs of the main lateral lines of the body, in *Batrachus Tau,* should be innervated by the ramus recurrens facialis, and that the supratemporal branch of the vagus should issue from the skull through a foramen in the supraoccipital bone, are such radical departures from the conditions found in *Amia* and *Scomber* that I can attempt no comparison until I have had time to further investigate the subject.

2. *Supraorbital Canal.*

The supraorbital canal begins at a pore on the dorsal surface of the snout, not far from its anterior end. The tube leading from this pore runs backward and laterally and enters the front end of the nasal bone. In that bone it runs backward, following the somewhat sigmoidal line of the bone. Having issued at the hind end of the bone it lies, at first, in an open groove on the dorsal surface of the frontal, and then enters that bone, running directly backward to a point nearly opposite the hind edge of the eye.

There it curves sharply laterally, or laterally and backward, traverses that part of the frontal that forms the floor of the anterior ends of the supratemporal and temporal grooves, and enters that part of the ridge between the temporal and dilatator grooves that is formed by the frontal bone alone. In this ridge it runs laterally and outward, and issues from the frontal on the dorso-mesial surface of the ridge, near its outer edge. There it enters the dermal tissues superficial to the ridge, and running backward and laterally, superficial to the anterior portion of the otic part of the main infraorbital canal, ends, lateral to that canal, in a single pore. It does not extend beyond the frontal into the parietal as it does in *Amia*.

The first dendritic system of the line is the anterior terminal tube and pore of the canal. The tube issues from the nasal bone near its anterior end, and the pore lies on the top of the snout, considerably in front of the single nasal aperture.

The second and third systems were, on the right side of the fish used for illustration, each represented by two tubes and pores, each tube of each system arising separately and independently from the main canal. On the left side of the same fish each of the two systems contained but a single tube and pore. All of the tubes, on both sides of the head, were directed backward and laterally from the main canal. The second system arises from the canal at the summit of the curve that forms the anterior half of the nasal bone; the third system from the summit of the curve that forms its posterior half.

The fourth system of the line lies between the nasal and frontal bones, arising from that part of the main canal that lies in the open groove on the dorsal surface of the frontal, immediately posterior to the nasal. On one side of the fish used for illustration it was represented by two tubes arising close together from the main canal; on the other side by two tubes arising some little distance apart. One tube in each case ran laterally, outward and forward, the other laterally, outward and backward to the surface, the surface openings of the tubes lying slightly posterior to the single nasal aperture of the fish.

System No. 5 lies at the point where the main canal bends sharply laterally, and was always found as a relatively long tube,

arising from the lateral aspect of the canal. It ran at first forward and slightly laterally, almost parallel to the main canal, then turned sharply laterally, and, branching dichotomously, ended in two pores which lay directly between, or one of them even slightly in front of, the exposed portions of the eyeballs.

The sixth system lies on the mesial side of the main canal and was always found as a group of two, three or four tubes, which arose separately and independently from the main canal, just at the bend in that canal and close to the point of origin of the trunk of system 5. Where there were four tubes the anterior tube of the group ran mesially and forward, the second tube mesially, the other two mesially and backward. Each tube ends on the outer surface of the head in a single pore, the four pores, in the specimen used for illustration, forming a nearly straight line, lying close to the middle line of the head, and close to the corresponding line of the opposite side. There is thus, in *Scomber,* an approach to a supraorbital, or frontal commissure.

The trunk of the next system, system 7, formed, in most of the specimens examined, a direct continuation of the main canal. It had every appearance of being the terminal section of that canal, and, in all the earlier dissections, was considered as such. The arrangement found in the corresponding part of the lateral system of *Amia* strongly suggesting that the main canal would not naturally so end, repeated dissections were made in order to establish what I considered as the true relations. These were finally found, as shown in the several figures, and were found repeatedly afterwards. A somewhat different arrangement, shown in Fig. 1*a,* has however since been found on both sides of the head of three large specimens, by Mr. Nomura. Whether this represents a difference due to age, or to some difference in species, or simply a variation in the formation of the canals, I am unable to judge. In the arrangement considered as the normal and proper one, the penultimate system of the supraorbital canal anastomoses, exactly as in *Amia,* with that system of the main infraorbital canal that is formed at the postorbital bend in the canal, and a double system arises. This system is, accordingly, in *Scomber,* system 11 infraorbital—7 supraorbital, as already stated in describing the main infraorbital canal. In the subdivision of this double sys-

tem three tubes and pores had been formed in all the specimens examined, without exception. One of these tubes, in what was considered as the normal arrangement, remained at the bend in the main infraorbital canal, and was a direct continuation of the trunk of the supraorbital system. The other two, resulting undoubtedly from the dichotomous subdivision of a single tube, had travelled downward along the suborbital part of the infraorbital canal, and appeared as separate tubes of that canal, as already described. In the second arrangement found, it seemed to be the terminal system of the supraorbital canal that fused with the infraorbital one, or possibly both that system and the penultimate one. Having been found after the drawings and manuscript were ready for press it was not further investigated.

After giving off the trunk of system 7 the supraorbital canal, in what was considered as the normal arrangement, makes a sharp, angular bend backward, and continues backward and laterally as the eighth or terminal system of the line. Near the anterior end of this section of the canal the seventh organ of the line is found, and approximately superficial to this organ the anterior head line of pit organs begins. The terminal section of the canal, as already stated in describing the bones, runs backward, outward and laterally in that part of the frontal that forms the anterior part of the ridge between the temporal and dilatator grooves, and then in the dermal tissues superficial to that ridge, passing superficial to the otic part of the main infraorbital canal, and ending in a single pore lying lateral to that canal.

In *Gadus,* according to Cole's descriptions (No. 16), it is the terminal system of the supraorbital canal that fuses with the infraorbital canal, *Gadus* differing in this from *Amia* and also from the larger number of the specimens of *Scomber* examined. It is, however, to be noted that the penultimate system of the supraorbital canal of *Gadus* is apparently wanting—that is, the system that should be found between organs 4 and 5 of the line—and that this suggests that the terminal and penultimate systems of the line may be fused to form the enlarged hind end of the canal as shown by Cole. If that be so the arrangement found in *Gadus* would not differ, in principle, from that found in *Amia* and most of the specimens of *Scomber,* and would agree exactly with what

seemed to be the conditions in the apparently exceptional specimens of *Scomber.*

There are thus, in *Scomber,* eight dendritic systems and seven sense organs in the supraorbital canal. Two of the dendritic systems are terminal systems, and a third one fuses with an infraorbital system to form a double system. Three of the sense organs of the line lie in the nasal, and four in the frontal, in the positions shown in Fig. 1*a.* All of these organs, excepting one, are innervated by branches that arise either directly from the ophthalmicus superficialis facialis, or from that nerve fused with the ophthalmicus superficialis trigemini. The one organ that is not so innervated is the anterior organ of the line, which organ is innervated by a nerve that is undoubtedly a branch of the buccalis facialis. The canal in *Scomber* thus differs radically in this respect from the canal in *Amia,* and the only explanation possible is, as already stated, that the anterior end of the nasal bone of *Scomber* is the homologue of either one half of the ethmoid bone of *Amia,* or of the antorbital bone of that fish. In *Amia,* the short bony tubes that form in connection with the first two organs of the main infraorbital line have fused with each other, and with the corresponding bones on the opposite side of the head, to form the so-called median, dermal ethmoid. In *Scomber* the tube formed in connection with the first organ of the same line has fused with the anterior end of the true nasal bone. This seems to throw an unexpected light on many questions relating to the dermal bones of the skull of fishes, and it becomes more than ever evident that the development of those parts of the lateral system that are related to the bones of the skull must be definitely known before their homologies can be properly determined.

In *Chimæra,* Cole (No. 15) finds two organs of the supraorbital canal innervated by a branch that has its apparent origin from the ophthalmicus profundus trigemini. The short section of canal containing the organs so innervated is said to lie between two long and nearly equal parts of the canal, the organs of both of those parts being innervated by branches of the ophthalmicus superficialis facialis. The origins, from the main nerves, of the branches that innervate the organs of these two long sections, and the subsequent subdivision of most of them, indicate sufficiently,

to any one familiar with the subject, that the sections so innervated have been developed from two centers that had much the same measure of independence that belongs to the several groups of organs along the main infraorbital lines of *Amia* and *Scomber*. This method of development, from separate centers, seems to be of frequent occurrence in the lateral system, and to give rise, occasionally, to apparent anomalies in the distribution of the canals. Platt's figures show that it occurs in the hyomandibular line of *Necturus;* and the separate innervation of the two parts of the line in that animal is said by her to be due (No. 55, p. 531) to the fact "that the lengthening of the main stem of the hyomandibularis has not kept pace with the growth of the sensory line" that gives origin both to the nerve and to the organs of the line. Applied to *Chimæra* this method of development indicates that the supraorbital canal of that fish has been developed from three secondary centers, two innervated by the ophthalmicus superficialis facialis and one, apparently, by the profundus trigemini; and that the section of canal belonging to each center has developed proximally and distally along the line of the canal and fused with the adjoining section or sections to form a single continuous canal, the profundus part of the canal becoming intercalated between the other two parts. Whether the anterior section of this canal in *Chimæra* has or has not its homologue in some part of the canals of *Amia* or *Scomber* is not evident. In *Necturus* it would seem to correspond to the lateral and anterior of the two lines of supraorbital organs described by Platt. The posterior section corresponds, unquestionably, to a part, or possibly to all, of the supraorbital canal of *Amia;* and to a part or all of that part of the canal of *Scomber* that lies posterior to its most anterior organ; plus, in both cases, the anterior head line of pit organs of the fish. In both *Amia* and *Scomber* this anterior head line of pit organs forms a posterior continuation of the supraorbital sensory line, directed toward the supratemporal commissure, and, in *Scomber,* reaching that commissure. In larvæ of *Amia* the anterior organ of this pit line was often found partly enclosed in the terminal opening of the supraorbital canal (No. 2, p. 506). In *Chimæra* the whole pit line must certainly have been regularly enclosed in that canal, and the

supraobital canal, so prolonged posteriorly, has fused with the supratemporal commissure. This posterior part of the supraorbital line in these three fishes seems to be represented in *Necturus* by the four organs said by Platt to be innervated by a separate dorso-posterior branch of the ophthalmicus facialis (No. 55, Fig. 31). In certain teleosts the pit line seems, from Sagemehl's descriptions (No. 66, p. 508), to be enclosed, as it is in *Chimæra,* and to fuse with the so-called supratemporal commissure of the fish; but this commissure, in the fishes referred to by Sagemehl, is said by him to lie in the parietal bone and not in the extrascapular ones, and hence not to be the homologue of the commissure in *Amia.*

Regarding the middle one of the three sections of the supraorbital canal of *Chimæra* Cole suggests, in explanation of its innervation, that certain fibers of the lateralis facialis have become secondarily juxtaposed to the profundus trigemini, thus appearing as, but not in reality being, a part of that nerve. As the superior branch of the nervus oculomotorius and the nervus trochlearis both seem, from their distribution, as given in Cole's figure, to lie between the two nerves concerned, such a secondary juxtaposition seems to me wholly impossible, as already fully set forth in discussing these same nerves in elasmobranchs in general in my earlier work (No. 4, p. 539). For similar reasons a simple juxtaposition of lateral fibers coming from the buccalis facialis seems impossible, the nervus opticus lying between the two nerves concerned. The only proper explanation, if the observation be correct, seems to me to be that lateral sensory fibers may, in certain animals, be associated with the nervus profundus trigemini in exactly the same manner that they are associated with other branches of the nervus trigeminus, and as they are also associated with the roots and branches of the facialis, glossopharyngeus and vagus. The development of the profundus in *Necturus,* as given by Platt; the statement, by the same author (No. 55, p. 530) that certain organs of the infraorbital of *Necturus* are in part innervated by branches from the profundus; and van Wijhe's statement (No. 79, p. 21) that a branch of the same nerve in *Pristiurus* innervates a part of the supraorbital line of that fish, all certainly indicate this.

As to the development of the profundus, Platt says (No. 55,

p. 491) that in *Necturus* it splits off from a primitive supraorbital ridge of thickened ectoderm, the supraorbital sense organs and the ophthalmicus superficialis developing in and from a secondary ridge which occupies exactly the position of the primitive one. In my work on the cranial nerves of *Amia,* I assumed (No. 4, p. 635) that the profundus nerve of *Necturus,* as described in Platt's earlier work (No. 54), must, from its manner of development, be the homologue of the ophthalmicus superficialis trigemini of *Amia.* In this I seem to have been wrong, the nerve, as described in her later work, seeming to be, unquestionably, the homologue of the similarly named nerve in other Ichthyopsida, where it lies, in the adult, ventral to the rectus superior and obliquus superior muscles, and probably always ventral also to the nerves that innervate those muscles. In marked contradistinction to this position in the adult, the nerve must, at the time of its origin from the supraorbital ectodermal ridge, if Platt is correct, lie dorsal to both those muscles and to the nerves innervating them. Its position in the adult, ventral to these structures, thus needs some special explanation, and this explanation would necessarily differ according as one assumes that all or certain of the nerves concerned are first laid down as lines of cells, or that they grow peripherally either from the brain or from their ganglia. Relative differences in the times of development of the several nerves might sufficiently account for it, and, as applied to the profundus nerve, developed in the manner stated by Platt, might also account for the throwing down of certain lateral sensory fibers with that nerve in certain animals and not in others. The simultaneous throwing down of lateral and general sensory fibers seems even to have been observed by Platt, along the infraorbital line of *Necturus,* where, according to her (No. 55, p. 520), the infraorbital ridge gives rise to a single nerve " from which the inner part splits off as a trigeminal branch, while the outer part remains as a branch of the facialis."

In *Ambystoma,* if I interpret rightly Herrick's figures (No. 35), the ramus ophthalmicus trigemini, which must be the homologue of Platt's ophthalmicus profundus and of the ramus nasalis of other authors, lies ventral to the nervus opticus. The nerve is said by Herrick to contribute certain fibers to the nervus adducens, destined to innervate the M. retractor bulbi, and certain of its

branches are said to pierce and traverse certain of the muscles of the eyeball. In *Salamandra* the ramus nasalis is said by von Plessen (No. 57) to lie dorsal to the opticus, and I have assumed it to so lie in *Necturus*. This indicates, if I am right in my interpretation of Herrick's statement, either some error in the descriptions of this nerve, or some important difference to be explained.

In *Ammocœtes,* the supraorbital line of ganoids and teleosts seems to be represented by a single organ said by Alcock (No. 1, p. 136) to be innervated by the so-called third facial nerve of the fish. As the so-called ramus ophthalmicus superficialis of this fish "runs forward between the eyeball and the floor of the orbit," "and is concerned only with the innervation of sense organs belonging to the lateral line system," it would seem to be, unquestionably, the homologue of the buccalis facialis of ganoids and teleosts. Fürbringer, however, says (No. 26, p. 62) that it lies, in *Petromyzon,* dorsal to the nervus opticus and nervus oculomotorius; and his figures seem to show it ventral to the nervus trochlearis, that is in the position of a nervus profundus. What the homologue is, in ganoids and teleosts, of the line of sense organs it innervates is thus uncertain, though it would seem to correspond to that organ of the supraorbital line that is, in *Scomber,* innervated by a branch of the buccalis facialis.

3. *Preoperculo-Mandibular Canal.*

The preoperculo-mandibular canal begins, anteriorly, at a single pore that lies on the latero-ventral surface of the mandible close to its tip and not far from the corresponding pore of the same canal of the opposite side of the head. From this point the canal enters the dentary, and running backward through that bone issues on its outer surface near the hind end of its ventral arm. Here it lies for a short distance in an open groove on the outer surface of the adjoining ends of the dentary and articular, then enters the latter bone, and issues at its hind end immediately postero-ventral to the hind end of the articular surface for the quadrate. It then traverses the dermal tissues between the mandible and preoperculum, lies, for a short distance, in an open groove on the outer surface of the latter bone, which bone it then enters and traverses its full length. Issuing at the dorsal end of the

preoperculum it traverses a relatively wide strip of dermal tissue, and then joins the main infraorbital canal at the enlarged hind end of the dorsal ridge on the squamosal.

There were, in the full length of the line, in all the larger specimens examined, what seemed to be but eight separate dendritic systems, five in the mandible, one between the mandible and preoperculum, one in the preoperculum, and one in the skin between the dorsal end of the preoperculum and the adjoining edge of the squamosal. The one system in the preoperculum was, however, so unusually large and was placed in such an exceptional position relative to the related sensory organs, that I had repeated examinations made of it by Dr. Dewitz and later by Mr. Nomura. Dr. Dewitz, in his dissections, always found an arrangement of tubes that was approximately that shown in Figs. 2–4, and he always found what seemed to be a single large sense organ lying directly opposite the point where the tubes of the system arose from the preopercular canal. This large organ was always innervated by two separate branches of the mandibularis externus facialis. Mr. Nomura, in two young specimens that he examined, found the arrangement shown in Fig. 1*a*. In these two specimens there seemed to be no question that there were, in reality, four systems in what, in large specimens, seemed always to be a single system. The trunks of the four systems, and the four related organs, simply become crowded together with age and then appear as a single system and organ. While these results should certainly be controlled by sections of larvæ, they can be accepted as correct for the purposes of the present paper. As no organ was found near the ventral end of the preoperculum, in any of the specimens examined, it seems exceedingly probable that the system formed between the mandibular and preopercular parts of the line, is, as in *Amia,* a double system, and that it is represented by the two trunks and four pores marked in the figures pmp^6. There are, accordingly, eleven systems in the entire line.

The first system of the line is a terminal one, and was represented, in all the specimens examined, by a single tube and pore, the tube curving inward and backward in the dentary. Close to it is the second system of the line, also always represented by a

single pore and tube, the tube lying mainly in the skin and running forward and inward from the pore to the main canal. The third system lies somewhat farther from the second than that one does from the first, and was represented in different specimens by one, two or three pores, the pores, where there were more than one, lying in a line parallel to the line of the main canal. Where there was but one pore, which was the condition most frequently found, the tube leading to it ran outward and backward from the main canal. Where there were two or three pores and tubes, the tubes diverged outward from a large opening in the dentary which led directly into the main canal.

The fourth system resembles the third, and lies slightly farther from it than the third does from the second. It was usually represented by a single pore and tube, but sometimes by two pores and tubes. The tube or tubes, in every case, ran outward, or outward and backward from the main canal.

The fifth system always lies at a considerable distance from the fourth, and is represented by one or two pores and tubes. The tube or tubes issue from that part of the main canal that lies in the open groove between the adjoining edges of the dentary and articular, the two tubes, when there were two, always issuing separately and independently of each other, but close together. When there was but a single tube in the system it was directed outward and backward, but usually less strongly backward than the tubes of the anterior systems.

The sixth system of the line is probably represented, as already set forth, by the single tube that leaves the preoperculum near its ventral end and by the ventral one of the group of tubes that leave that bone somewhat ventral to the middle of its length, the two tubes opening on the outer surface, in the specimens represented in the figures, by two or four pores. The sense organ that lies anterior to this double system lies in the articular. The one that lies posterior to it forms part of the large sensory patch found near the middle of the length of the preoperculum.

The next four systems of the line have been crowded together, and arise from the main canal opposite and immediately below the angle in the anterior edge of the preoperculum. The preopercular canal is here enlarged, and from this enlarged portion

from four to six tubes arise, in addition to the tube that represents one half of the double system No. 6. In this entire group there were from thirteen to fifteen external pores, most of them lying in a curved line not far from the long postero-ventral edge of the preoperculum, but certain of them forming a second, concentric line lying slightly antero-dorsal to the first one. From the pores long and delicate tubes lead upward and forward toward the enlarged part of the main canal, certain of them reaching the enlarged space without uniting with the adjoining tubes, while others fuse by twos or threes to form a single trunk.

The next, or eleventh system is the last one of the line, and was always found, as already stated, as a double system, formed by the fusion of the terminal system of the preoperculo-mandibular canal with the thirteenth system of the main infraorbital line. The double system is represented by two tubes one of which arises from the point where the preoperculo-mandibular canal joins the main infaorbital canal in the squamosal, and the other from the preopercular canal as it traverses the dermal tissue between the preoperculum and squamosal. The opening of this latter tube lies slightly dorsal to the hind end of the gelatine-like mass that surrounds the eye.

The first four sense organs of the line lie in the dentary, between consecutive ones of the first five systems of the line. The fifth organ lies in the articular, between the fifth and sixth systems of the line. The sixth, seventh, eighth and ninth organs lie in that enlarged part of the preopercular canal that is found near the middle of its length, and are supplied by two separate branches of the mandibularis externus facialis. Dorsal to these organs, or group of organs, but one sensory organ could be found in the canal, but two separate branches of the facialis enter the canal, near its dorsal end, and not far one from the other. One of them turns downward in the canal and supplies the tenth sense organ of the line, which lies in the preoperculum near its dorsal end. The other turns upward in the canal, but no sense organ could be found related to it. It may be the nerve of an organ that has disappeared, and there may have been between it and organ ten a dendritic system that has been entirely aborted by the gelatine-

like mass that covers externally this part of the canal, just as similar systems have been obliterated in the postorbital part of the main infraorbital canal.

In *Chimæra,* according to Cole (No. 15), the preoperculo-mandibular canal is represented by two separate canals, called by him the hyomandibular canals. Each of these canals arises, independently, from the superior division of the infraorbital canal of the fish, one immediately anterior to the first otic organ and the other immediately posterior to that organ. From the anterior one of these two canals, at about the middle of its length, a so-called inferior division of the buccal part of the main infraorbital canal has its origin. This inferior buccal canal is said by Cole to have been found by Garman, in a specimen examined by that author, arising from the main, or dorsal buccal canal, instead of from the anterior hyomandibular one. The inferior buccal canal is said by Cole to be innervated by two separate branches of the outer buccal nerve; which indicates clearly that it has developed from two separate centers. This inferior buccal canal and the anterior hyomandibular one would therefore seem to together represent some combination of the cheek lines or pit organs of *Amia* and one or more of the anterior groups of infraorbital organs of *Amia* and *Scomber.* As the anterior hyomandibular line seems also to have arisen from two centers, and as there are two separate groups of ampullary organs associated with it, this line may represent the cheek and mandibular organs of *Amia,* the posterior hyomandibular line then alone representing the preopercular line of *Amia.* It is to be remembered, in this connection, that the vertical pit line of the cheek of *Amia* ends dorsally among the pores of group 12 infraorbital (No. 2, p. 506).

In *Necturus* the hyomandibular sensory line of Platt's descriptions is apparently the homologue of the entire preoperculo-mandibular canal of *Amia,* and the mandibular line the homologue of the cheek and mandibular lines of pit organs. The development and innervation all tend to show this, and I have already referred to it in an earlier work (No. 7). The anterior, or mandibular part of the hyomandibular line of *Necturus* is said by Platt to arise independently of the posterior or hyoid portion, developing in connection with the anterior end of the ventral longitudinal ridge

of ectodermic thickening, while the hyoid portion develops from the hyomandibular ridge. The innervation of the two parts of the line, in the oldest embryo figured (No. 55, Fig. 31), retains the impress of this independence of origin, and agrees strictly in this with the larval and adult conditions found in *Amia*. The mandibular line shows, in its development, horizontal and vertical portions separated by a sharp angle; and in the oldest embryo figured, two organs of the line have passed onto the upper lip ventral to the buccal line or organs. The whole arrangement indicates, to me almost unquestionably, a strict analogy with the conditions found in *Amia*, and explains, or helps to explain, the somewhat aberrant conditions shown in *Chimæra*. The dorsal end of the hyomandibular line seems to be shifted forward, relatively to the main infraorbital line, in *Chimæra*, and also in *Necturus*, and a glance at Kingsbury's figures (No. 42) of the sensory lines in other Amphibia will show that this may be a general characteristic of all Ichthyopsida other than Teleosts and Ganoids.

4. *Supratemporal Commissure.*

The supratemporal commissure lies in the mesial arm of the extrascapular, extending the full length of that arm and then forward and mesially, in the skin, slightly beyond the antero-mesial end of the arm. So far as could be determined, there are only two sense organs in the canal, and hence probably but two dendritic systems in the line. The arrangment of the tubes and pores seems, however, to indicate three dendritic systems. At the antero-mesial end of the line there is a single tube and pore. Posterior to this pore there is a series of from four to seven pores each of which is the external opening of a short tube leading directly into the canal. These tubes and pores are usually arranged in two somewhat separate groups, and one of the two sense organs of the line lies between the two groups. The second sense organ of the line lies posterior to all the tubes, close to the point where the commissure joins the main infraorbital canal. This arrangement of tubes and organs seems to indicate that the terminal system of the line has undergone repeated subdivision, and that the system that normally develops between the second

organ of the line and organ 14 infraorbital is system 14 of the latter line, that system thus being a double system.

The two sense organs of the line are innervated by branches of the first, large branch of the nervus lineæ lateralis.

Organ 14 infraorbital of *Scomber* is thus the homologue of organ 18 infraorbital of *Amia.* It must also be the homologue of organ 4 of the lateral canal of Cole's description of *Gadus,* if organ 3 of that fish is the homologue of the glossopharyngeal organ of *Amia,* as I have been led to suggest (No. 8, p. 369).

In *Menidia* there is, according to Herrick (No. 36), but one sense organ in the supratemporal commissure.

5. *Lines of Surface Pit Organs*

But three lines of surface pit organs could be found on the head of *Scomber.* They correspond, in general position, to the anterior, middle and posterior head lines of *Amia,* and are undoubtedly the homologues of those lines. Their innervation could not be determined. There were usually from five to eight organs in each line.

The anterior line begins antero-mesial to the terminal pore of the supraorbital canal, approximately dorsal to the posterior organ of the canal, and runs backward and mesially to a point slightly lateral to, or lateral and anterior to, the terminal pore of the supratemporal commissure.

The middle line begins antero-mesial to the point where the preoperculo-mandibular canal joins the main infraorbital canal, and runs mesially and forward for a short distance.

The posterior line forms, with its fellow of the opposite side of the head, a transverse line across the top of the head, approximately between the terminal pores of the supratemporal commissures.

No surface indications of any other head lines were found, but there was always a small branch sent backward and downward from the mandibularis externus facialis toward the lower edge of the preoperculum, which may perhaps be destined to supply such a line.

Myology.

1. *Muscles of the Eyeball.*

The eyeball of *Scomber* is large, and the muscles that operate it well developed. In addition to the six usual muscles there is a rudimentary muscle associated with, and apparently a part of, the rectus internus.

The Obliqui Muscles (Figs. 52, 61 and 66) arise, on each side of the head, at the anterior part of the orbit, from the lateral surface of the membranous interorbital septum. The surface of origin of the obliquus superior lies immediately ventral to the exposed, orbital part of the nervus olfactorius, the surface or origin of the obliquus inferior lying immediately ventro-posterior to it. A small part of the inferior muscle extends, at its insertion, upward and forward around the inferior edge and then along the anterior surface of the superior muscle, and reaches to the level of its dorsal edge.

The obliquus superior is inserted on the eyeball close to the insertion of the rectus superior, there lying immediately dorsal to the latter muscle, and hence superficial to it. The obliquus inferior is similarly inserted close to the insertion of the rectus inferior, lying immediately ventral and superficial to it. The four muscles all widen and become tendinous at their insertions. Each pair, at its insertion, is covered superficially, that is dorsally or ventrally as the case may be, by a thin and transparent but strong membrane, which arises on the eyeball, near the edge of the cornea, and is inserted on the outer surface of each of the two muscles of each pair.

The Recti Muscles all arise at the hind end of the orbit, or in the eye-muscle canal. The rectus superior arises from the anterior edge and end of the horizontal membrane that separates the eye-muscle canal into dorsal and ventral parts, and is inserted, by a tendinous end, close to the obliquus superior, as already stated. The rectus inferior arises partly from the membranous interorbital septum, between the nervus opticus and the anterior edge of the basisphenoid, and partly from a ligament or tendon, that arises from the dorsal end of the shank of the basisphenoid and runs forward and outward along the hind edge of the muscle.

The muscle is inserted close to the obliquus inferior in the manner already described. The rectus internus arises from the mesial part of the ventral surface of the anterior two thirds, approximately, of the horizontal membrane of the eye-muscle canal. It runs forward, ventral to the rectus inferior, and is inserted directly on the eyeball, between the oblique muscles, without the intervention of a tendinous end. A small but well developed tendon, is, however, always found running forward from the distal end of the muscle and having its insertion on the eyeball. Associated with the rectus internus there is always a slender rudimentary muscle which arises by a long tendon from the shank of the basisphenoid, immediately dorsal to the point of origin of the ligament related to the rectus inferior. This rudimentary muscle runs forward along the dorsal edge of the rectus internus, close to and parallel to that muscle, and, continuing forward beyond it, widens considerably and is inserted in loose connective tissue that covers the eyeball. The rectus externus arises from the lateral walls of the eye-muscle canal, dorsal to the horizontal membrane of the canal, its surface of origin beginning posterior to the pituitary fossa and continuing backward to the extreme hind end of the canal. The muscle turns outward as it issues from the canal, and, near its insertion, becomes reduced to a tendinous point which passes under the outer edge of the cornea and is there inserted on the inner surface of the cornea and on the outer surface of the sclerotic.

The muscles are innervated in the same way that they are in *Amia,* with the exception, only, of the order in which the branches to the rectus internus and rectus inferior leave the inferior branch of the oculomotorius. This will be fully described in describing the latter nerve.

2. *Muscles Innervated by the Nervus Trigeminus and Nervus Facialis.*

When the outer skin is removed from the lower portion of the cheek, there is found immediately beneath it, between it and the pigment-layer, a thin fibrous layer, the fibers of which radiate upward from the lower, posterior corner of the mandible. The fibers run upward and forward, directly upward, and upward and

backward, the layer becoming gradually thinner in its upper and posterior portions, and finally disappearing as a distinct fibrous structure. In this fascia-like layer the scales of the cheek, and the delicate scale-like postorbital bones, have their insertions. It is, therefore, a special formation of the corium. Its principal insertion is on the internal surfaces of the lachrymal and suborbital bones. When it, and the bones to which it is attached are removed, the adductor mandibulæ, levator arcus palatini and dilatator operculi, are exposed. The levator maxillæ superioris, as a separate muscle, is not found in *Scomber,* but it is represented, apparently, by certain tendons found associating with different parts of the adductor mandibulæ.

The Adductor Mandibulæ (Figs. 54 and 55) presents three well-defined portions; a superficial portion, A_1, a deeper portion, A_2A_3, and a mandibular portion, A_ω.

A_1, the superficial portion of the adductor, arises almost entirely from the upper portion of the outer surface of the preoperculum, a few fibers only, at the extreme upper corner of the muscle, arising from the outer surface of the hyomandibular. The fibers of the muscle run downward and forward, crossing, externally, the lower half of the levator arcus palatini and the upper half of A_2A_3. At its lower end the muscle separates slightly into two portions, the division not extending far into the muscle and apparently not having any special morphological significance. Those fibers of the muscle that arise from the hyomandibular form a small and somewhat separate bundle on the inner surface of the muscle. The outer surface of the muscle is marked by several faint, tendinous lines, not shown in the figures, and on its inner surface, along its antero-dorsal edge, there is a long, tendinous band which gives insertion, at about the middle of its length, to a tendinous formation which doubtless represents, in part, one of the divisions of the levator maxillæ superioris.

Along the middle portion of the inner surface of the distal half of the muscle, there is a broad longitudinal tendinous band, from which, at the distal end of the muscle, two tendons arise, an anterior and superficial one, and a posterior and deeper one. The fibers of the muscle are all inserted in this tendinous band, none

of them having any other insertion whatever, though some of them, along the postero-ventral edge of the muscle, join and are continuous with fibers of the muscle A_2A_3. The anterior and superficial tendon that arises from the tendinous band separates at once into two parts. One of these parts (*t.* a_1 *la*) is short and broad, and triangular in shape, runs forward and downward along the inner surface of the lachrymal, and is inserted along the lower edge of the posterior third of that bone. It lies between the lachrymal bone and the crease or fold of the external skin that extends upward between the lachrymal and the maxillary. The other and smaller part of the anterior and superficial tendon runs downward and backward, and is inserted on the outer surface of the articular, near its hind end. The posterior and deeper tendon of the muscle runs downward and forward, and joins a tendon that may be called tendon A_2A_3, joining that tendon at the point where it joins a tendon or fascia on the inner surface of A_ω. The muscle, along its postero-ventral edge, is partly continuous with A_2A_3, as stated above.

A_2A_3, the deeper portion of the adductor, lies partly internal to and partly postero-ventral to A_1. It is single at its origin but double at its insertion, and is apparently formed by the almost complete fusion of the two muscles called by Vetter (No. 75) A_2 and A_3 in the fishes described by him. It arises from the anterior edge of the preoperculum, along something more than its middle third, from the outer surfaces of the hyomandibular and metapterygoid, and from the dorsal end of the quadrate, its surfaces of origin on these latter three bones lying immediately in front of the preoperculum. On its outer surface there are two strong tendinous lines, partly oblique and partly longitudinal in position. They mark the outer edges of two aponeurotic formations which extend inward, downward, and backward into the muscle. The posterior one of these two aponeuroses lies ventral to the other one, is short, and the fibers arising from its antero-internal surface are inserted on the outer surface of the other aponeurosis. Neither of the two formations extends through the muscle to its inner surface.

Toward its insertion the muscle A_2A_3 separates partly into two parts, as already stated, and I accordingly call them A_2 and A_3,

though I have no intention whatever, in so doing, of definitely homologizing them with the similarly named muscles in other fishes.

A_3 lies directly internal to A_2, but only covers a part of its inner surface. It extends backward from the distal end of the united muscles through about two thirds the length of that muscle, and downward from the antero-dorsal edge of the muscle through about two thirds its width. It consists of a thin layer, only, of muscle fibers, all of which are inserted on a tendon which forms upon its mesial surface. At the distal end of the muscle this tendon separates into three parts, an upper, anterior one, a middle one, and a lower, posterior one. The upper, anterior tendon (*t. a_3 mx*) runs almost directly forward, internal to the distal end of A_1 but external to the dorso-posterior corner of A_ω, and then forward internal to and immediately dorsal to the tendon *a_1 la,* which arises from the anterior end of A_1. Like this latter tendon it lies along the inner surface of the lachrymal, between that bone and the dermal fold that lies between it and the maxillary. It is inserted on or near that process of the maxillary that lies on the outer surface of that bone near its ventral edge and close to its anterior end. It may, accordingly, be referred to as the superior maxillary tendon of the adductor muscle. Its general position seems to indicate that it is the homologue of that tendon of *Amia* that has its origin on the coronoid process of the mandible and its insertion on the inner, instead of on the outer, surface of the maxillary (No. 4, p. 548). Its insertion, in *Scomber,* is such that any pull upon it would move the maxillary upward internal to the lachrymal. In one specimen it was double, the lower, stronger part having the ordinary insertion, while the upper, more slender part was inserted on the upper edge of the maxillary near the middle of its length.

Slightly distal to the base of the superior maxillary tendon a small branch tendon is sent from it downward and backward external to A_ω, internal to tendon *a_1 la,* and immediately internal to, or slightly anterior to and parallel to, the small posterior branch of that same tendon. It is inserted, with the latter branch of tendon *a_1 la,* on the outer surface of the articular near its hind end.

The middle tendon of A_3 arises from the upper, superior maxillary tendon of the muscle, at its base. It runs downward and forward, internal to the posterior tendon of A_1, and internal to the hind end of A_ω. There it joins, in part, a fascia on the inner surface of A_ω, and in part it continues downward and forward along the lateral surface of that fascia, between it and the muscle fibers of A_ω, toward the ventral edge of the latter muscle. Slightly dorsal to that ventral edge it pierces A_ω, reaches its lateral surface and is there inserted on the mesial surface of the articular, ventral to Meckel's cartilage.

The lower, posterior tendon of A_3 (*t. a_3 art*) runs downward and forward along the lateral surface of A_ω to the hind end of Meckel's cartilage, where it is inserted partly on that cartilage and partly on the mesial surface of the articular immediately above the hind end of the cartilage, a slight eminence on the bone marking its place of insertion. From Meckel's cartilage, immediately in front of the insertion of this tendon, there is a tuft of tendinous fibers which run upward and backward parallel to the tendon of A_3, into A_ω, and there disappear.

A_2 is a strong muscle forming much the larger part of A_2A_3 On its mesial surface, at its distal end, a tendon forms and separates distally into two parts. One of these parts is joined by a part of the middle tendon of A_3, and by the posterior and deeper tendon of A_1, to form with those tendons the tendon that was above referred to as tendon A_2A_3, which tendon then joins the fascia on the mesial surface of A_ω. The other part of the tendon of A_2 becomes a short strong tendon which runs downward and forward into, and sometimes along the outer surface of A_ω, and gives origin to part of the fibers of that muscle. Most of the muscle fibers of A_2 are inserted on these two tendons; some of them, however, pass directly into and become part of the mandibular muscle A_ω.

A_ω, the mandibular part of the adductor, is a thin, broad muscle lying internal to and covering almost the entire inner surface of the mandible. Its mesial surface, excepting only its ventro-posterior corner, is covered by a tendinous fascia, the mesial surface of which, as there is no splenial in *Scomber,* lies directly against the lining membrane of the mouth cavity. From the

hind end of this fascia a strong tendon runs directly backward, and, separating at its hind end into two heads, is inserted on the adjoining inner surfaces of the preoperculum and quadrate. The two heads of the tendon here straddle the internal surface of the symplectic, one being inserted in front of that bone and the other behind it. The rami mandibularis externus and internus facialis pass between the two heads of this tendon and then reach the lateral surface, or lower edge of the tendon. The two nerves thus lie antero-lateral to the preopercular head of the tendon, and postero-mesial to its quadrate head. Immediately dorsal to the point where this tendon has its origin from the fascia on the inner surface of A_ω, that fascia is joined by parts of the tendons of A_1, A_2 and A_3, as already described. From the lateral or deep surface of the fascia, part of the fibers of A_ω arise. Other fibers of the muscle arise from one of the two tendons of A_2; others directly from, and as a continuation of, the fibers of A_2; and still others, a small bundle at the postero-ventral corner of the muscle, from a tendon that has its origin on the inferior end of the preoperculum. The dorsal fibers of the muscle run upward and forward, the middle ones forward, and the ventral ones downward and forward. All of them are inserted on the inner surfaces of the articular and dentary, on the skin that covers the lower edge of the dentary, and on a strong membrane that covers Meckel's cartilage throughout its entire length. This latter membrane seems much too strong to be simply the perichondrial membrane of the cartilage, but it apparently includes that membrane. The cartilage lies in it, imbedded in the outer, lateral surface of A_ω, none of the fibers of the latter muscle being inserted directly onto the cartilage.

A_1 is innervated by a branch of the ramus maxillaris inferior trigemini given off just as that nerve passes outward around the anterior edge of the levator arcus palatini. A_2A_3 is innervated by another branch of the same nerve, given off at the same place. The branch to A_1 enters that muscle on its mesial surface. The branch to A_2A_3 enters that muscle on its lateral surface. The maxillaris inferior, after giving off these two branches, continues downward and forward between the two muscles and enters the mandible, where branches are sent to A_ω.

The Levator Maxillæ Superioris, as a muscle, is not found in *Scomber*. It seems, however, to be represented by certain tendons and ligaments.

On the inner surface of the antero-dorsal edges of both A_1 and A_2, at about the middle of the length of each muscle, there is inserted a fibrous or tendinous band. These bands arise, together, from a fibrous membrane that lies internal to the levator arcus palatini, between that muscle and the adductor hyomandibularis and adductor arcus palatini. The external portion or layer of this membrane is distinctly fibrous in character, and can be easily separated from the internal portion or layer, which has more the character of connective tissue. The fibers of the external layer arise from the anterior edge of that thin portion of the hyomandibular that lies immediately ventral to its dorso-anterior articular head, or from the lateral surface of that bone near its anterior edge, and also from the dorsal edge and adjoining surface of that process of the metapterygoid that projects backward mesial to the hyomandibular. From this line of origin the fibers run almost directly forward, and disappear on the external surface of the connective tissue layer near the hind edge of the orbit. The connective tissue layer has the same posterior origin as the tendinous layer, but its dorsal portion has a large surface of attachment on the lateral surface of the postorbital ossification and on the external surface of the united adductor hyomandibularis and adductor arcus palatini muscles, near the origin of those muscles. Antero-dorsally the membrane passes onto the orbital face of the postorbital ossification, filling the hour-glass-shaped depression on that face of that bone, and then becomes continuous with the membranes lining the orbit. The attachment to the adductor hyomandibularis and adductor arcus palatini is often so strong that the membrane seems to give origin to a part of the fibers of those muscles.

From the external, tendinous portion of this membrane the two tendons that have their insertions on A_1 and A_2 arise, as do also two small tendons that have their attachment on the anterior edge of the levator arcus palatini. The internal connective tissue portion envelopes the ramus maxillaris inferior trigemini as it passes outward and downward in this part of its course, and

envelops also the venous and arterial vessels associated with that nerve. The tendinous portion of the membrane thus seems, both in origin and insertion, to represent the first two divisions of the levator maxillæ superioris of *Amia*. The third division of that muscle seems to be represented in the broad flat ligament that arises from the posterior surface of the preorbital ossification and is inserted on the cartilaginous ridge that forms the posterior boundary of the articular facet by which the palato-quadrate articulates with the preorbital ossification. The ligaments that extend from the nasal and ethmoid of *Scomber* to the outer surface of the anterior end of the maxillary, seem to represent, one or both, the fourth division of the levator maxillæ superioris of *Amia;* and it is to be noted that part of that muscle, in *Amia,* has its origin from the ventral surface of the antorbital bone. The two tendons that extend downward and backward, in *Scomber,* and have their insertions on the outer surface of the articular, although strongly recalling the tendons of Lms^3 and Lms^2 in *Amia* can hardly be the homologues of those tendons, as they lie external to the articular instead of internal to it. Those tendons of *Amia* are much more probably represented in *Scomber* by the tendon a_1 *la* and the tendinous tuft that has its origin immediately in front of that tendon.

The Levator Arcus Palatini (*Lap*, Figs. 11, 54 and 55) arises from the dorsal edge of the postero-lateral face of the postorbital ossification, and from the postero-lateral face of that bone immediately below that edge. The fibers of the muscle run downward, and downward and backward, radiating from their relatively small surface of origin, and having a large surface of insertion. This surface of insertion includes a portion of the outer surface of the dorsal end of the hyomandibular; the inner surface of the dorsal end of the metapterygoid and that of the opposing, lateral surface of that process of the metapterygoid that projects backward internal to the hyomandibular; and about one half of that part of the upper edge of the metapterygoid that lies anterior to the anterior edge of the hyomandibular.

From the dorsal edge of the postorbital ossification a broad, flat tendon runs downward and backward into the muscle, lying longitudinally in the muscle and extending through about two

thirds its length. This tendon has a nearly rectangular surface, and gives origin, on both sides, to the fibers of the muscle. The anterior edge of the tendon coincides with the anterior edge of the muscle, and at its origin the tendon is as wide as the muscle. At its distal end it is only about two thirds as wide as the muscle. The distal half of the muscle is crossed, nearly at right angles, by A_1.

The Dilatator Operculi (*Do*) occupies the entire dilatator groove, arising, in that groove, from the dorsal surface of the frontal, postorbital ossification and squamosal. The dorsal fibers of the muscle run backward and downward; the ventral fibers almost directly backward. Nearly all of them are inserted on a longitudinal tendon, the outer edge of which is seen as a tendinous line on the outer surface of the muscle. This tendon begins not far from the extreme anterior end of the muscle, and, running downward and backward, is inserted on the operculum on the flat, projecting edge of bone that forms the superficial or antero-lateral edge of the facet by which the operculum articulates with the hyomandibular. The deep edge of the tendon, in its anterior part, has its origin on the ridge that separates the dilatator groove into its antero-lateral and postero-mesial portions. A few of the fibers of the muscle are inserted, with its tendon, directly on the operculum. The muscle crosses externally the posterior, squamosal head of the hyomandibular; crosses externally a small, dorso-posterior corner of the levator arcus palatini; and passes partly internal to the projecting dorsal end of the preoperculum. It lies mesial to the foramen by which the ramus oticus facialis reaches the dorsal surface of the skull, and those branches of that nerve that supply organs 11 and 12 in the squamosal run upward and mesially along the external surface of the muscle and then pass inward between the muscle and the lateral surface of the ridge of bone that separates the dilatator and temporal grooves. The muscle must accordingly, in acquiring its origin on the dorsal surface of the skull, have crowded in between the nerve and the canal it innervates, either pushing the nerve laterally or the canal mesially.

The Intermandibularis (*Im*, Fig. 57) is a small, much degenerated muscle, lying between the rami of the mandibles and

extending backward a short distance from the symphysis. It arises, on each side, near the dorsal edge of the dentary, in a slight longitudinal depression in that bone, and lies between the tendons by which the two parts of the geniohyoideus have their insertion.

The Geniohyoideus presents, as in *Amia,* two portions, a superficial, inferior portion and a deeper, superior one; but these two portions of the muscle, in *Scomber,* and the muscles of opposite sides of the head, are much more fused with each other than they are in *Amia.*

The superior, or deeper portion of each muscle (*Ghs,* Figs 56–58) arises by two more or less distinctly marked heads from the outer, ventro-lateral surface of the ceratohyal of its side of the head, slightly in front of the base of the fourth branchiostegal ray. One of these two heads is entirely muscular, the other entirely tendinous. The former is much the larger of the two and arises from the external surface of the ceratohyal in a narrow line which runs transversely from the ventro-posterior edge of the bone forward and upward somewhat more than half way across it. The other, or tendinous head of the muscle arises more from the integument that lines the mouth cavity than from the ceratohyal, the integument, however, being firmly attached to the ceratohyal at the place or origin of the tendon. This place of origin is on the external surface of the ceratohyal, near the dorso-anterior edge of the bone, usually about opposite the middle of the line of insertion of the muscular head. The groove that lodges the arteria hyoidea, and hence that artery also, lies between the two surfaces of origin. Both parts of the muscle run mesially and forward along the external surface of the ceratohyal, and soon unite more or less completely. The ventral, muscular head of the muscle here becomes entirely tendinous, and for a short distance the entire muscle is simply a broad, flat tendon. From this tendon the anterior, wholly muscular part of the muscle arises. The fibers of this anterior part of the muscle are in part inserted, with the fibers of the corresponding muscle of the opposite side of the head, in a median aponeurosis; but a large part of them continue forward and are inserted, with the corresponding fibers of the opposite muscle, on a relatively small, flat and narrow, median

tendon. This tendon is inserted by two heads, one on each side, on the inner surface of the dentary close to the symphysis.

In the median line of the ventral surface of the united superior geniohyoidei of oppposite sides of the head, there is a longitudinal depression, or concavity, in which lie the almost completely fused superficial, inferior portions of the two muscles. These inferior muscles (*Ghi*) take their origins from the deeper, superior muscles, and thus are partly fused with those muscles as well as being almost completely fused with each other. Together they form a single muscle, which is nearly round in section and runs directly forward in the middle line of the head. On the ventral surface of this muscle there is usually a slight median groove, which marks the line of separation of its two component parts; and, between it and the superior part of the muscle, on each side, there is a lateral and deeper groove. Anteriorly, the median, ventral groove disappears, and the ventral fibers of the inferior muscle unite and are inserted, either directly, or by a flat, median tendon, on the inner surface of the mandible, at the symphysis. The dorsal fibers of the two muscles, on the contrary, separate at this point completely, not only from each other but also from the deeper, superior muscle, and form two round and tapering muscle bundles, each of which is inserted, by a relatively long and small tendon, on the inner surface of the ramus of the mandible of its own side, near the symphysis. All three tendons of the inferior muscles lie ventral to the intermandibularis, the single, double-headed tendon of the superior muscle lying dorsal to it. The median tendon of the inferior muscles has the most ventral insertion, the insertion of the tendons of the superior muscles is next dorsal to it, while the two tendons of the inferior muscles pass dorsal to the tendons of the superior muscles, along their lateral edges, and are there inserted. Dorsal to the insertion of the latter tendons the mucous lining membrane of the mouth turns backward and then forward again, thus forming a delicate fold with a free posterior edge. The fold is narrow but long, extending a considerable distance backward, on each side, along the inner edge of the mandible, and is the mandibular breathing valve described by Dahlgren (No. 21) in other teleosts.

The dorsal surface of the anterior portion of the superior division of the geniohyoideus lies immediately underneath the mucus membrane that lines the mouth cavity, and the united muscles of opposite sides of the head here form that part of the floor of the mouth cavity that lies in front of and under the tongue. The tongue lies in the V-shaped space formed between the dorsal surfaces of the united muscles, and nearly fills the anterior end of the mouth cavity, its pointed, anterior end extending almost to the apex of the mandible. The thin membrane that connects the hyoid apparatus with the mandible, and thus completes the floor of the mouth cavity, extends from the ventral edge of the mandible to the dorso-lateral edge of the anterior portion of the superior division of the geniohyoideus, and, posterior to that muscle, to the external surface of the ceratohyal, somewhat lateral to the middle line of the bone. This membrane is formed, as in *Amia,* by the fused external dermis and internal lining membrane of the mouth, and it is in it, near its attachment to the ceratohyal, that the small, tendinous head of the superior geniohyoideus has its origin.

The Hyohyoideus can be considered, in *Scomber,* as in *Amia,* as having two divisions, a superior and an inferior one, but the inferior division arises in part from the second instead of entirely from the first, or most anterior, branchiostegal ray. This inferior division of the muscle has two distinct portions, each of which is usually partly double. One of these portions lies partly superficial to, or ventral to, the other portion, and it is much more independent of the superior division of the muscle, and much less a continuation of that muscle, than the deeper portion is. It arises mainly from the anterior edge of the most anterior branchiostegal ray, but there is a posterior continuation of the muscle in fibers that lie between the most anterior and the next posterior ray. The line of origin of the muscle begins some little distance from the base of the associated ray and extends distally to its free end. The muscle usually arises in two somewhat separate portions, which run mesially and forward, and, uniting, have a single, broad, flat tendon, which crosses the middle line of the head and is inserted on the ventral surface of the hypohyal of the opposite side. The muscle of the left side

of the head lies superficial to, that is ventral to, that of the right side, as in *Amia.* The other, deeper part of the inferior muscle arises from the ventral surface of the most anterior or next following ray, runs forward, or forward and laterally and is inserted partly on the ventro-posterior edge of the distal end of the ceratohyal, and partly on the adjoining and corresponding edge of the proximal end of the hypohyal. In Fig. 58 a part of this muscle, on the right hand side of the fish, is seen arising by a separate tendon. This is exceptional. The fibers of this deeper part of the muscle lie at a considerable angle to those of the superficial portion, and the two parts of the muscle, together, are apparently equivalent to the single muscle of *Amia.*

The superior division of the hyohyoideus is a thin layer of somewhat separate muscle bundles, extending from ray to ray along the inner surface of the gill cover. It is most developed near the bases of the branchiostegal rays, and extends distally on them for only about one third or one half their length. In part it arises, as in *Amia,* from the adjoining, ventro-posterior edge of the ceratohyal. Toward the free ends of the branchiostegal rays it disappears entirely, and near the proximal end of the ceratohyal it becomes a sheet of degenerate muscle tissue, or simply a series of patches of such tissue. From the dorsal edge of the last, or most dorsal branchiostegal ray, a sheet of this degenerate tissue extends upward to the inner surfaces of the interoperculum and suboperculum. Two other detached patches of similar tissue are found on the inner surface of the operculum, one lying posterior to the surface of insertion of the levator operculi, and the other at the hind edge of the operculum and extending across the notch in the hind edge of that bone.

The Adductor Hyomandibularis (*Ah,* Figs. 11 and 55) and Adductor Arcus Palatini (*Aap*) are, in *Scomber,* simply regions of a single continuous muscle. Nothing whatever, at the origin of the muscle, indicates a separation of its two parts, and such a separation, at its insertion, is indicated only by the fact that the posterior part of the continuous muscle is inserted on the inner surface of the hyomandibular, while the anterior part is inserted on the inner surface of the palatine arch. That part of the muscle that has its insertion on the inner surface of the

hyomandibular is pierced by the truncus hyomandibularis facialis, which runs upward, from its foramen, close against the lateral wall of the skull. That part of the united muscles that lies anterior to the truncus facialis forms much the larger part of it. It arises (Fig. 11) from that part of the lateral surfaces of the petrosal and the lateral wing of the parasphenoid, that lies in front of a nearly vertical line drawn from the dorsal surface of the muscle downward across the hind edge of the facial foramen and then along the anterior edge of the slight groove that marks the position of the infrapharyngobranchial of the first arch. The surface of origin does not extend quite to the dorsal edge of the petrosal. Antero-ventrally it extends forward along the dorsal edge of the lateral surface of the body of the parasphenoid some little distance in front of the anterior edge of the wing of the bone. That part of the united muscles that lies posterior to the truncus facialis arises from a small part of the lateral surface of the petrosal, extending backward and upward to the posterior edge of the bone near its dorsal end, and from a small adjoining portion of the anterior edge of the lateral surface of the squamosal, the hind edge of the muscle here being contiguous with the anterior end of the adductor operculi. The surface of origin of the entire muscle thus has an anterior, ventral portion, a posterior, dorsal portion, and a vertical portion connecting the two. The dorsal surface of the muscle is covered by the partly tendinous membrane that, in part, seems to present the first and second divisions of the levator maxillæ superioris, the membrane, near the origin of the adductor, being attached to its outer surface and seeming to serve in part as origin for it.

The fibers of the anterior and ventral part of the muscle run outward, or outward and forward, and are inserted on the inner surface of the dorsal edge of the metapterygoid along its entire length, the surface of insertion occupying the groove, already described, on the edge of the bone. These fibers are, therefore, that part of the muscle that corresponds to the separate adductor arcus palatini of certain other fishes. Anteriorly, this part of the muscle lies dorsal to the hind end of the entopterygoid, between it and the eyeball; posteriorly and mesially it lies immediately dorsal to the lining membrane of the roof of the mouth.

At its insertion it is separated from the corresponding muscle of the opposite side of the head by the narrow median rib on the ventral surface of the parasphenoid, that rib alone separating the two muscles, which thus form almost a continuous sheet across the under surface of the skull.

Continuous with this anterior and ventral portion of the muscle, and lying at right angles to it, is the thick, middle portion, which has its insertion on the inner surface of the thin anterior part of the hyomandibular, and on the adjoining parts of the shank and of the anterior articular arm of that bone. The anterior surface of this part of the muscle forms part of the hind wall of the orbit. The posterior surface is covered by the lining membrane of the mouth cavity, bears the opercular gill, and forms the anterior wall of the first gill cleft.

The posterior portion of the muscle lies nearly at right angles to the middle portion, inclining slightly upward and backward. It is thin, its fibers run outward, and outward and backward, and are inserted in a nearly horizontal line which extends backward across the shank of the hyomandibular, ventral to the opening of the facial canal, and then along the mesial surface of the opercular process of the bone. The facial nerve, as it issues from the skull through the facial foramen, turns slightly upward, close against the lateral surface of the skull, and then runs outward along the upper surface of this posterior part of the muscle, lying in a depression on its dorsal surface. The muscle here is very thin, but it forms, nevertheless, a continous sheet ventral to the nerve.

The Adductor Operculi (*Ao*) arises (Fig. 11) from the lateral surface of the squamosal, immediately posterior to the hind edge of the dorso-posterior portion of the adductor hyomandibularis, and from the adjoining dorsal portion of the lateral surface of the intercalar. Its fibers spread outward and backward, and are inserted, in a narrow line, along the ridge that runs backward, on the inner surface of the operculum, from the upper edge of the articular facet of the bone. This ridge, which is not distinctly shown in Fig. 37, marks the ventral limit of the depressed region that gives insertion to the levator operculi. It extends backward about halfway across the operculum, approximately in the line of the dorsal edge of the notch in the hind edge of the bone. The

ridge, the notch, the degenerate muscle fibers stretching across the notch, and the insertion of the adductor operculi along the ridge, all seem to indicate that this is a region where two branchiostegal rays have fused.

The adductor operculi, both at its origin and at its insertion, is directly contiguous with the adductor hyomandibularis. Its fibers, however, have a different direction from, and are entirely separate from, those of that muscle.

The Levator Operculi (*Lo,* Figs. 54 and 55) arises immediately above the dorso-posterior end of the posterior articular head of the hyomandibularis, from the thickened hind end and edge of the dorsal ridge of the squamosal. Its fibers run downward and backward, radiating from the small surface of origin, and are inserted in the depressed region on the dorsal portion of the inner surface of the operculum. It lies immediately external to the adductor operculi, but its fibers cross those of that muscle at a considerable angle. At its origin it is immediately contiguous with the dilatator operculi, and its anterior fibers are parallel to, and in immediate contact with, the posterior fibers of that muscle.

3. *Muscles Innervated by the Nervus Glossopharyngeus and Nervus Vagus.*

The Levatores Arcuum Branchialium (Figs. 59 and 60) are, as in *Amia,* seven in number, two interni and five externi. The muscles do not however, in *Scomber,* all arise together, as they do in *Amia,* and there is, in *Scomber,* a ligament connecting the first arch with the skull, not found, or not found equally developed, in *Amia.*

The two interni (*Labi*^{a}, *Labi*^{p}) arise, with the externi of the third and fourth arches (*Labe. III.–IV.*), from the lateral surface of the skull, in a horizontal line that extends the full length of the intercalar and slightly overlaps anteriorly the squamosal and petrosal. The surface of origin (Fig. 11) is wider posteriorly than anteriorly, and lies along, and immediately below, the sharp ridge that extends forward across the intercalar from the hind end of its suprascapular process. Anteriorly the surface of origin crosses the ventral corner of the squamosal, and extends

slightly beyond it onto the lateral surface of the petrosal above and posterior to the facial foramen. The origin of the third externus occupies a narrow band across the anterior end of this surface, lying sometimes almost entirely on the petrosal. The origin of the fourth externus occupies a similar, but narrower and longer band across the hind end of the surface. The two interni occupy the whole surface between these two terminal bands, the surface of origin of the anterior internus lying immediately ventral to the posterior two thirds of that of the posterior muscle.

The externi of the first and second arches (*Labe. I–II.*) arise, with the ligament (*Iad. I.*) that connects the first arch with the side wall of the skull, from the lateral surface of the skull immediately below and behind the facial foramen. The surface of origin of these muscles is oval in form, and lies mostly on the petrosal, but it extends backward slightly beyond that bone onto the anterior end of the intercalar. The surface of origin of the first externus occupies the ventral and larger part of this surface; that of the ligament lies immediately dorsal to that of the first externus; and that of the second externus immediately antero-dorsal to the other two.

The fifth externus (*Labe. V.*) arises from the posterior portion of the lateral surface of the intercalar, immediately above the suprascapular process of that bone. It shares this origin with a part of the fibers of the first muscle segment of the trunk, the surface of origin of the latter muscle extending dorsally onto the posterior process of the squamosal.

The anterior internus runs mesially and downward internal to the dorsal end of the posterior internus, and postero-internal to the suprapharyngobranchial of the first arch, and is inserted along the dorsal edge of the second infrapharyngobranchial. The surface of insertion of the muscle occupies the postero-dorsal edge of the small depression that lies between the two cartilaginous portions of the dorsal edge of the element, the antero-ventral part of the depression giving insertion to the obliquus dorsalis of the first arch. On the dorsal edge of the postero-mesial surface of the infrapharyngobranchial, adjoining the surface of insertion of the anterior internus, the obliquus dorsalis of the second arch has its insertion. The in-

ternus, as it passes internal to the suprapharyngobranchial of the first arch, bends somewhat sharply forward and downward around that element. The muscle here lies between the glossopharyngeus and first vague nerves, and between the efferent arteries of the first and second arches. It is innervated by a branch of the glossopharyngeus that arises from the truncus of that nerve close to its ganglion.

The posterior internus runs downward, backward and mesially, external to the dorsal end of the anterior internus, but internal to all the external levators. It is inserted on the dorsal surface of the infrapharyngobranchial of the third arch, the surface of insertion lying at about the middle of the piece, between the articular surfaces of the second and third epibranchials, and immediately lateral to the longitudinal ridge on the dorsal surface of the infrapharyngobranchial. The muscle thus lies, at its insertion, between the nerve and artery of the second arch and the same structures of the third arch. It is innervated by a branch of the first vagus nerve that arises from the posterior surface of the truncus not far from the ganglion of the nerve.

The externus of the first arch runs downward, backward and mesially, and is inserted by a tendinous end on the dorsal surface of the suprapharyngeal process of the first epibranchial, near its dorso-mesial end. The muscle lies, in its course, immediately internal to the ligament that connects the first arch with the side wall of the skull, internal to the external levator of the second arch, and external to the anterior internus. It lies, at its insertion, posterior to the glossopharyngeus, and is innervated by a small branch that arises from that nerve not far from the branch that innervates the anterior internus.

The externus of the second arch lies, at its origin, immediately external to that of the first. It runs decidedly backward, external to all the levator muscles it crosses, and is inserted by a tendinous end on the mesial edge of the suprapharyngeal process of the second epibranchial, near the middle of the length of that process. It lies, at its insertion, between the first and second vagus nerves; and is innervated by a small branch of the ramus posttrematicus of the former nerve. The muscle was always found double toward its origin, the dorsal part being inserted, not

on the skull, but on the outer surface of the jugular vein as that vein issues from the facial foramen. The pretrematic branch of the glossopharyngeus and the external carotid artery run forward between the two heads of the muscle.

The externus of the third arch lies, at its origin, immediately in front of the anterior edge of the posterior internus. It runs downward and backward immediately external to that muscle, lying approximately parallel to the second externus, and is inserted by tendon near the posterior end of the suprapharyngeal process of the third epibranchial. It is almost entirely tendinous through approximately the middle third of its length, this tendinous part lying directly external to the posterior internus. It lies, toward its insertion, between the ramus posttrematicus of the second vagus nerve and the ramus pretrematicus of the third vagus. It is innervated by a small branch of the second vagus, that usually arises from the trunk of the nerve before it separates into its pre- and post-trematic portions. In one specimen this branch arose from the pretrematic part of the nerve, close to its base.

The externus of the fourth arch lies, at its origin, immediately behind the two interni. It runs downward and backward, approximately parallel to the third externus, and is inserted by a long tendinous end on the postero-mesial edge of the fourth epibranchial, immediately distal to the bend that separates the proximal articular head of that bone from its shank. It lies, at its insertion, between the anterior and posterior branches of the third vagus. It is innervated by a small branch that arose in one specimen from the trunk of the third vagus, close to the ganglion of the nerve, and in another specimen from the trunk of the second vagus close to its ganglion. The latter specimen was the first one in which the nerve was traced, and the nerve fibers were not followed beyond their apparent origin from the second vagus. In the second dissection, where especial attention was given to it, it was found arising, as stated above, from the third vagus; and that was undoubtedly its real origin in the earlier dissection also.

The so-called fifth externus is tendinous at its origin, and is there practically continuous with the lower edge of that part of the first intermuscular septum that arises from the hind edge of

the posterior process of the squamosal. It runs downward and backward along the antero-ventral edge of the trunk muscle, passes external to the nerve of the lateral line, and is inserted in a tendinous membrane that lines the inner surface of the mucous membrane that forms the hind wall of the gill chamber. This membrane covers and is attached to the dorsal end of the antero-lateral face of the clavicle. The muscle, in the one specimen in which it was examined, was innervated by a branch of the third vagus that arose from the ganglionic swelling of the nerve. It is shown in Fig. 59 with a small section of the muscle attached.

The Interarcuales Dorsales are nine in number, three interarcuales dorsales, three obliqui dorsales, two transversi dorsales and a retractor arcuum branchialium. To these nine muscles should be added a ligament that probably represents the interarcualis between the hyoid and first branchial arches, and also a partly differentiated muscle that seems to represent the interarcualis between the fifth arch and an arch that formerly existed posterior to it.

The first interarcualis dorsalis (*Iad. I.*) is a ligament that arises (Fig. 11) from the lateral surface of the petrosal immediately dorsal to the surface of origin of the external levator of the first arch. It runs downward and slightly backward along the external surface of the external levator of the first arch, and is inserted along the antero-lateral edge of the first epibranchial, near its proximal end, and on the corresponding edge of the first infrapharyngobranchial, near its distal end. It usually breaks up into several parts near its insertion. It lies internal to, and hence morphologically in front of, the ramus anterior of the glossopharyngeus.

The second interarcualis dorsalis (*Iad. II.*) arises (Fig. 29) from the antero-lateral edge of the second epibranchial, opposite the base of the suprapharyngeal process of that bone. It runs forward and slightly inward and is inserted on the postero-mesial edge of the first epibranchial at the base of the suprapharyngeal process of that bone. It is a small muscle, largely tendinous, and is apparently innervated by branches of a plexus of delicate nerves that spread over its dorso-external surface, the nerves arising

from all three divisions of the first vagus nerve, in the angle formed by those divisions as they separate one from the other.

The third interarcualis dorsalis (*Iad. III.*) arises from the antero-lateral edge of the third epibranchial, opposite the suprapharyngeal process of that bone, runs forward and slightly upward, and is inserted on the extreme posterior end of the suprapharyngeal process of the second epibranchial. It is innervated by a branch of the second vagus nerve, that arises from the ramus anterior of the nervus before it separates into its two divisions.

The fourth interarcualis dorsalis (*Iad. IV.*) arises from the antero-lateral edge of the fourth epibranchial, runs forward and upward, and is inserted on the extreme posterior end of the suprapharyngeal process of the third epibranchial. It is a short muscle and is even more tendinous than the two preceding interarcuals. It was innervated, in the one specimen examined, by a branch that had its apparent origin from the pharyngeal portion of the ramus anterior of the third vagus nerve.

The fifth interarcualis dorsalis (*Iad. V.*), or what seems to be that muscle, arises from the extreme posterior end of the fifth ceratobranchial, curves upward, at first postero-laterally and then antero-mesially, and is inserted on the dorsal edge of the bent, articular, proximal head of the fourth epibranchial. It is, in a measure, continuous with, and looks like a part of, the anterior end of the constrictor of the œsophagus. Delicate branches of the fourth vagus extend toward it and apparently innervate it.

The obliquus dorsalis of the first arch (*Od. I.*) is simply a band of degenerate tissue, tendinous rather than muscular. It arises from the antero-lateral edge of the base of the suprapharyngeal process of the first epibranchial, runs forward and mesially, parallel to the first suprapharyngobranchial, and is inserted on the ventral part of the depression on the dorsal edge of the second infrapharyngobranchial. The dorsal part of the same depression gives insertion to the levator internus anterior. The obliquus muscle, when viewed from below, appears as a part of the second interarcualis dorsalis, a tendinous band that covers the ventral surface of the one, continuing forward and covering the ventro-posterior surface of the other.

The obliquus dorsalis of the second arch (*Od. II.*) is continu-

ous, posteriorly, with the transversus dorsalis anterior, the two muscles being simply parts of a single muscle-mass. The obliquus is represented by certain fibres that arise from the antero-lateral edge of the dorsal surface of the proximal articular head of the second epibranchial. These fibers form, on the dorsal surface of the muscle-mass, a large and distinctly marked bundle, the superficial fibers of which diverge considerably, running forward and mesially. The anterior fibers of the bundle are inserted on the postero-mesial face of the second infrapharyngobranchial, near its dorsal edge; the posterior fibers are inserted in a median longitudinal sucker-like formation that forms part of the anterior transversus. The muscle was innervated, in the first specimen examined, by branches of a nerve that arose from the ganglionic swelling on the second vagus, the same nerve innervating also the obliquus dorsalis of the third arch and the two transversi dorsales. This apparent innervation of a muscle associated with the second arch by a branch of the nerve of the third arch seeming unusual, the innervation was again carefully traced in a second specimen. In this fish the branch in question arose from the second vagus where that nerve separated into its three principal divisions, that is, at some considerable distance distal to the ganglion of the nerve. Close to the root of the branch the second vagus received an anastomosing branch from a nerve that arose from the main truncus of the united vagus nerves, proximal to the point where they separated one from the other, and hence proximal to the ganglia of the several parts. The remaining part of this commissural nerve anastomosed with the third and fourth vagi. The fibers of a part of that part of the nerve that anastomosed with the second vagus apparently entered the motor branch here under consideration, the rest of the fibers going to the ramus posterior of the nervus. If this commissural nerve contained motor fibers, those fibers might, accordingly, have belonged in part to the first vagus, and hence would naturally innervate a muscle developed in apparent connection with the arch of that nerve.

The obliquus dorsalis of the third arch (*Od. III.*) arises from the anterior half of the dorsal surface of the proximal articular head of the third epibranchial, from the mesial edge of the supra-

pharyngeal process of the same bone, and from a tendinous line that extends a short distance mesially from the process, along the posterior edge of the proximal articular head of the fourth epibranchial. None of the fibers of the muscle arise directly from the latter bone. The muscle runs forward and mesially, and then forward, having a curved mesial edge and terminating in a point directed forward. It is inserted along the mesial edge of the anterior half of the dorsal surface of the third infrapharyngobranchial, the surface of origin lying mesial to the ridge along the middle of the dorsal surface of the bone, and extending almost to its anterior end. The anterior end of the muscle lies ventral to the transversus anterior. It is innervated by branches of a nerve that arises from the second vagus, the same nerve innervating also the obliquus of the second arch, as described above.

No obliquus dorsalis could be identified on the fourth arch.

The Transversus Dorsalis Anterior (*Tda*) forms, with the obliqui of the second pair of arches, a single muscle-mass, as already stated. Like the obliqui of those arches, it arises, on each side of the head, from the dorsal surface of the proximal articular head of the second epibranchial, its anterior fibers running forward and mesially, its posterior fibers directly mesially, or mesially and slightly backward. The ventral fibers of the muscle cross the middle line of the head and are inserted on the corresponding portions of the second epibranchial of the opposite side. The muscle is thus much wider in the median line of the head, than at its lateral ends, its rounded anterior edge reaching forward nearly to the level of the anterior ends of the second infrapharyngobranchials. On its dorsal surface, in the middle line, there is a longitudinal, sucker-like, tendinous membrane, which forms part of the muscle and clasps, or is inserted on, the rounded inferior surface of the posterior half of the parasphenoid. Into this membrane, and also in part directly onto the parasphenoid, a large part of the fibers of the muscle have their insertion, the surface of insertion extending dorsally slightly beyond the dorso-lateral edge of the parasphenoid, on each side, onto the adjoining edges of the petrosal and basioccipital (Fig. 11). On the ventral surface of the muscle a similar but much more delicate membrane attaches the muscle to the inner surface of the skin of the roof of the

mouth. The muscle fibers themselves are not here inserted directly, either on the skin, or on the membrane, for the membrane can be removed from the muscle without tearing it. The dorsal, sucker-like membrane can not be so removed without cutting the muscle fibers. The muscle bulges downward in the middle line, a longitudinal median ridge being thus formed on its ventral surface. The muscle crosses dorsally the anterior end of the third obliquus, and its anterior edge lies immediately posterior to the transverse groove, already described, that connects, on the roof of the mouth, the anterior end of the branchial cleft that lies between the hyoid and first branchial arches of one side of the head with the corresponding cleft on the opposite side. The muscle is innervated by branches of the nerve that innervates the second and third obliqui.

The Transversus Dorsalis Posterior (*Tdp*) arises from the posterior portion of the dorsal surface of the proximal articular head of the third epibranchial, and from the dorsal surface of the third infrapharyngobranchial anterior to the mesial end of that epibranchial, the latter surface of insertion lying mesial to the posterior end of the ridge along the middle of the dorsal surface of the infrapharyngobranchial. The fibers of the muscle all run across the middle line of the head to the corresponding surfaces on the opposite side. The muscle, like the anterior transversus, is much wider in the middle than at its ends, its anterior edge projecting strongly forward in the middle line of the head, while its posterior edge has a wavy outline, projecting backward at first and then slightly forward in the middle line. The lateral ends of the muscle lie ventral to the posterior ends of the third obliqui. Its middle part lies dorsal to the anterior ends of the retractores arcuum branchialium dorsales. From the hind edge of the muscle, near the middle line, a small bundle of fibers runs laterally and backward on each side, and joins and fuses with the constrictor of the œsophagus. The muscle is innervated by a branch of the nerve that innervates the third obliquus.

The Retractores Arcuum Branchialium Dorsales (*Rbad*) are two in number, one on each side of the head, instead of but a single muscle as in *Amia*. The muscle, on each side, arises from the ventro-lateral surface of the third and fourth vertebræ, runs

directly forward, passes ventral to the transversus dorsalis posterior, and is inserted, ventral and mesial to that muscle, on the mesial edge of the anterior end of the fourth infrapharyngobranchial and on the posterior end of the third infrapharyngobranchial. It is innervated by branches of a nerve that has its apparent origin from the fourth vagus near the ganglion of that nerve, or from that ganglion itself. When carefully traced proximally, beyond its apparent origin, this nerve seems to receive a large part of its fibers from the third or second vagus nerves, a part of its fibers also coming from the commissural branch that arises from the main truncus of the united vagi and has been referred to in describing the innervation of the obliquus dorsalis of the second arch.

The Adductores Arcuum Branchialium are two in number, one on the fourth arch and one on the fifth. The adductor of the fourth arch is a small muscle lying in the angle between the epibranchial and ceratobranchial of its arch. It is apparently innervated by branches of that branch of the anterior nerve of the arch that passes over the antero-lateral edge of the arch onto and along the oral surface of the ventral part of the arch; that is, by a branch of the ramus posttrematicus of the third vagus.

The adductor of the fifth arch is a short, stout muscle which arises from the dorso-lateral surface of the fifth ceratobranchial, near its posterior, pointed end, and is inserted mainly on the inner surface of the small piece of cartilage that represents either the epibranchial or infrapharyngobranchial of the fifth arch. Some of the fibers of the muscle extend forward beyond this element of the fifth arch onto the adjoining articulating ends of the ceratobranchial and epibranchial of the fourth arch. It is apparently innervated by branches of that branch of the fourth vagus nerve that innervates the fifth interarcualis dorsalis.

The Interarcuales Ventrales are represented in *Scomber* by rudimentary obliqui ventrales, by two pharyngo-claviculares and a pharyngo-hyoideus on each side of the head, and by two transversi ventrales. The ventral interarcual ligaments, found so well developed in *Amia* and there considered as the true interarcual muscles of the fish, are not found in *Scomber;* or, if found, they are represented by ligamentous tissues only which extend from arch to arch along the basal line.

The Obliqui Ventrales of the first two arches are simply a few muscle fibers, or degenerate muscle tissue, filling the concave, ventral surfaces of the hypobranchials of their arches, and being covered externally by tendinous tissue that forms a part of the muscle. This tendinous tissue arises, on each arch, from the ventral surface of the distal end of the hypobranchial of the arch, and is inserted on the distal end of the ceratobranchial immediately beyond the cartilaginous end of that element. The tendon on the first arch is always double, that on the second arch occasionally so.

The obliquus ventralis of the third arch arises from the ventral surface of the large laminar process of the third hypobranchial, and from the ventral surface of the element itself lateral to that process. Its fibers run laterally and slightly backward and are inserted on a tendon which forms along the antero-lateral edge of the muscle. This tendon runs laterally and backward, parallel to the antero-lateral edge of the hypobranchial, and is inserted on the antero-lateral corner of the distal end of the ceratobranchial of the arch, the surface of insertion lying immediately proximal to the cartilaginous tip of the element.

The obliquus ventralis of the fourth arch arises from a tendinous band which extends, in a curved line, from the posterior end of the ventral edge of the large laminar process of the third hypobranchial of one side of the head, at first backward, then mesially across the middle line of the head, and then forward to the corresponding end of the hypobranchial of the opposite side. At the point where this tendon crosses the middle line of the head it is attached to the cartilaginous, posterior end of the third basibranchial. The fourth obliquus arises by tendon from this tendon, runs backward and slightly outward and is inserted on the anterior portion of the ventral edge of the scoop-shaped distal portion of the fourth ceratobranchial. The muscles of opposite sides of the head, at their origins, touch each other in the middle line. Although not having at all the same insertions, these muscles of *Scomber* seem to correspond to the muscles called by Vetter, in *Esox,* the pharyngo-arcuales.

The first, second and third obliqui are each innervated by branches of the nerves of their respective arches, undoubtedly by the ramus anterior of the arch concerned, though branches from

the ramus posterior also penetrated the muscles; this being more particularly the case on the second arch. The obliquus of the fourth arch seemed to be innervated by the ramus anterior of the third arch instead of by that of the fourth arch.

The Transversus Ventralis Anterior arises from the concave, mesial surface of the spoon-shaped anterior end of the fourth ceratobranchial of one side of the head, and extends across the middle line of the head to the corresponding surface of the ceratobranchial of the opposite side. The line of origin lies dorsal to the line of insertion of the fourth obliquus, and the muscle lies ventral to the anterior ends of the ceratobranchials of the fifth arch, curving downward to pass below them. Its innervation, like that of the obliquus of the fourth arch, could not be satisfactorily determined. It seemed to be innervated by the ramus anterior of the third arch rather than by that of the fourth arch, but the latter nerve ran forward close to it, along its dorsal surface, and delicate branches, that perhaps innervated it, may have been missed in the dissection.

The Transversus Ventralis Posterior, called by Vetter the pharyngeus transversus in the teleosts described by him, is a flat, thin muscle, which arises from the mesial surface of the ventral process or wing of the fifth ceratobranchial, and is inserted, with its fellow of the opposite side of the head, on a median, longitudinal tendon. The dorsal edge of this median tendon projects upward, as a ridge, between the mesial edges of the two pharyngeal bones, and between two small, anterior, longitudinal prolongations of the muscles of the œsophagus, to which it gives insertion. Anteriorly the median tendon separates into two parts, each of which is inserted on the fifth ceratobranchial of its own side of the head, at the anterior end of the mesial surface of the ventral process or wing of the bone. The point of insertion of the tendon lies anterior to the surface of origin of the transversus, and antero-mesial to the surface of insertion of the pharyngo-clavicularis externus.

The muscle is innervated by a branch of the nerve of the fifth arch, that is, by a branch of the ramus posttrematicus of the fourth vagus nerve.

The anterior end of the Constrictor Œsophagei shows several muscles either in process of absorption or in process of differentiation, whichever it may be. The muscle already described as the

interarcualis of the fifth arch, the small posterior bundle of the transversus dorsalis posterior, and the longitudinal muscle fibers that extend forward between the two fifth ceratobranchials, all belong to this class. In addition to these muscles there is a broad, flat muscle-bundle inserted along the posterior edge of the proximal articular head of the fourth epibranchial, and a broad and important longitudinal prolongation between the posterior dorsal pharyngeal bones. The former muscle, which is only differentiated from the constrictor œsophagei on the dorsal surface of the œsophagus, is continuous, along its entire lateral edge, with the so-called interarcualis of the fifth arch. The longitudinal anterior prolongation of the constrictor runs forward between and ventral to the retractores arcuum branchialium dorsales, and ventral to the transversus dorsalis posterior. It is inserted, in part, along the mesial edge of each pharyngeal bone, and in part it continues forward between those bones as a thin layer of longitudinal fibers which gradually disappear.

The Pharyngo-Claviculares and Pharyngo-Hyoideus form, on each side of the head, a group of three flat muscles inserted along the ventral edge of the ventral process or wing of the fifth ceratobranchial. All three pull the pharyngeal bone downward; the hyoideus pulling it downward and forward, the claviculares downward and backward.

The pharyngo-hyoideus (*Ph*) is the anterior and external muscle of the group. It arises from the dorsal edge of the posterior part of the sternum, runs upward and backward, and is inserted along the anterior half of the ventral edge of the ventral wing of the fifth ceratobranchial. It is tendinous both at its origin and at its insertion, and is crossed, not far from its origin, by a narrow tendinous line which extends entirely through the muscle. Directly internal to, and in contact with this tendinous line the truncus arteriosus runs forward and slightly upward. About half way between this tendinous line and the upper end of the muscle there is a tendinous patch on the external surface of the muscle. The muscle either pulls the pharyngeal bone downward and forward, or the sternum upward and backward. Its innervation could not be satisfactorily determined, but it seemed to be by a branch of the ramus posttrematicus of the second vagus. A delicate terminal

branch of the posttrematic branch of the fourth vagus also comes into relations with it and may in part or wholly innervate it.

The pharyngo-clavicularis externus (*Pce*) arises in a slight depression on the antero-lateral surface of the antero-lateral plate of the clavicle, approximately at the ventral third or quarter of that bone. It lies, at its origin, internal to the dorsal edge of that part of the sterno-hyoideus of its side of the head that arises from the lateral surface of the clavicle, but external to the corresponding edge of that part of the muscle that arises from the mesial surface of the bone. It runs upward and forward, and is inserted along the anterior two thirds of the ventral edge of the ventral wing of the fifth ceratobranchial, its anterior half here lying internal to the pharyngo-hyoideus. Across the outer surface of the muscle, at about one-third its length from its origin, there is usually a broad, irregular, tendinous line, not shown in the drawing.

The pharyngo-clavicularis internus (*Pci*) arises near the anterior edge of the mesial surface of the clavicle, at about the middle of its length. In some specimens there is, on this part of the clavicle, a cornice-like edge projecting backward, which, when found, gives origin to the muscle. The muscle runs upward and forward and is inserted along the posterior half of the ventral edge of the ventral wing of the fifth ceratobranchial, the anterior half or two thirds of the muscle here lying internal to the pharyngo-clavicularis externus. The fifth ceratobranchial, as shown in Fig. 49, lies considerably below its natural position.

The two pharyngo-claviculares are innervated by branches of the ramus anterior of the fifth arch, that is, by the ramus posttrematicus of the fourth vagus, the same nerve that innervates the transversus ventralis posterior, and possibly, though it seemed not probably, the pharyngo-hyoideus.

No Interbranchiales are described by Vetter in any of the teleosts examined by him. They are apparently represented, in *Scomber,* by two sets of muscles, one of which is greatly degenerated, and the other specialized in relation to the gill rays. The former are found on the anterior faces of each of the first four arches, along the bases of those gill filaments that lie at the outer, posterior angle of the arch. The muscle on each arch is repre-

sented by a line of degenerate muscle tissue, the fibers of which are arranged transversely to the arch, that is, lying in the same direction as the gill rays. This tissue extends a short distance, both distally and proximally, from the posterior angle of the arch, gradually diminishing in size and finally disappearing entirely.

The specialized muscles (Fig. 44) are found as a series of well-developed muscles lying along the inner face of each branchial ray, and hence radial to the arch. Each muscle arises, by a long tendon, from the outer surfaces of the bases of two adjoining rays of one row of filaments, runs outward between those rays, and, beyond their flattened basal portions, becomes a well-developed but slender muscle which passes between the rays from which it arises and is inserted on the inner face of a ray belonging to the opposite row of filaments. The rays of the two rows of filaments alternate, as already described, so that the ray on which the muscle is inserted lies opposite the interspace between the two rays from which it arises. The insertion of the muscle extends some distance along the shaft of the ray. The action of these muscles is simply to pull the two rows of filaments together.

The definite innervation of any of the interbranchiales could not be determined.

4. *Muscles Innervated by the Occipital and First Spinal Nerves.*

The Sternohyoideus (*Sh,* Fig. 49) of each side of the head arises from the inferior end of the corresponding clavicle. Running almost directly forward it is inserted on the posterior portion of the lateral surface of the sternum, the surface of insertion extending, in its ventral portion, about one half the length of the bone, but in its dorsal portion only about one third or one quarter of its length. The ventral edges of the muscles of the two sides of the head touch each other in the middle line through nearly their entire length. Their dorsal edges touch each other through about one third of their length. There is, however, no interchange of fibers between the two muscles. The ligament that connects the anterior ends of the clavicles of the two sides of the head with the hind end of the sternum lies between the two muscles.

The muscle of each side arises mainly from the antero-lateral

surface of the corresponding clavicle. Certain bundles of its fibers, however, arise from the mesial surface of the bone, and certain of them, both on its outer and on its inner surfaces, are continuous with the trunk muscles that lie immediately posterior to them. Certain other tendons or muscle-bundles come from the muscles of the ventral fin. The fibers of the muscle do not arise directly from the clavicle, but from a tough membrane that covers that bone. On the sternum they are inserted directly onto the bone without the intervention of such a covering membrane.

On the outer surface of each clavicle the surface of origin of the corresponding sternohyoideus occupies the full width of the bone from its ventral end upward and backward approximately to the level of the anterior edge of the pharyngo-clavicularis externus. There the hind edge of the surface of origin runs upward and forward, across the bone, to a point on a level with or slightly above the hind edge of the pharyngo-clavicularis externus. On the inner surface of the clavicle the surface of origin is much less extensive, extending backward, in its dorsal portion, to about the same level as on the outer surface of the bone, but occupying, ventrally, a much less important portion of the surface of the bone. The surface of insertion of the muscle occupies the full width of the posterior portion of the lateral surface of the sternum. The surface of insertion of the sterno-clavicular ligament occupies only the extreme postero-dorsal corner of the sternum, the ligaments running downward and backward from there to the anterior ends of the clavicles.

In young fishes the lateral fibers of the sternohyoideus are not continuous with the fibers of the trunk muscles that lie posterior to them, the fibers of the two muscles arising from, and being separated by, a tendinous band that lies along and is attached to this part of the postero-ventral edge of the clavicle. In old fishes, as stated above, certain muscle bundles of the sterno-hyoideus pass backward beyond this band and penetrate and have their insertion in the trunk muscles.

The muscle is always crossed by certain tendinous lines, and is imperfectly separated into several parts or bundles. Two of these somewhat separate bundles lie along the dorsal edge of the posterior portion of the muscle, one arising from the lateral surface of

the clavicle, external to the pharyngo-clavicularis externus, and the other internal to that muscle, either from the anterior edge or the inner surface of the clavicle. Both bundles fuse anteriorly with certain tendinous portions of the main body of the muscle which have their insertion near the dorsal edge of the lateral surface of the sternum. When these two bundles are removed a third bundle is exposed, lying on the dorsal portion of the lateral surface of the main muscle and crossed by a broad tendinous line. When it also is removed the main portion of the muscle is exposed. This latter part of the muscle is limited, both anteriorly and posteriorly, by broad tendinous bands or ends, and is crossed at fairly equal intervals by two tendinous lines, the lines beginning near the ventral edge of the muscle and running upward and backward about two thirds across it. These tendinous lines do not extend entirely through the muscle, but they are nevertheless, in all probability, the homologues of the two muscle septa that in *Amia* separate the muscle completely into three segments.

On the mesial surface of the muscle there are four somewhat separate bundles, two superficial ones and two deeper ones, the superficial bundles naturally lying mesial to the deeper ones. One of the two superficial bundles is crossed by a tendinous line, and is directly continuous with parts of the trunk muscles. The other arises from a large tendinous sheet that has its attachment to parts of the ventral fin. The two deeper bundles are inserted on the mesial surface of the clavicle, on a membranous formation that is continuous with the one that gives insertion to the muscle fibers on the lateral surface of the same bone.

The sternohyoideus is innervated by a nerve that arises from the trunk formed by the fusion of the three occipital nerves of the fish. This nerve enters the dorsal surface of the muscle and there breaks up into several branches.

The Anterior Muscle Segments of the Trunk of *Scomber* are much more distorted than those of *Amia*. If one of the first full segments be examined, the outer edge of each of the intermuscular septa bounding it is seen to run at first, for a short distance, forward and laterally from the mid-dorsal line. It then turns backward and laterally, at a sharp angle, and after coursing in a nearly straight line for a considerable distance turns again

sharply forward. The angle formed at this latter point may be called the dorso-posterior angle of the septum, the more dorsal angle being called the dorso-anterior one. Ventral to its dorso-posterior angle the septum curves gradually downward, and then downward and backward, to the line of the outer ends of the horizontal ribs, to one of which it is attached. Ventral to this rib it turns forward again, the septa between the anterior segments of the trunk here presenting a sharp angle, which, between the postrior segments examined, gradually becomes obtuse and rounded. Curving downward, and then downward and backward, the septum reaches a point lying approximately at the same distance ventral to the horizontal rib that the apex of its dorso-posterior angle lies dorsal to. There it turns sharply forward, forming an angle that may be called the ventro-posterior one, the apex of this angle lying directly ventral, or postero-ventral to that of the dorsal one. Ventral to this ventro-posterior angle, the septum runs forward and downward to the mid-ventral line of the body.

From this zigzag surface line the septum extends inward into the muscle mass, but, as in the adult *Amia,* it is pulled or pushed forward or backward, in several places, into more or less developed pocket-like portions. Of these pockets there are five in *Scomber.* The most dorsal pocket can be called the dorso-anterior one. It is a small pocket lying antero-internal to the dorso-anterior angle of the zig-zag surface septal line, and is directed forward, approximately in the line of the middle line of the supratemporal groove on the top of the skull. The second pocket can be called the dorso-posterior one. It is larger than the dorso-anterior pocket, lies postero-internal to the dorso-posterior angle of the surface septal line, and is directed backward, approximately in the line of the ridge of bone that separates the supratemporal and temporal grooves. The third pocket is considerably larger than either of the other two and can be called the dorso-median one. It is directed forward, approximately in the line of the middle line of the temporal groove, and occupies the entire space between the dorso-posterior angle of the surface septal line and the angle that marks the point where the septum is attached to the horizontal rib. The fourth pocket is, in the middle part of the trunk, as large as the third one, is directed forward, as that one is, and

occupies a position ventral to the horizontal muscle septum corresponding exactly to that of the third pocket dorsal to that septum. It can accordingly be called the ventro-median pocket. In the anterior segments it gradually diminishes in size, and even in the tenth muscle segment has largely disappeared. The fifth pocket, when found, is only slightly developed, is directed backward, lies internal to the ventro-posterior angle of the surface septal line, and can be called the ventro-posterior pocket. These several pockets all lie free in the muscle fibers of the adjoining segments, no ligamentous attachments of any kind being found in connection with them. The muscle fibers that have their attachments on the outer surface of the point of each pocket, are, however, more tendinous at their insertion than the other fibers of the segment, a tuft of fibers usually being found associated with the point of each pocket.

The mesial edges of the septa have a course approximately similar to that of their superficial edges, but they lie in front of the latter edges; in certain parts of their course considerably in front of them. In its mid-lateral part, each septum follows and is attached to the corresponding horizontal rib, that rib giving attachment also to the horizontal muscle septum. Ventral to this latter septum the mesial edges of the intermuscular septa follow, and are attached to, the ventral ribs of the vertebræ to which they belong. They do not, however, in those anterior trunk segments that alone were examined, follow those ribs to their distal ends. Shortly before reaching the distal end of the rib to which it belongs, each septum turns sharply forward, and, running downward and forward, crosses the next anterior rib close to its distal end.

Dorsal to the horizontal muscle septum, the mesial edge of each intermuscular septum runs upward and backward along the lateral surface of the vertebra to which it belongs, its line of attachment being along the ridge that represents the base of the spine-like part of the dorsal arch of the vertebra. It then passes onto the spine of the arch, and continues upward and backward nearly to its dorsal end. There it turns backward and slightly upward and crosses the distal end of the next posterior dorsal arch. At this point it lies close to the next posterior septum of the trunk, and is connected with that septum by fibrous tissue, the intervening

muscle segment thus here being pinched off, no muscle fibers here reaching to the mid-vertical plane of the body. Continuing its course across this first posterior dorsal arch, the septum approaches somewhat the line of the next or second posterior dorsal arch, but, before reaching that arch, turns upward and backward approximately parallel to it and reaches the level of the line of the dorso-posterior pockets. There it turns sharply forward and slightly upward, crosses the lines produced of three or four dorsal vertebral arches, and, having reached the level of the dorso-anterior pocket of the septum, turns sharply backward and continues in that direction to the dorsal surface of the body.

The first complete intermuscular septum, that is, the first one that extends from the mid-dorsal to the mid-ventral line of the body, is, as already stated in an earlier work (No. 6), the sixth. The ventral part of the fifth septum, as seen on the inner surface of the body wall, extends in a nearly straight line, from the vertebræ to which it is attached, downward and backward until it almost meets, at approximately a right angle, that part of the sixth septum that lies distal to its ventro-posterior angle. There it ends, so far as could be determined. The fifth septum thus does not present a ventro-posterior angle, or its segment a corresponding pocket. In the ventral half of this part of its length this septum follows the posterior portion of the ventral edge of the large, posterior accessory shoulder-girdle bone, the postero-ventral, spine-like end of that bone lying in the inner edge of the septum.

The mesial edge of the fourth septum extends downward and backward from the vertebral column less than one half as far as the fifth septum, its ventral end running onto the ventral edge of the large, posterior accessory shoulder-girdle bone somewhat in front of the point where the fifth septum reaches it. The third, second and first septa all extend but a short distance below the horizontal septum, their ventral portions forming, with that septum, small muscle pockets.

The fifth septum in *Scomber* thus seems to mark the anterior limit of the muscle segments that lie completely posterior to the clavicle. According to Corning (No. 20) this septum marks, in all teleosts, the posterior limit of the muscle segments that take part in the formation of the "Hypoglossusmusculatur." It has

its attachment, in *Scomber,* to the second vertebra and to the horizontal rib that articulates with that vertebra. The nerve that innervates the muscle segment immediately in front of it issues through the foramen that perforates the first vertebra, and this nerve is, apparently, the most posterior one that takes any part in the innervation of the Hypoglossusmusculatur. It is also either the most posterior one, or the next to the most posterior one, that can take any part in the formation of the nervus pterygialis.

The fifth intermuscular septum of *Scomber* thus corresponds closely, in its relations to the clavicle and to the spinal and occipital nerves, to the same septum in *Amia.* But in *Scomber* this septum has its attachment to the second vertebra, while in *Amia* it is attached to the last occipital arch. What this may indicate has already been discussed in an earlier work (No. 6) and will be again referred to in considering the spinal and occipital nerves.

In front of the fifth muscle segment the septa and segments are incomplete, and the anterior ones irregular also.

The dorsal portions of the fourth and third septa are regular, the dorso-anterior angles and associated septal pockets of both running forward into the supratemporal groove. The second septum is irregular. It has a large dorso-median pocket extending forward in the line of the temporal groove, and a small dorso-posterior pocket extending backward in the line of the corresponding pockets in the more posterior septa. It has, however, no dorso-anterior pocket, its anterior end being attached in part to the hind end of the bony ridge that separates the temporal and supratemporal grooves, and in part extending forward along the bottom of the latter groove. The bony ridge that separates the temporal and supratemporal grooves is thus an anterior extension of the line of the second septum.

The first septum has but one pocket, the dorso-median one. The septum is attached to the pedicle of the suprascapular, and with that pedicle to the posterior process of the intercalar. From there it runs upward and then mesially along the hind edge of the temporal groove, to the hind end of the posterior process of the exoccipitale. From this line of attachment a large pocket extends forward into the temporal groove. At the dorsal end of the

septum, just before it becomes attached to the hind end of the exoccipitale, there is a slight indication of a dorso-posterior pocket. The first septum joins at this point, and becomes fused with, the second septum, the first septum lying, apparently, ventral to the antero-mesial process of the suprascapular and the second septum dorsal to that process.

On the dorsal surface of the dorso-median pocket of the first septum, that is, morphologically, on its anterior surface, there are two fibrous ridges which project upward and come to the outer surface of the muscle mass that fills the temporal groove. The outer edges, so exposed, of these ridges, form two slightly curved lines, parallel in general direction but with the hollows of their respective curves presented toward each other. The posterior halves of these lines lie dorsal to the two splint-like anterior processes of the suprascapular. Between them there is a third longitudinal fibrous line. The anterior half of this third line is attached, along its deeper edge, to the bottom of the temporal groove, the line of attachment extending backward to the point where the bottom of the groove changes abruptly from a higher to a lower level. Posterior to that point the fibrous band projects backward into the muscle fibers of the first muscle segment, giving insertion to that part of those fibers that lie between the two fibrous ridges of the first intermuscular septum. This middle fibrous line thus represents a part of the anterior fibrous covering of the trunk muscles, and, in the nomenclature used by me, would have to be designated as septum zero. Another part of this same formation is attached to the hind edge of the posterior process of the squamosal, and, extending backward, covers the outer surface of a part of the anterior end of the trunk muscles.

The pedicle of the suprascapular is thus seen to lie in the first intermuscular septum; the two slender, pointed anterior processes of the bone to lie in the lines of the two fibrous ridges on the antero-dorsal surface of the same septum; and the antero-mesial process of the bone to lie between the first and second septa. In *Amia* the pedicle of the suprascapular lies immediately in front of the first septum. The septa in *Scomber* thus agree, in this respect, as well as in their apparent relations to the clavicle and to the occipital and spinal nerves, with the corresponding septa in *Amia*.

In *Scomber* there is but one occipito-supraclavicular ligament, and it lies in the third septum. In *Amia* (No. 4, p. 708) there are two of these ligaments, one lying in the fourth septum and the other in the fifth septum. In *Scomber* the first two horizontal ribs are found in these fourth and fifth septa. As these two ribs in *Scomber* lie in, or immediately below, the horizontal muscle septum, and are accordingly directed toward the lateral canal of the body, they thus have the same general position and direction that the two ligaments in *Amia* have. If then the first two free vertebræ of *Scomber* are represented in *Amia* by the last two occipital vertebræ (No. 6), the two associated horizontal ribs, in *Scomber,* would seem to be naturally represented, in *Amia,* by the occipital ligaments. The occipital ligament of *Scomber* would then be another more anterior, but homodynamous structure, not perceptibly differentiated in *Amia.*

5. *Muscles of the Pectoral Fin.*

There are, in *Scomber,* three lateral and three mesial muscles associated with the pectoral fin.

The largest of the lateral muscles (*Abds,* Figs. 45–49) lies superficial to the other two, and almost completely covers them. It arises from a median portion of the postero-mesial surface of the antero-lateral wall of the clavicle, the surface of origin extending nearly the full length of the grooved part of the bone. Superficial to the surface of origin of this muscle the same surface of the clavicle gives insertion to portions of the trunk muscles, and internal to it, to a portion of the fibers of a deeper muscle of the fin. All of the fibers in the dorsal part of the superficial muscle run directly upward and backward, in a nearly parallel course, toward the base of the fin, and, becoming tendinous, and separating more or less completely into separate bundles, are inserted on the eminences on the proximal ends of the lateral half rays of the fin. In this part of the muscle there are, often, more separate tendinous ends than there are dermal rays in the fin, two tendons, or parts of two tendons, being naturally inserted, in such case, on certain of the rays. The ventral fibers of the muscle are inserted on a long, curved tendinous formation that forms part of the muscle. This tendon, or aponeurosis, begins near the ventral end of

the muscle, not far from its hind edge, and, running upward and backward, soon reaches the hind edge of the muscle, along which it continues upward to the dorsal end of the muscle where it is inserted on the postero-ventral dermal ray of the fin. A large part of the muscle thus acts, directly, on this one ray alone. The muscle, in contracting, gives to the rays a motion downward and backward, in the plane of the fin, and also a motion laterally, at right angles to that plane, its principal action being undoubtedly the latter.

This superficial muscle of the fin is, in the nomenclature adopted by McMurrich in his descriptions of *Amiurus* (No. 49, p. 332), the abductor superficialis. In the nomenclature adopted by Klaatsch in his description of *Polypterus* (No. 44) it would seem to be the extensor superficialis, but it is also, at the same time, a depressor. According to the definition of angular movements given by Thane (No. 61, Vol. II., Pt. II., p. 151) it would seem to be mainly a flexor, but also an adductor. Wishing to avoid the introduction of new names, pending more extended investigations, it seems to me best, for the present, to call it, after McMurrich, the abductor superficialis.

The next largest lateral muscle, in *Scomber* (*Abdp*), lies internal to the superficial abductor muscle, its postero-ventral edge, however, projecting considerably beyond the corresponding edge of the superficial muscle and thus having, in this part, an exposed lateral surface. Its surface of origin occupies all of the lateral surface of the procoracoid excepting only its dorsal edge, and all of the lateral surface of the membrane that fills the large fenestra between the procoracoid and the clavicle. Anteriorly and ventrally the surface of origin extends onto the adjoining lateral surface of the mesial wall of the clavicle, and dorsally it extends onto the adjoining lateral surface of the scapulare. Its fibers first spread somewhat, from their points of origin, and then converge, and, becoming tendinous, are inserted on the lateral eminences on the proximal ends of the dermal rays, immediately internal to the tendons of the superficial muscle. The tendinous distal end of the muscle is, however, not as distinctly separated into separate tendons as the corresponding part of the superficial muscle is. In contracting, the muscle has much the same action upon the fin as

the superficial muscle has, but it acts less as a depressor and more as an abductor. It is, in McMurrich's nomenclature, the abductor profundus of the fin.

The third lateral muscle (*Lc*) is a long and somewhat S-shaped one. It arises from the bottom of the grooved surface of the clavicle, its surface of origin extending from the ventral end of the bone nearly to the dorsal end of the grooved portion, and occupying parts of both walls of the groove. Its ventral end is exposed ventral to the ventral edge of the superficial abductor muscle. Its fibers converge strongly and are inserted on a long tendinous aponeurosis, which begins almost at the ventral end of the muscle and lies nearer its posterior than its anterior edge. Distally the muscle becomes entirely tendinous and is inserted on the anterior surface of the shaft of the mesial one of the two bones that together form the first dorsal ray of the fin, the surface of insertion lying immediately distal to the proximal end of the half ray. It is, accordingly, the levator muscle of the fin; that is, it raises the dorsal edge of the fin, and spreads the rays one from the other. Near its distal end it traverses a tendinous formation that arises from the curved line that marks the dorsal continuation of the grooved part of the clavicle. The fibers of this formation converge toward the proximal end of the dorsal edge of the fin, and are inserted on the dermal rays, on the two abductor muscles, and on the adjoining parts of the primary girdle. The tendon is traversed by a well formed, closed canal, which lodges the distal end of the levator muscle, and, holding it, as in a pulley, greatly adds to its efficiency.

The nerve that supplies these three lateral muscles issues through the foramen in the scapulare, sends one branch at once to the dermal parts of the fin and another to the S-shaped levator muscle, and then, running downward between the two abductor muscles, sends branches to them also.

The ventral ends of the lateral muscles lie internal to the anterior part of the trunk muscles, which muscles here have their insertion on the clavicle superficial to the muscles of the fin.

The mesial muscles of the fin, like the lateral muscles, are represented by three muscles, one of which is a superficial muscle and the other two deeper ones. The superficial muscle, and the dorsal

one of the two deeper ones, are usually more or less continuous, and are undoubtedly parts of a single muscle in process of separation.

The superficial muscle (*Adds,* Figs. 50, 51), which naturally lies mesial to the other two, is a broad, flat rectangular muscle. It arises from the anterior edge of the dorsal part of the mesial surface of the clavicle, the surface of origin beginning near the dorsal end of the antero-dorsal process of the bone, and extending downward somewhat below the level of the central point of the scapulare. Its fibers run almost directly backward, and, becoming tendinous near their distal ends, separate into separate tendons each of which is inserted on the eminence found on the mesial half-bone of each of the dermal rays immediately distal to its proximal end. None of the tendons of the muscle are usually inserted on either of the first five most dorsal rays of the fin. The action of this muscle is, as shown by its origin and insertion, to pull the fin mesially and downward against the trunk. It is the adductor superficialis of McMurrich's descriptions.

The two deeper mesial muscles (*Addp*) are also adductor muscles. The more dorsal one of the two is a triangular muscle, the surface of origin of which lies, in its ventral two thirds, immediately internal to and anterior to that of the superficial muscle. Dorsal to the latter muscle the surface of origin of the deeper muscle extends upward and forward along the dorsal edge of the postero-dorsal process of the clavicle, for about one half its length. The muscle, as already stated above, is usually somewhat continuous with the superficial muscle. Its fibers converge strongly, and, separating into several bundles, are inserted by tendons on those rays that lie between the propterygial ray and the most dorsal one of those rays that give insertion to the tendons of the superficial muscle; the insertions being, like those of the latter muscle, on the eminence found on the mesial half-bone of each of the rays concerned. No part of this muscle is inserted on the propterygial ray. The muscle thus pulls the dorsal edge of the fin mesially without acting directly upon its ventral portions.

The ventral one of the deeper muscles is a flat muscle larger than either of the other two. It has a large surface of origin, arising from the mesial surface of the ventral half of the scap-

ulare, from the corresponding surface of the dorsal two thirds of the procoracoid, from the adjoining surface of the clavicle, and from the dorsal half or two thirds of the mesial surface of the membrane that fills the fenestra between the clavicle and procoracoid. Its fibers run upward and backward, and, becoming tendinous, are inserted on the proximal ends of all of the dermal rays excepting sometimes certain of the ventral ones.

The nervus pterygialis enters the muscles of the fin at the ventral edge of the superficial adductor muscle. There it turns upward between the superficial adductor and the ventral one of the two deeper muscles, until it reaches the dorsal edge of the latter muscle, where it turns outward, that is laterally, between the two deeper muscles, and enters its foramen in the scapulare. There it turns downward between the superficial and deeper lateral muscles, as already stated. Branches are given by it to each of the three mesial muscles as well as to the lateral ones.

Neurology.

1. *Brain.*

To show the apparent origins of the several nerves, and the relations of their roots to the different parts of the brain, a superficial examination of the latter structure was necessary, and two views of it are given. It presents the usual teleostean form and characteristics, and varied greatly in the form and relative proportions of its different parts in different specimens; but whether this was due to actual variations in the structure, or to the effect of reagents, was not investigated.

The optic lobes are large, having in this a direct relation to the largely developed eyes. They project laterally considerably beyond the other parts of the brain, and overhang and lie directly upon the roots of the third, fourth, fifth and seventh nerves. They also overhang the anterior parts of the membranous ear, the anterior semicircular canal, on each side, being pushed laterally and backward into a strongly inclined position. The anterior part of this semicircular canal, on each side, lies against and is slightly embedded in, the lateral surface of the optic lobe, that surface of the lobe being presented laterally, ventrally, and

backward. The dorso-posterior part of the same canal lies against and is deeply imbedded in the lateral face of the cerebellum. The posterior two fifths, or two thirds, of the united optic lobes, according to the specimen examined, are overlapped dorsally, in the middle line, by the anterior two thirds of the cerebellum, and they themselves slightly overlap dorsally and laterally the hind end of the forebrain.

The forebrain, at its hind end, is about one half as wide and one half as thick as the midbrain with its optic lobes, and lies in front of the dorsal half of the latter structures. It is separated, dorsally, by a deep fissure from the optic lobes, and ventrally is continuous with the midbrain. The optic nerves arise immediately ventro-posterior to it, from what, in lateral views, appears as the ventral half of an anterior surface of the midbrain. What I take to be, in Studnicka's (No. 72) terminology, the posterior lobes of the forebrain, are strongly reflexed, and what are apparently simply the lobi olfactorii lie immediately in front of them. The flat membranous roof of the forebrain extends from the lobi posteriores forward onto the lobi olfactorii, but its limits could not be traced. In front of the lobi olfactorii the bases of the olfactory nerves are always somewhat enlarged and rounded, and in all the fresh, or freshly preserved, specimens this part of each olfactory nerve presented strongly the external appearance of a bulbus. In certain specimens this part of the nerve had even a greater diameter than the lobus from which it arose. Whether this conformation is due simply to the lateral pressure of the greatly enlarged orbits, or represents some differentiation in the olfactory parts of the brain was not investigated.

The cerebellum, as seen in dorsal views, is oval in outline, in its central part, and varies considerably in length, relatively to other parts of the brain. Its anterior end projects forward and lies directly upon and between the optic lobes, which it overlaps for from two fifths to two thirds their length. Lateral to its posterior portion there is, on each side, a pronounced swelling which is apparently the homologue of what Wright (No. 80, p. 354) considers, in *Amiurus,* as the tuberculum acusticum. Herrick considered this same structure in the Siluridæ, *Amiurus* included (No. 37, p. 224), as a homologue in part of the restiform bodies.

The posterior halves of these swellings, in *Scomber,* are separated by a narrow fissure from the overlying hind end of the cerebellum, the fissure extending transversely, in a curved direction, from one side of the brain to the other, and separating the ventral surface of the hind end of the cerebellum from a narrow bridge of nervous matter which bridges over the anterior portion of the fourth ventricle. A similar bridge, said to be of gray matter, is said by Wright to connect the so-called tubercula acustica in *Amiurus,* but his drawing of the brain of that fish seems to show the bridge and the hind end of the cerebellum continuous, without a separating fissure. The same is true of Herrick's drawings. The bridge in *Scomber* is of variable thickness, being in some specimens nearly as thick as the overlying part of the cerebellum, and in others considerably thinner. It lies directly dorsal to a second bridge of nervous matter which apparently represents the lobi trigemini of Wright's descriptions, and the trigeminal tubers or tuberosities of Herrick's. In Goronowitsch's descriptions of *Lota* (No. 32) the bridge formed by the Cerabellarleisten seems to correspond to this second bridge in *Scomber.*

Immediately posterior to the bridge formed by the lobi trigemini, if they be such, are two other lobes, probably the lobi vagi. In certain specimens they meet and touch in the medial line, but without being fused. In others they are separated by a median cleft.

Posterior to the lobi vagi there is a small swelling on each side, marking the posterior limit of the fourth ventricle.

The hypoaria are large and flat, and touch in the middle line throughout the larger part of their length. Their general shape and disposition is shown in Fig. 65. Anteriorly they diverge, leaving a space in which is found the hypophysis, which is round in outline and usually with a bluntly pointed ventral end. No separate saccus vasculosus was found in any of the several dissections made. Whether it was removed in the dissecting, or formed part of the so-called hypophysis, was not determined.

2. *Nervus Olfactorius.*

The Nervus Olfactorius (*ol*) arises from the anterior end of the lobus olfactorius, and runs at first almost directly forward in that anterior extension of the cranial cavity that is enclosed in the

dorsal portion of the membranous interorbital septum. In this part of its course it is closely pressed against its fellow of the opposite side of the head, and is oval in section, the long axis of the oval being directed vertically and being about twice as long as the transverse axis. The base of each nerve is considerably enlarged, as already stated, and is often somewhat rounded as if there were here a ganglionic formation, an appearance too strongly marked not to have especial attention called to it.

At about the middle of the orbit the olfactory nerve, on each side, turns laterally, pierces the corresponding half of the membranous interorbital septum and reaches the lateral surface of that structure. Turning slightly downward and laterally it continues its forward course, running dorsal to the obliqui muscles at their origins, and reaches the posterior opening of the olfactory canal through the antorbital process. Traversing that canal it issues, by its anterior opening, into the nasal fossa, and reaches the nasal epithelium. This epithelium is, in *Scomber,* placed somewhat vertically, instead of horizontally, and the olfactory nerve seems in consequence to have been twisted outward, that is, upward and laterally. This is indicated by a small and somewhat separate bundle of fibers that crosses the dorsal surface of the nerve, from within upward and laterally, during that part of its course that lies outside the cranial cavity. This bundle could not be traced on the intracranial part of the nerve, but it seems, nevertheless, to be the homologue of the ventro-median bundle described by me in *Amia* (No. 4, p. 511). No indication whatever of a separate nerve, such as Pinkus describes in *Protopterus* (Nos. 52 and 53), was found. It is however to be remembered that no sections whatever were made of *Scomber.*

As the olfactorius passes through the antorbital process it is accompanied by three vessels, apparently veins, coming from the nasal pit. One of these vessels (Fig. 61) runs backward dorsal to the obliquus superior and rectus superior muscles, closely accompanying the nervus trochlearis, and at the hind end of the orbit, having passed ventral to the anterior end of the trigemino-facial ganglion and ventral to all the nerves that arise from that ganglion, enters the trigeminal opening of the trigemino-facial chamber in the petrosal. Traversing that chamber it issues at its posterior or

facial opening, and becomes the jugular vein. The other two vessels run backward ventral to the obliquus superior, but dorsal to the obliquus inferior, and then backward and downward mesial to the rectus internus. Having reached the lower edge of the latter muscle they turn upward and backward around that edge and around the corresponding edge of the rectus inferior, and passing antero-mesial and then dorsal to the rectus externus enter the eye-muscle canal by its orbital opening. Their further course could not be traced. They accompany, in their course through the orbit, the inferior branch of the nervus oculomotorius, and they are joined, before entering the eye-muscle canal, by a large vein that comes from the eyeball, the three veins apparently uniting to form a single vessel. The venous trunk thus formed, and its anterior continuation in the vein that comes from the eyeball, thus together correspond in position to the vein *ov* of my descriptions of *Amia*. In *Scomber* no communicating branch to the more dorsal orbital vein could be established, nor could it be determined whether or not the ventral vessel communicated with the corresponding vessel of the opposite side of the head, and supplied the hypophysis or saccus vasculosus, as in *Amia*.

3. *Nervus Opticus.*

The Nervus Opticus (*o*), on each side, issues from the cranial cavity antero-dorsal to the anterior edge of the basisphenoid, and, lying postero-ventral to the eye-stalk, runs forward and laterally to the eyeball. In issuing from the cranial cavity it pierces the interorbital membranes at the point where the unpaired interorbital septum spreads, on each side, to form or join the membrane that closes the orbital opening of the brain case. It is a large, strong nerve, enclosed in a tough cylindrical envelope, but the nervous matter itself is arranged in many folds inside the envelope. Stannius says that the nerve is found in the form of a folded band. The two nerves cross each other while under the ventral surface of the brain, sometimes one and sometimes the other having the ventral position. Whether there was here a commissure connecting the nerves, or any interchange of fibers, was not investigated. Stannius says there is a simple crossing of the nerves.

4. *Nervus Oculomotorius.*

The Nervus Oculomotorius (*ocm*) arises as a single strand, near the median line, from what is undoubtedly the floor of the mid-brain; the surface from which it arises seeming, however, in gross dissections, to be the extreme anterior end of the medulla rather than a part of the brain anterior to the medulla. The ventral surface of the medulla seems here to be continued forward beyond the lateral surface of the structure, and to form a somewhat conical surface, with a rounded anterior end which reaches almost to the middle transverse line of the optic lobes. This part of the brain is covered ventrally by the hypoaria, the nervi oculomotorii thus lying, at their origin, immediately internal to, that is, dorsal to those structures. From here each nerve runs at first forward and laterally and then forward, and issues from between the hypoarium of its side and the floor of the mid-brain at the antero-lateral corner of the hypoarium, between it and the hind edge of the tractus opticus. Continuing forward it issues from the cranial cavity by the olfactorius foramen, between the adjoining edges of the basisphenoid, alisphenoid and petrosal. Immediately after issuing from its foramen it separates into its inferior and superior divisions.

The superior division of the nervus (Fig. 66) is much the smaller of the two. It separates at once into two principal parts, one of which goes to the dorso-mesial, and the other to the ventro-lateral surface of the rectus superior muscle, the nerve innervating that muscle alone. It lies, at its origin, mesial to, or ventro-mesial to, the truncus ciliaris profundi.

The inferior division of the nervus is large, and separates at once into two portions, both of which turn mesially, downward and forward across the lateral surface of the rectus superior, between that muscle and the rectus externus. The most dorsal portion of the nerve soon separates into two parts, one of which enters and supplies the rectus inferior, the other running dorsal to that muscle and entering and supplying the rectus internus. Both parts break up into several branches as they approach their respective muscles, and both have a long, terminal branch. The terminal branch of the nerve that supplies the rectus inferior runs

outward along the edge of that muscle. The terminal branch of the nerve that supplies the rectus internus runs outward along, and innervates, the rudimentary muscle that lies immediately dorsal to, and seems to form part of, the internus.

The ventral portion of the inferior division of the nervus runs downward, posterior to the rectus inferior, and then forward ventral to that muscle, and ventral to the rectus internus, and enters and supplies the obliquus inferior.

The inferior division of the oculomotorius of *Scomber* thus supplies the same three muscles that it does in *Amia,* and it and its branches have the same relations to the several muscles of the eyeball and to the nervus opticus that they have in *Amia,* with the single exception of the branch that innervates the rectus internus. That branch, in *Scomber,* lies dorsal to the rectus inferior, while in *Amia* it lies ventral to that muscle. Just what this difference is will be readily understood if it be supposed that the rectus inferior instead of the rectus internus had, in *Scomber,* acquired an origin in the eye-muscle canal, the inferior muscle thus passing, at its origin, ventral to the rectus internus instead of dorsal to it. The arrangement in *Scomber* would then be exactly the same as in *Amia* excepting only in the order in which the branches that innervate the internus and inferior leave the inferior branch of the oculomotorius; or, otherwise stated, the innervation would be exactly the same, in the two fishes, if the inferior muscle of the one were an internus in the other. Sketches that I have of the eye muscles of *Esox, Gadus* and *Conger,* but which I have not yet controlled, show that that branch of the oculomotorius that supplies the rectus internus in those fishes has the same position, relative to the rectus inferior, that it has in *Scomber.* This arrangement may, therefore, be characteristic of all teleosts, and hence have some special significance.

The ciliary ganglion, in *Scomber,* is related to those two branches of the inferior division of the oculomotorius that supply the recti internus and inferior, rather than to the entire inferior division of the nervus. This will be fully described in connection with the nervus profundus.

5. *Nervus Trochlearis.*

The Nervus Trochlearis (*tr*) has its usual origin from the superior surface of the brain, there lying between the optic lobe of its side of the head and the overlapping cerebellum. It runs downward and forward internal to the hind end of the optic lobe and then forward between the ventral surface of the midbrain and the underlying hypoarium, lying dorsal or slightly lateral to the oculomotorius. Continuing forward across the tractus opticus it reaches its foramen, at the mesial edge of the alisphenoid, and issuing by it, into the orbit, runs forward dorsal, or dorso-mesial to all the muscles and nerves of the eyeball, lying ventro-mesial to the ramus ophthalmicus superficialis trigemini, as in *Amia*. It reaches the obliquus superior toward the origin of that muscle, having separated into two principal parts as it approaches it, and then breaks up into several branches which spread upward and downward on the ventro-mesial surface of the muscle. One long branch is sent backward and upward along the postero-ventral edge of the muscle, almost to its insertion.

No indication, whatever, of a communicating branch from this nerve to the ophthalmicus superficialis trigemini could be found; nor could any intracranial branches be found, such as Kingsbury (No. 43, p. 146) describes in *Necturus*.

6. *Nervus Abducens.*

The Nervus Abducens (*ab*) arises from the floor of the medulla as a single strand, lying, at its origin, antero-mesial to the point of origin of the acusticus and postero-mesial to that of the anterior root of the trigemino-facial complex. It runs at first forward and slightly laterally, and then directly forward onto the hind end of the ventral surface of the hypoarium. The nerve here becomes flattened, as if by pressure, and is slightly pressed into the hypoarium, thus forming a slight impress on the ventral surface of that organ. Before reaching the middle of the hypoarium it turns laterally and forward, at a well-marked angle, traverses its foramen in the horizontal wing of the petrosal, enters the eye-muscle canal, and is distributed immediately to the rectus externus, which it innervates. As the nerve approaches its foramen Mr. Nomura

always found a small strand which separated from the main nerve but was distributed, like the remainder of the nerve, to the rectus externus. It however ran forward a considerable distance along the muscle before entering it, instead of entering it at once, as the larger part of the nerve did.

7. *Trigemino-Facial Complex.*

The Radix Profundi, usually considered as a part of the trigemino-facial complex, arises from the brain separate and distinct from the other roots of the complex. It lies antero-mesial to the latter roots, runs forward and outward and enters a small ganglion (*gp*) while still inside the cranial cavity. This ganglion may be connected by a nervous strand, perhaps sympathetic, with the root of the nervus trigeminus. From the ganglion, which is evidently the homologue of the whole or a part of the profundus ganglion of *Amia,* a single nerve arises, which I have called the truncus ciliaris profundi. Immediately after leaving its ganglion this truncus traverses the profundus foramen in the petrosal, and enters the trigemino-facial chamber on the outer surface of that bone. Issuing from the chamber, by its trigeminal opening, the truncus separates, sooner or later, into two parts, one of which is the radix longa and the other the ciliaris longus, the manner and place of separation of the two parts varying in different specimens, and three strands often being found (Fig. 66), two of which together form the radix longa. Either the truncus ciliaris profundi alone, or both the truncus and the ciliaris longus, were always connected, by a variable number of strands, with a large sympathetic ganglion found intimately associated with the trigeminal nerves. Whether one or more of these strands represented the portio ophthalmici profundi of *Amia,* or not, could not be determined from dissection. They seemed however, from their course and general appearance, to be simply sympathetic fibers sent from the sympathetic ganglion to the ciliary ganglion and nerves. If this be so the portio ophthalmici profundi of *Amia* must either be wholly wanting in *Scomber,* or wholly fused with the trigeminus, those parts of the profundus ganglion and radix profundi that belong to it included. For the present it seems to me better to consider the nerve as wholly wanting in *Scomber,* as I was led to consider it to be in *Trigla* (No.

4, p. 538) ; or, if present, as represented by a few fibers, only, contained in the two or more communicating sympathetic strands. Whether it is wholly absent or wholly fused with the nervus trigeminus, the loss of the fibers belonging to it would naturally account for the small size, in *Scomber,* of the profundus root and ganglion.

It should here be noted that Hoffmann (No. 39, p. 287) says that, in *Acanthias* embryos of from 45—50 mm. in length, the Portio minor s. trigemini is a branch of the ramus ophthalmicus profundus. The ramus ophthalmicus profundus is said to be an independent nerve that arises from van Wijhe's ciliary ganglion, that ganglion being connected with the brain by a dorsal root that Hoffmann calls the thalamicus, the root and nerve together forming the thalamo-ophthalmicus nerve. The ciliary ganglion here referred to is said, after its formation, to fuse completely with the trochleo-trigeminus anlage, and later to anastomose with the nervus oculomotorius. This single ganglion in *Acanthias* thus seems to represent the profundus and ciliary ganglia, together, of my descriptions of *Amia,* and hence necessarily also the radix longa, which connects the two ganglia. It must also represent the two ganglia described by Mitrophanow (No. 46), in *Acanthias,* as the ciliary and oculomotorius ganglia, which, as already stated in my earlier work (No. 4, p. 537), are probably the homologues of the two ganglia of *Amia.* The nerve called by Hoffmann in *Acanthias* the Portio minor s. trigemini would therefore seem to be the homologue of the portio ophthalmici profundi trigemini of *Amia,* and not of the ramus ophthalmicus superficialis trigemini. The Portio major s. facialis of the nervus ophthalmicus superficial of his descriptions is naturally the ramus ophthalmicus superficialis facialis of my descriptions.

The radix longa (*rl*) of *Scomber,* after its separation from the ciliaris longus, is sometimes represented by one strand, and sometimes by two, one of which is probably sympathetic. It runs forward, or downward and forward, lateral to the rectus superior, between it and the rectus externus, and enters the ciliary ganglion. From this ganglion the ciliaris brevis (*cb*) runs onward, parallel at first to the nerve that innervates the rectus internus, and then parallel to the nervus opticus, and enters the eyeball not far from

the place where the opticus enters it. Both the nerve and its root—the radix longa—lie, in their course, lateral to the rectus superior, lateral to the superior division of the oculomotorius, mesial to the rectus externus, dorsal to the rectus inferior, dorso-lateral to the rectus internus, and dorsal to the inferior division of the oculomotorius.

The ciliary ganglion (*gc*) is relatively large, and is closely applied to the lateral aspect of that branch of the inferior division of the oculomotorius that supplies the recti inferior and internus. With that branch it is connected by short fibers representing the radix brevis, and many of these fibers could easily be traced a considerable distance proximally in the oculomotorius. In the specimen used for illustration in Fig. 65 there was a small and wholly separate ganglion lying immediately beyond the main ciliary ganglion. It was connected with the latter ganglion, and two short branches arose from it, one going to the nerve that innervated the rectus inferior and the other to the nerve that innervated the rectus internus. This small ganglion is doubtless the homologue of certain of the accessory ciliary ganglia described by Schwalbe (No. 68) and Schneider (No. 67) in other animals.

The ciliaris longus (*cl*) runs forward and outward, or at first forward and inward and then forward and outward, between the rectus superior and rectus externus, and enters the eyeball in the region between the surfaces of insertion of those two muscles. It has the same relations to the muscles and nerves of the eyeball that the ciliaris brevis has.

No branch was found arising either from the profundus ganglion, or from either of the ciliary nerves, that could represent the ramus ophthalmicus profundus of selachians.

The ciliary ganglion of *Scomber,* with its two roots—the radix longa and radix brevis—and the two ciliary nerves, were all found and described by Stannius (No. 70, pp. 38–40). According to his descriptions a ramus or truncus ciliaris arises directly from the trigemino-facial ganglion, close to the ramus ophthalmicus, and receives a sympathetic strand from the most anterior cerebral ganglion of the nervus sympathicus. The truncus then separates into a ramus ciliaris longus and a radix longa, the latter of which enters a ciliary ganglion, from which the ciliaris brevis arises.

The ciliary ganglion is said to be connected with the nervus oculomotorius by two strands representing the radix brevis, and also by a separate sympathetic root. Stannius thus did not find a profundus root or ganglion in *Scomber,* although both these structures are described by him in *Trigla* (No. 70, p. 35). While this root and ganglion may, in the specimens examined by Stannius, have been fused with the trigemino-facial root and ganglion, this seems to me improbable, since, in all the many specimens examined in my work, a separate profundus foramen was always found. The profundus root and ganglion, and the origin of the radix longa from that ganglion, were, however, missed in all the earlier dissections made, and the sympathetic strands that join the radix longa were supposed to represent the direct nervous connection of the ciliary ganglion with the trigemino-facial ganglion, as Stannius asserts.

A profundus root and ganglion are thus found in *Amia,* in *Scomber,* and in *Trigla.* In *Amia* an important Portio ophthalmici profundi is found, arising from the profundus ganglion, and there is also what may, possibly, be a rudimentary ramus ophthalmicus profundus. In *Scomber* and *Trigla* there is no trace of either of these nerves as structures arising from the profundus ganglion.

In *Menidia* Herrick (No. 38, p. 167) has recently described what he considers as a very small ramus profundus. He says that it arises from the gasserian ganglion, and that it "accompanies the sympathetic fibers of the radix ciliaris longa of the ciliary ganglion to that ganglion, after which they can no longer be separately followed. The relations of this nerve, which has not before been described for teleosts, indicates that the embryonic profundus ganglion has fused with the Gasserian." As the so-called radix ciliaris longa of this description is said to be composed of sympathetic fibers, it would seem as if it could be safely assumed that the fibers that form it arise from the large sympathetic ganglion said by Herrick to be associated with the trigemino-facial ganglion of the fish (No. 36), and that they are, accordingly, represented in *Scomber* in the sympathetic strands that join the truncus ciliaris of that fish. The so-called ramus profundus of *Menidia* would then seem to become the radix longa ganglii ciliaris of my

descriptions and of Stannius's, and not a ramus profundus trigemini; and a separate profundus root and profundus ganglion must be wholly wanting in *Menidia*. It is furthermore to be noted that, in all those fishes in which it is properly identified, the ramus ophthalmicus profundus never, so far as I can find, traverses or ends in the ciliary ganglion. It is, however, said to come into relations with that ganglion in certain other animals.

Dixon (No. 23) says that the ciliary ganglion, when first recognizable in man, is a collection of nuclei surrounding the frontal nerve, that nerve, however, simply traversing the ganglion as a solid and distinct bundle of fibers. The nervus trochlearis, at this stage, is said to run into this same ganglion and end in it. The nervus oculomotorius comes into no relations whatever with the ganglion. In older embryos the ciliary ganglion is said to lose entirely its early connection with the frontal nerve and the nervus trochlearis, and to acquire its adult relations to the nasal nerve and to the inferior division of the nervus oculomotorius. This change of position, and of relation to the orbital nerves, is accounted for by Dixon on the assumption of a migration of the cells of the ganglion. He then gives an extended review of the literature relating to the nerves and ganglia here concerned, going over much the same ground that I did, independently of him, in my work on *Amia* (No. 4, pp. 535–546), but giving more attention to embryological considerations than to anatomical ones. His work leads him to conclude: that the first formed ophthalmic trunk in mammals corresponds to the nasal nerve of the adult; that the frontal nerve is developed later than the nasal, in man united in a common trunk with the proximal part of the nasal nerve, but in the rat arising, separately and independently, from the gasserian ganglion; that in mammals no outlying part of the gasserian ganglion is present as a ganglion either for the ophthalmic or nasal nerve, in the sense of a ganglion of a posterior nerve root; and that the ciliary ganglion can in no sense be the homologue of a spinal ganglion.

Dixon's work thus seems to me to support my conclusion (No. 4, p. 544) that the frontal nerve of higher vertebrates is the homologue either of the portio ophthalmic profundi of *Amia*, or of a branch of the ophthalmicus profundus similar to the one de-

scribed by Ewart in *Læmargus* as branch 1; and that it is, accordingly, not the homologue of the ophthalmicus superficialis trigemini of fishes. Dixon, on the contrary, inclines to consider this last nerve as the homologue of the frontal of mammals (No. 23, p. 42). As to the ophthalmic or mesocephalic ganglion of certain descriptions of mammals he thinks it is simply "the cells of the 'nervenführendes Gewebe,' which appears before the axis-cylinders of the nerves are present, and from which the nuclei of the white substance of Schwann are said to be developed." He here makes special reference to His's work on human embryos, and to Chiarugi's preliminary notice of his work on the guinea-pig. Chiarugi himself, in his later publication (No. 13, p. 70), reasserts the existence of a ganglion on the ophthalmic nerve of embryos of the guinea-pig, and he considers it the homologue of Beard's mesocephalic ganglion, that is, of the ganglion described by me in *Amia* as the profundus ganglion. In the *Torpedo,* Chiarugi says this ganglion is found on the ramus ophthalmicus superficialis, an evident error either of observation or nomenclature. The ganglion described by His on the ophthalmic nerve of human embryos, Chiarugi considers as an early stage in the development of the ciliary ganglion, and of this latter ganglion, in general, he says (loc. cit., p. 70), "Tutte queste particolarità sono un probabile indizio che dalla branca oftalmica derivi il ganglio ciliare; l'abbozzo del ganglio si distaccherebbe prococemente da essa e portandosi ventralmente si svilupperebbe in contatto e in rapporto col III° pajo."

Holtzmann (No. 41) finds that the ciliary ganglion, in birds, is not connected with the trigeminus by a branch that arises directly from it, but by a branch that always arises from the ciliary nerves distal to their origin from the ciliary ganglion. Between this connecting branch and the ganglion there is, however, an important interchange of fibers, but whether these fibers run, from the connecting branch, proximally along the ciliary nerve into the ganglion, or vice versa from the ganglion into the connecting branch he is not sure. Of the cells that form the ganglion he says: "Ich habe daher keinen Grund, an der rein spinalen Natur der Zellen des Ciliarknotens der Vögel zu zweifeln." In the cat, on the contrary, he finds them all of a purely sympathetic character, as does

also Apolant (No. 10); both these observers thus confirming Retzius's earlier observations (No. 62). In the dog the cells of the ciliary ganglion are said by Holtzmann to be partly spinal and partly sympathetic in character. He therefore concludes that the ciliary ganglion is of cerebrospinal origin, a derivative of an intervertebral ganglion similar to those that give origin both to the spinal ganglia and to the ganglia of the sympathetic cord, and that "in ihm bald die eine, bald die andere Seite der ursprunglichen Anlage zur Entwicklung gelangt." He assigns the ganglion definitely to the nervus oculomotorius, and inclines to account for its presence on that purely motor nerve by considering the nerve, with Hatschek, as the ramus visceralis of the nervus Trigeminus I; that is, as the motor component of the dorsal spinal root of that nerve. Haller, also (No. 34, pp. 520–532), considers the ciliary ganglion as a spinal ganglion belonging to the nervus oculomotorius, and he says that as conclusive proof of this he succeeded, after many futile attempts, in tracing "Wurzelfasern" to it from spinal ganglion cells in the torus semicircularis. He accordingly concludes that the oculomotorius is an independent metameric cranial nerve. He makes no mention whatever of any branch connecting the ganglion with any part of the nervus trigeminus, a regrettable omission in a discussion of this subject.

Cole, in his preliminary work on *Chimæra* (No. 14), says that the profundus nerve, in that fish, "is undoubtedly a branch of the Vth, and does not arise by a separate root from the medulla. It springs from the main trunk of the Vth, slightly distal to the Gasserian ganglion." No profundus ganglion is described, but a ciliary ganglion is described similar to the one previously described by Ewart in *Læmargus*. In Cole's later, complete work (No. 15) he describes a profundus or mesocephalic ganglion, found on the profundus nerve soon after its origin from the trunk of the trigeminus, and says of the nerve itself that "its origin and distribution make it exceedingly probable that it corresponds to the motor division of the profundus found in Cyclostomes." As the nerve in *Chimæra* lies dorsal to the nervus opticus, while in *Myxine* the motor part of the ophthalmicus runs forward ventral to that nerve (No. 26, p. 31), this homology seems to me improbable. It is clearly based on an acceptance of Pollard's statement, to which

Cole makes reference (No. 15, p. 649), that the origin and termination of nerve fibers are the fundamental grounds for determining the homology of nerves. "The course of the nerves is of less importance." Apparently in accordance with the same principle Cole considers that the ophthalmicus profundus of fishes can be found fused with the ophthalmicus superficialis. Of this he says: "According to all reliable authority, the profundus is a cutaneous sensory nerve; and Allis states, further, that in *Amia* it fuses with the superficial ophthalmic of the Vth. The latter statement is interesting, when we consider that in *Chimæra,* as well as in other cartilaginous fishes, the fusion is with the ophthalmic of the VIIth." The ophthalmicus profundus of *Amia,* here referred to, is the Portio ophthalmici profundi, carelessly called "the ophthalmicus profundus" in my early work (No. 2, p. 513), and not the ramus ophthalmicus profundus. This is an important difference, for even admitting that the fibers that form the two nerves have the same central origin and a similar peripheral distribution, they are certainly not the same nerves, for they are said to be both found in a single fish, *Polypterus* (Nos. 78 and 58). It is, however, to be noted, that Pollard concludes that there is, in the adult *Polypterus,* no ramus ophthalmicus superficialis trigemini. In a 20-cm. specimen he says there appeared to be a commissure representing the nerve.

Regarding the ciliary ganglion Cole says, in his complete work, that a few ganglion cells are found on the inferior branch of the oculomotorius at the point where the radix brevis joins that nerve, and these cells alone are probably the homologue of the entire ciliary ganglion described by Schwalbe in the same fish.

The Trigemino-Facial Complex, the nervus profundus excluded, arises from the brain by two large roots, an anterior trigeminal one, and a posterior one which contains the facial and lateral line components of the complex. The anterior root arises from the ventro-lateral surface of the anterior end of the medulla, at about the level of the hind end of the hypoarium. It thus lies, at its origin, anterior to the hind end of the optic lobe, and ventral to it. The posterior root of the complex arises from the lateral surface of the medulla, immediately dorsal or dorso-anterior to the root of the acusticus, in part from the tuberculum acusticum,

and in part from the medulla immediately ventral to that structure. It received from the acusticus, in one dissection, a communicating strand which first touched and anastomosed with the ventral part of the posterior trigemino-facial root and then continued onward and joined the dorsal, or lateral line, part of the root. This strand was not noticed in other earlier dissections, but might have easily been overlooked. The two trigemino-facial roots both run forward, laterally, and slightly downward, and fuse more or less completely with each other while still inside the cranial cavity. They are completely hidden, in dorsal views, under the overhanging optic lobe.

The posterior root always shows three somewhat distinct tracts of fibers, and these tracts can, in certain preparations, be separated, at their origin from the brain, as three distinct bundles. Two of these three roots, or bundles of fibers, lie ventral or ventro-lateral to the other one, and they always fuse quite completely with each other and with the anterior, trigeminal root of the complex, while still inside the cranial cavity. The dorsal root, or bundle, always remains much more distinct from the other three roots of the complex than either of the latter three does from the others. From it the ophthalmicus facialis, buccalis facialis and oticus facialis have their apparent origins. Whether the fibers that form the mandibularis externus facialis also arise from it, or arise as a part of one of the other three roots of the system could not be determined. The most posterior and ventral of the other two bundles of the posterior root of the complex seemed to pass entirely to the hyoideo-mandibularis facialis and hence to be the motor facial root of the complex. The remaining root or bundle was distributed to both the facial and trigeminal branches of the complex. This latter root would seem to be the one described by Stannius (No. 70, p. 32) as the third root of the complex, and said by him to have a separate or nearly separate ganglion formed upon it.

The trunk formed by the more or less complete fusion of these several roots or bundles, becomes ganglionic while still inside the cranial cavity, and separates into two portions. One of these portions turns backward and laterally and traverses the facial foramen through the petrosal, the other continuing forward and laterally in the general line of the trunk and traversing the tri-

geminal foramen. Both parts are ganglionic as they traverse their respective foramina, and also, beyond those foramina, when they issue from them in the trigemino-facial chamber of the petrosal. From the part that traverses the trigeminal foramen, the truncus trigeminus and the ophthalmicus, buccalis, and oticus facialis arise. From the part that traverses the facial foramen the palatinus facialis and the truncus hyoideo-mandibularis facialis arise.

Scomber thus does not probably differ materially in its trigeminal and facial roots from *Amia,* excepting that the several roots of the complex are more completely fused with each other than in *Amia,* and that the trigeminal and facial elements, and the lateral line elements that accompany them, separate from each other while they are still intracranial in position instead of after they have entered an upper and lateral portion of the eye-muscle canal. It is, however, to be remembered that no histological examination whatever of the complex was made. In *Scomber* there is, in the trigemino-facial chamber, a large communicating branch between the trigeminal and facial trunks of the complex, a branch not found in *Amia.* If it exists in the latter fish, it must be included in the ganglionic formation from which the two trunks arise, instead of lying external to it.

In *Lota,* Goronowitsch (No. 32) finds the trigemino-facial complex arising, as I understand him, by two true roots and three "Stämme." The two true roots are said to be the motor and sensory roots of the facialis, which unite to form a single facial stem, or trunk. One of the three "Stämme" is said to contain the sensory and motor elements of nervus Trigeminus I.; the other two together containing the same elements of nervus Trigeminus II. The so-called ramus ophthalmicus superficialis of the fish is said to arise entirely from the nervus Trigeminus II., and, as I understand the descriptions, entirely from the dorso-median stem of that nerve, that is, from the part called by Goronowitsch Tr. II. R. The so-called ramus ophthalmicus profundus is said to be formed by two bundles of fibers, one of which arises from the single stem of the nervus Trigeminus I., and the other from the dorsal root of the facialis. These two ophthalmic nerves, closely accompanying each other, are said to run forward along the dorsal wall of the orbit; this position, as shown in Fig. 1, Pl. I. of Go-

ronowitsch's work, thus indicating that they should be the homologues, respectively, of the nerves called by me in *Amia,* and also in the present work, the ophthalmicus superficialis facialis, and ophthalmicus superficialis trigemini. The distribution of the branches of the two nerves is not, however, entirely in accord with this supposition. Thus, the so-called ophthalmicus superficialis of *Lota* is said to supply "den Schleimkanälen der hinteren Knochen der suborbitalen Reihe"; a region innervated both in *Amia* and *Scomber* by a nerve that can only be considered either as a branch of the buccalis facialis or of the oticus facialis. Goronowitsch then says, "Einige Zweige innerviren die Schleimkanäle des Frontale"; but whether these branches come from the ophthalmicus superficialis or from both that nerve and the profundus is not stated. The profundus is said to send a branch to the canal in the antorbital bone; that is, to a section of canal that lies in a bone that usually forms part of the suborbital chain of bones, and that, in *Amia,* is innervated by a branch of the buccalis. That there is some error in these several statements seems to me certain, and I assume that the fibers destined to supply the supraorbital canal all come from the stem Trigeminus II. R. From this same stem, Tr. II. R, a branch is said to be sent forward along the floor of the orbit. It is called by Goronowitsch the nervus rostralis and is said to innervate the lateral canal in the suborbital bones, being thus the probable homologue of the ramus buccalis facialis of my descriptions of *Amia.* It is said to be closely accompanied by a branch of the stem Trigeminus I., which is called by Goronowitsch the nervus maxillaris superior. An independent motor branch, which innervates the adductor mandibulæ muscle, is said to arise from the Trigeminus I., and the nervus maxillaris inferior is said to receive its fibers in part from that stem and in part from the dorsal root of the facialis. The entire stem Trigeminus II. H, is said to unite with the ventral root of the facialis, and to then receive fibers from the dorsal root of the facialis and from the stem Trigeminus I., the fibers from Trigeminus I. being said to be possibly motor. From these united nerves the ramus hyoideomandibularis is said to arise.

Trigeminus I. of *Lota* thus seems to be the homologue of the anterior, or trigeminal root of the trigemino-facial complex of

Amia; Trigeminus II. R to be the homologue of the anterior, or trigeminal lateral component of the complex of *Amia;* and Trigeminus II. H to be the homologue of the posterior, or facial lateral component of the complex of *Amia,* but having certain motor fibers associated with it. The dorsal root of the facialis of *Lota* seems to be the fasiculus communis component of *Amia;* and the ventral root of the facialis to be approximately the facial root of *Amia.* If this be so the roots or stems of the complex in *Lota* would not differ materially from those in *Scomber* and *Amia.* That there is some intermingling of the fibers of the several components is, however, evident, and my attempt to establish an homology between the three fishes is only intended to be an approximation. Goronowitsch, unfortunately, does not give a full and definite description of the peripheral distribution of the several branches of the complex, contenting himself not only with what seems to me a much too implicit reliance on the completeness of the work of Stannius and Vetter, but also with what seems to me the mistaken idea that, "Wenig Neues kann demnach eine Bearbeitung des Verlaufes der Hauptäste bringen" (No. 32, p. 35). That a careful study of the course and ultimate distribution of the cranial nerves of fishes can, in the present state of the literature of the subject, have but little morphological importance, and that all important results are to be obtained only by a study of the central origin of the fibers, seems to me certainly an error. To know where a nerve goes, and what it does, is absolutely necessary in all attempts to establish its homologies, and is hence equally as important as to know where it comes from, what character of fibers it contains, or how it is developed. Its peripheral distribution should, in fact, be, first of all, definitely known.

The Ophthalmicus Superficialis Trigemini (*opt*) and Ophthalmicus Superficialis Facialis (*opf*) arise, in *Scomber,* close together but independently of each other, from the trigeminal prolongation of the trigemino-facial ganglionic complex, leaving the ganglion either in the trigemino-facial chamber, or immediately beyond the trigeminal opening of that chamber. Running upward and forward, as separate nerves, in the hour-glass-shaped depression on the adjoining, orbital faces of the postorbital ossification and alisphenoid, they reach the ventral surface of the

frontal. There they fuse more or less completely to a single trunk, and, running forward, immediately mesial to the strong ridge on the ventral surface of the frontal, traverse the preorbital incisure, and reach the dorsal surface of the cartilage of the antorbital process. There the single trunk formed by the fusion of the two nerves continues forward between the frontal bone and the antorbital cartilage, in a groove on the dorsal surface of the latter, and then runs dorsal to the nasal sac toward the end of the snout. In their course the two nerves lie dorsal to all the other nerves and to all the muscles of the orbit.

The ophthalmicus facialis always gives off three branches, and sometimes four, before it fuses with the ophthalmicus trigeminus. These branches pierce the frontal and enter the supraorbital lateral canal, going to organs 7, 6, 5 and 4 of the line. The branch that goes to organ 4 usually arises from the single trunk formed by the fusion of the ophthalmic nerves. A fifth branch arises from the fused nerves as they pass dorsal to the nasal sac. It separates into two parts, each of which enters the nasal bone, one innervating organ 3 and the other organ 2. No important branches other than those described were given off by the two nerves up to this point, but it is evident that there either must have been numerous small branches, representing parts of the ophthalmicus trigemini, or that fibers of that nerve must accompany the lateral sensory branches that go to the several organs of the supraorbital canal. They could not however be traced, nor could the branch that must innervate the anterior head line of pit organs.

Distal to the branch to organ 2 supraorbital the ophthalmic trunk continues forward, lying dorsal to the nasal sac and passing between the ligament that extends from the dorso-lateral process of the ethmoid to the anterior end of the maxillary and the one that extends from the nasal bone to the maxillary. The nerve thus has the relations to these two ligaments that it has, in certain specimens of *Amia,* to two heads of the fourth division of the levator maxillæ superioris muscle (No. 4, p. 608). The nerve, in *Scomber,* here forms one or two anastomoses with the terminal portion of the maxillaris superior trigemini, and is distributed, with the latter nerve, to the anterior end of the snout. It sends no branch to organ No. 1 supraorbital, that organ being innervated, as already

stated in describing the lateral canals, by a branch of the buccalis facialis.

It is thus evident that the ophthalmicus facialis of *Scomber* must end in that branch of the united superficial nerves that goes to organ No. 2 supraorbital, and that beyond that branch the fibers of the trunk are wholly trigeminal. It is then the ophthalmicus trigemini alone that anastomoses with the maxillaris superior on the top of the snout. This anastomosis of these two nerves was not found in *Amia,* although the two nerves of that fish approach each other distally; nor is it described by Goronowitsch or Cole in either *Lota* or *Gadus.*

In the young of *Gadus* Cole says (No. 16, p. 156) that the two ophthalmic nerves, a certain distance beyond their points of origin from the ganglionic complex, enter "what appears to be a rudimentary eye muscle canal." As that part of the ganglionic complex that lies in front of the truncus hyoideo-mandibularis is said by Cole (*loc. cit.,* p. 135) to lie partly inside and partly outside the cranium, and as the ophthalmicus trigemini is given off from the anterior end of the ganglion, this nerve, at least, must have already issued from the cranium before entering the canal in question. Both nerves are said to leave the canal, in the "region of sense organ 3" supraorbital, that is, in the figure given, dorsal to the anterior edge of the eyeball. What the homologue of this canal may be, in either *Amia* or *Scomber,* I am wholly unable to tell.

The Truncus Maxillaris Trigemini (*tmt*) arises from the trigemino-facial ganglionic complex, either in the trigemino-facial chamber or immediately beyond the trigeminal opening of that chamber. It lies, at its origin, ventral to the buccalis facialis, which nerve arises independently of it, from the dorsal, more or less independent part of the complex. Lying close to the buccalis, and usually connected with it by a short commissural branch, it runs downward and forward internal to the levator arcus palatini, and, near the anterior edge of that muscle, separates into its superior and inferior divisions.

From the base of the truncus, or perhaps from what is still a part of the ganglion, a large commissural branch is sent backward, through the trigemino-facial chamber, to the truncus hyoideo-mandibularis facialis. This branch often arises by two strands

from the truncus maxillaris, and it usually separates into two parts before joining the truncus facialis. Close to its origin from the truncus maxillaris it is often flattened, and here presents somewhat the appearance of a ganglionic formation, but no microscopical examination was made to determine whether or not it contained ganglion cells. Stannius (No. 70, p. 47) described this branch in fishes as the Ramus communicans N. trigemini ad N. facialem, and he says that it is found in nearly all teleosts. In the Gadidæ it is said by him to be absent, because the facial and trigeminal nerves, in those fishes, issue from the skull by a single foramen. In *Lota,* however, it would seem to be represented in that branch that is described by Goronowitsch as a branch, possibly motor, of the nerve Trigeminus I. (No. 32, p. 28). In *Menidia* it must be the branch described by Herrick (No. 38, p. 167) as formed by general cutaneous "fibers running back into the truncus hyo-mandibularis VII. for the operculum." In *Amia,* it is not found, notwithstanding the fact that the trigeminal and facial nerves issue from the skull by separate foramina; and if the commissural connection between the two nerves concerned exists in that fish it must be found in some bundle of fibers forming part of the trigemino-facial ganglionic complex of the fish.

Immediately ventro-mesial to the anterior end of the trigemino-facial ganglion, at the point where the rami ophthalmici and the truncus maxillaris have their origins, there is a large sympathetic ganglion, the anterior end of which lies in the orbit and the posterior end in the trigemino-facial chamber. Anteriorly this ganglion presents two ends or heads, one of which is usually connected by one or two strands of fibers with the truncus maxillaris, and the other by one or two strands with the ophthalmicus trigemini (Fig. 66). From the mesial one of these two heads one or more branches are sent to the radix longa or to that nerve and also to the ciliaris longus, as has been already stated. Posteriorly the ganglion diminishes gradually in size, and becomes a nerve, which runs backward through the trigemino-facial chamber and reaches the truncus hyoideo-mandibularis facialis distal to the point where the ramus palatinus facialis is given off, but proximal to a branch of the facialis that forms a commissural connection with the nervus glossopharyngeus. There the sympathetic nerve separates into

two strands, one of which passes above the truncus facialis and the other below it, the two strands uniting again immediately beyond the truncus, thus enclosing it in a sympathetic loop. The sympathetic nerve here sends delicate fibers to the truncus facialis, the fibers seeming to run proximally into the truncus. The sympathetic nerve then issues through the facial opening of the trigemino-facial chamber, with the truncus hyoideo-mandibularis, lying ventro-internal to that nerve. Continuing backward, close against the lateral surface of the skull, it passes ventral to the nervus glossopharyngeus and ventro-internal to the commissural branch from that nerve to the facialis. It here lies close against the ventral surface of the proximal end of the ganglion of the glossopharyngeus, and presents two or three small ganglionic swellings. From the one or more posterior swellings delicate fibers go to the radix or ganglion of the glossopharyngeus. From the anterior swelling, in Mr. Nomura's several dissections, there was always a small branch running forward to the dorsal surface of the truncus hyoideo-mandibularis facialis and there connecting with the communicating branch from the trigeminus to the facialis. Posterior to the glossopharyngeus the sympathetic nerve continues backward, and, passing ventral to the vagus nerves as they issue from their foramen, enters another ganglion from which delicate fibers are sent to the vagus. Posterior to this ganglion the nerve continues backward ventro-mesial to the occipital nerves, to one or all of which fibers are sent. The nerve then reaches the ventro-lateral surface of the spinal column and joins a ganglionic formation that is in close connection with a small sympathetic ganglion associated with the first spinal nerve. From this last ganglion a sympathetic cord runs backward, ventro-mesial to the spinal nerves, along the ventro-lateral surface of the spinal column.

The large, anterior, sympathetic ganglion of *Scomber* was apparently entirely overlooked by Stannius, for he says (No. 70, p. 135): "Bei *Scomber* beginnt der Grenzstrang ohne dentliche Auschwellung an der Austrittsstelle der N. facialis." The ganglion that I have described lies wholly anterior to that point, and the ganglion of *Scomber* seems to agree closely with the one described by Herrick (No. 36) in *Menidia*. In *Menidia* Herrick

says that a branch from this ganglion anastomoses with the third nerve, and then "gives rise to the usual ciliary nerve."

The Maxillaris Superior Trigemini (*mst*) and Buccalis Facialis (*bf*) of *Scomber* usually anastomose shortly after the former nerve has separated from the maxillaris inferior. From this anastomosis two nerve strands arise which continue downward and forward under the eyeball, anastomosing again, one or more times, or being connected with each other, in a variable manner, by communicating branches. That there is, in these several anastomoses, an important interchange of nerve elements is evident from the ultimate distribution of the branches of each of the two nerve strands. The two strands, in this suborbital part of their course, lie external to, that is, posterior or ventral to, all the muscles of the orbit and the nerves innervating them, and dorsal to the floor of the orbit, that floor being formed either by the adductor arcus palatini or by parts of the palato-quadrate arch.

The buccalis facialis gives off two branches before its first anastomosis with the maxillaris superior. The first of these two branches is the ramus oticus facialis (*of*), which arises from the base of the buccalis, or from the ganglionic complex close to the base of that nerve. Turning upward along the hind wall of the orbit it enters the large pit in the orbital face of the postorbital ossification, and issues on the top of the skull by the one or two openings on the dorsal surface of that same bone, near its lateral edge. It there separates into two parts. One of these parts turns forward, and, entering the postfrontal bone, innervates organ 10 of the infraorbital canal. The other part turns backward and mesially, along the external surface of the dilatator operculi, and separates into two branches, both of which turn inward between the dilatator and the ridge of the squamosal that bounds its dorso-mesial edge, and entering the ridge innervate, one of them organ 11 infraorbital, and the other organ 12.

The oticus facialis of *Scomber* thus corresponds to the nerve identified as the oticus facialis in *Amia,* plus that branch of the buccalis of *Amia* that arises close to the base of the ramus oticus, almost as a part of that nerve, and that goes to organ 14 infra-orbital. The otic part of the main infraorbital canal of *Scomber*

thus definitely includes the postfrontal organ of the line. In *Amia* the postfrontal organ, although innervated by a branch of the buccalis that is relatively separate and distinct from the ramus oticus, is enclosed in its canal before the adjoining organ, No. 13, and is enclosed independently of that organ (No. 2). It accordingly belongs, in its development, as the corresponding organ in *Scomber* does in its innervation, much more to the otic part of the main infraorbital canal than to its buccal portion, and it may represent, as already stated, the anterior organ of a morphologically separate part of the line. If so the arrangement shown by Pollard in *Trichomycterus* (No. 59, Fig. 5) would be naturally explained. In *Menidia* the ramus oticus facialis is even said to innervate two postorbital organs (No. 36, p. 429).

In *Amia* the oticus facialis traverses a canal that lies between the postorbital ossification and the adjoining cartilage of the chondrocranium, and, on issuing on the dorsal surface of the skull, it passes directly to the organs it innervates, sending its first branch to the spiracular sense organ. In *Scomber* the nerve, after having first passed into the orbit, traverses a canal that lies wholly in the postorbital ossification; and those two branches of the nerve that supply the two squamosal organs take what seems a most indirect and circuitous course to reach their destination. This is due to the fact, already mentioned, that the dilatator operculi, in acquiring its origin on the dorsal surface of the skull, has crowded the nerve away from the canal that it innervates. The nerves do not cut into or through the muscle, but cross its outer surface, and then turn inward beyond it to reach the canal they supply. The fact that the muscle thus passes forward mesial to the canal traversed by the trunk of the nerve, and the further fact that that canal is much larger than is necessary simply for the passage of the nerve, would seem to indicate that the canal is in part a rudiment of the spiracular canal of *Amia*.

The second branch of the buccalis of *Scomber* innervates organ 9 infraorbital.

The third branch is given off after the buccalis has received the first small anastomosing branch from the truncus maxillaris trigemini, and just before it has its first important anastomosis with the maxillaris superior. It separates into three branches and innervates organs 8, 7 and 6 infraorbital.

Anterior to this third branch of the buccalis the relations of the buccalis and maxillaris superior to each other, and the number and disposition of their branches, varied greatly in different specimens. One large branch was usually sent to the connective or dermal tissues of the region, the branch arising sometimes from the united nerves and sometimes from one or the other of the two strands into which they separate after their first anastomosis. Another large branch was always given off from the superficial strand of the united nerves, and seemed destined, wholly, to the innervation of the first five infraorbital organs. One branch of this nerve entered the suborbital bone and innervated organ No. 5. A second branch (Fig. 53) always pierced the suborbital bone and then entered the infraorbital canal by the opening by which that canal issues from the hind end of the lachrymal. In this canal in the lachrymal the branch ran forward and innervated organ No. 4. The other branches of the nerve pierced the lachrymal separately, and entering the canal in that bone supplied organs 3, 2 and 1, the nerve ending in the latter organ. The branch that suppplied organ 2 was usually double at its outer end.

After giving off this large lateral sense organ branch, the one or two strands of the united nerves run forward, internal to the lachrymal and lateral to the ligament that binds the palato-quadrate to the posterior surface of the antorbital process of the skull, this latter ligament thus having the same relations to the nerves that the third division of the levator maxillæ superioris muscle has in *Amia*. In this part of their course, in *Scomber*, the two strands of the nerve were usually, but not always, found united in a single nerve. From the single nerve, or from the larger of the two strands where there were two, the maxillary branch of the maxillaris superior is here given off. Turning downward and forward this branch reaches the dorsal edge of the maxillary, and there separates into two parts, both of which pass internal to the maxillary, one turning forward and the other backward. Both parts soon break up into several branches, which spread forward and backward along the mesial surface of the maxillary, and the lateral surface of the premaxillary.

Immediately after giving off this maxillary branch the one or two main strands send two or more branches upward and forward

to the general tissues of the region, and then continue forward, sometimes as two wholly separate nerves, sometimes as two nerves partly fused, and sometimes as a single nerve. One of these nerves, where there are two of them, or a branch of the single nerve, where there is but one, runs upward and forward, mesial to the terminal part of the ophthalmicus trigemini, and entering the anterior portion of the nasal bone innervates the first organ of the supraorbital canal. This distribution of this branch shows that it contains lateral fibers, and that it must accordingly be derived from the buccalis facialis. Its origin from the parent nerve, independently of the branches that supply the first five organs of the infraorbital canal, strongly suggests, as already stated in describing the canal, that we have here to do with a separate section of the main infraorbital sensory line, and that that section is the homologue of the anterior section of the line in *Amia,* that is, of the anterior cross commissure of the latter fish.

The remaining, distal and terminal portion of the fused nerves, which now belongs entirely to the superior maxillary nerve, forms an important anastomosis with the terminal branches of the ophthalmic nerves, and then continues forward toward the end of the snout, some of its branches passing internal to the anterior end of the maxillary bone.

There are thus in *Scomber,* as in *Amia,* no motor branches arising from the maxillaris superior. In *Chimæra* Cole describes several such branches. In that fish the maxillary nerve of his descriptions does not closely follow the buccalis facialis, as the maxillaris superior does in *Amia* and in *Scomber.* There is, however, in *Chimæra,* according to Cole (No. 15, p. 644), a fairly large bundle of fibers sent from the trunk of the trigeminus to the buccalis, the bundle separating into two parts, one of which comes into relations with the so-called inner buccal nerve, and the other with the outer buccal nerve. This in itself, and, furthermore, both the course of the larger part of the so-called maxillary nerve, and the presence in it of large motor and pharyngeal components, all seem to indicate that this nerve of *Chimæra* must contain fibers which, in *Amia* and *Scomber,* are found in the inferior maxillary nerve. Certain of the motor fibers must represent the branch that in *Amia* innervates the levator maxillæ superioris muscles, a nerve which, in

Amia, seems to belong to the maxillaris inferior rather than to the maxillaris superior.

In *Gadus* Cole describes the oticus facialis as a branch of the so-called outer branch of the buccalis. It lies at first in the orbit, as in *Scomber,* and then, as in that fish, traverses a canal in the postorbital ossification and so reaches the dorsal surface of the skull. There it is said to run backward dorsal to the squamosal but ventral to that section of the membranous infraorbital canal that lies on the dorsal surface of that bone, and reaches organ No. 11 infraorbital which it innervates. The nerve thus does not pierce the squamosal in any part, and Cole suggests that the organ it innervates may be the postfrontal organ of the line, that organ having left the postfrontal bone and invaded the squamosal. After giving off the ramus oticus, the outer branch of the buccalis is said to send branches to organs 10 and 9 infraorbital, and then to continue a considerable distance and finally to innervate organs 8 and 7 infraorbital. Organs 10 and 9 are said to lie in the postorbital bones, organs 8 and 7 in suborbital ones. That part of the outer buccal branch of Cole's descriptions that lies distal to the ramus oticus is thus approximately the equivalent of the branches that supply organs 11 to 14 infraorbital in *Amia,* those five organs together with the otic organs forming two of the four groups of buccal organs that I considered as distinctly independent of each other in so far as the manner of their innervation is concerned (No. 2, p. 514). The inner buccal branch of Cole's descriptions of *Gadus* must accordingly represent that part of the buccalis of *Amia* that innervates organs 1 to 10 infraorbital. These organs in *Amia* were separated by me into two groups, and the nerves that innervate each group probably correspond to the upper and lower branches of Cole's inner buccal nerve, Cole's upper branch corresponding to that terminal part of the buccalis of *Amia* that innervates organs 1 to 4 infraorbital, and to that part of the buccalis of *Scomber* that innervates organ No. 1 supraorbital. This has already been referred to in one of my earlier works (No. 8), as well as in the earlier parts of the present work.

The Ramus Maxillaris Inferior Trigemini (*mit*), after separating from the maxillaris superior, runs downward and forward internal to the superficial division of the adductor mandib-

ulæ. Near the distal end of that muscle it issues between it and the deeper division of the adductor, and comes to the exposed outer surface of the latter muscle near the hind end of the mandible. There it describes a short curve, turning upward and forward along the lower edge of the superficial division of the adductor, near its insertion, and passes mesial to the hind edge of the articular, near its dorsal end. There it turns downward and forward, and lying internal to the articular, along the lateral surface of the mandibular part of the adductor mandibulæ, reaches the dorsal surface of Meckel's cartilage. There it turns directly forward, along the dorsal surface of the cartilage, and lying internal to the dentary continues its forward course toward the anterior end of the mandible.

What is probably the first branch of the nerve is given off from the truncus maxillaris as it issues from the trigeminal opening of the trigemino-facial chamber. Turning backward and upward, close against the lateral surface of the skull, it sends two branches to the levator arcus palatini, and then enters and innervates the dilatator operculi. It is accordingly the exact homologue of the first branch of the corresponding nerve in *Amia*.

Not far from this first branch of the nerve the communicating branch from the truncus maxillaris to the buccalis facialis is given off. This branch thus corresponds, in the order of its origin from the truncus, but in nothing else, so far as is evident, to the large branch sent in *Amia* to the levator maxillæ superioris. Somewhat further forward the truncus maxillaris separates into its superior and inferior portions.

The third branch of the inferior nerve is given off after it has separated from the superior one. It leaves the nerve approximately at the anterior edge of the levator arcus palatini, and separates at once into two parts, each part often appearing as a separate and distinct nerve. Running backward and downward between the superficial and deeper divisions of the adductor mandibulæ, each part or division of the nerve breaks up into two or more branches, all of which enter the two divisions of the adductor, which they innervate. This branch of *Scomber* is accordingly the homologue of the third branch of the nerve in *Amia*.

The next, or fourth, branch of the nerve is given off from that

short part of the nerve that lies exposed on the outer surface of the adductor mandibulæ muscle, between its superficial and deeper divisions, near their distal ends. It turns downward and backward external to the deeper division of the adductor, and then along the hind edge of the mandible. Somewhat below the ventral edge of the adductor it enters a small canal in the articular, turns sharply forward, and traversing the bone issues at its anterior edge. There, lying in the tissues between the articular and dentary, it turns downward toward the lower edge of the mandible, passing, in its course, mesial to the mandibular lateral canal but lateral to the mandibularis externus and internus facialis. It thus lies between the mandibular lateral canal and the nerve that innervates the organs of that canal, and hence must, if it arise by being split off from the ectoderm, have been so split off after the mandibularis externus facialis had so arisen, and before the mandibular canal had been enclosed.

From this fourth branch of the maxillaris inferior two principal branches are given off. The first one turns upward and forward along the hind edge of the mandible, runs internal to the dorsal portion of the distal end of the superficial division of the adductor, and reaches the dorsal portion of the coronoid process of the articular. There it turns sharply forward, mesial to that process, and, running directly forward, is lost in the lining membranes of the inner surface of the mandible. It is accordingly, in its ultimate distribution, the homologue of the mandibularis internus trigemini of my descriptions of *Amia,* but it runs, in *Scomber,* ventral and internal to the superficial division only of the adductor mandibulæ, and not, as in *Amia,* ventral and internal to both divisions of that muscle. The second branch enters a small canal in the articular, dorsal to and similar to the one traversed by the terminal portion of the main branch, and running forward and slightly upward issues from the bone near its anterior edge and is distributed to tissues there. In one specimen another branch of the nerve was found which seemed to be running toward the inner surface of the ventral end of the preoperculum, but it was lost, in the dissection, before it reached that bone.

This fourth branch of the maxillaris inferior of *Scomber* thus corresponds closely to the fourth branch of the same nerve in

Amia, excepting only that a posterior branch, sent to the inner surface of the hyoid arch in *Amia,* could not be established in *Scomber.* This fourth branch of the maxillaris inferior of *Amia,* in whole or in part, combined perhaps with one or with both of the branches called by me r.ghs and r.ghi in that fish, was considered by me as the probable homologue of the nerve described by Pinkus (No. 53), in *Protopterus* as the inferior branch of the palatinus facialis. This palatine nerve in *Protopterus* is considered by Pinkus as the homologue of the chorda tympani of higher animals; and the mandibularis internus trigemini of *Amia* was considered by me as the only nerve in that fish that could be the homologue of the chorda, this latter nerve being considered as a prespiracular one (No. 4, pp. 638, 640, 748).

Herrick (No. 36), in his investigation of the cranial nerves of *Menidia,* makes a suggestion regarding the chorda tympani that indicates that he also is, or was, under the impression that that nerve might be found in fishes as an apparent branch of the trigeminus. This is found in a statement made while speaking of the fasciculus communis component of the trigemino-facial complex of the fish. He there says: "Certain fibers from the r. maxillaris supply the lining of the mouth and are probably derived from this component (chorda tympani?)." In a later publication (No. 38) he says that a part of that sensory portion of the facialis that is derived from the fasciculus communis is distributed to "the r. maxillaris V. to taste buds within the upper lip." He does not again refer to the branch so distributed as possibly containing chorda tympani elements, and its distribution to the upper lip instead of to the lower jaw, if correct, would seem to preclude its being that nerve.

Goronowitsch, in his work on *Lota,* says (No. 32, p. 39) that the nervus maxillaris inferior of that fish "enthält . . . die Elemente von zwei, mit einander verschmolzenen Nerven, des N. maxillaris inferior und des N. palatinus von *Acipenser.*" In his work on *Acipenser* he says (No. 31, p. 482): "Ein N. palatinus trigemini existirt beim Sterlet nicht; der N. palatinus ist ausschleisslich ein Ast des Facialis"; and then, "Da kein N. palatinus anterior angenommen werden konnte, so musste der Nerv [N. palatinus posterior (van Wijhe)] als ein N. palatinus facialis bezeichnet wer-

den." We thus have, according to Goronowitsch, the posterior division of the palatinus facialis of the cartilaginous ganoids, associated, in *Lota,* with the maxillaris inferior trigemini.

It should here be noted that the ramus mandibularis internus trigemini of my descriptions must not be confounded with the nerves similarly named by Wright, Pollard and Goronowitsch, for my mandibularis internus is probably a branch of what all those authors call the ramus mandibularis externus trigemini, externus and internus being apparently used by them to express simply the relations of the nerves to the coronoid process of Meckel's cartilage. I overlooked this use of the name by Wright and Pollard when I gave the name I did to the branch in *Amia,* and Goronowitsch's work had not yet appeared when my manuscript was sent to press. Stannius simply refers to what is probably the mandibularis externus of these authors, a nerve that must accordingly contain my mandibularis internus, as an outer "Unterkieferast" (No. 70, p. 45). The remaining portion of the maxillaris inferior is considered by him, as by me, as the continuation of the trunk of the nerve itself, and it is said by Stannius to separate into an upper and a lower portion, "welche beide zunächst für die Innenflache des Unterkiefers bestimmt sind." These two portions of the nerve have, however, in my opinion, little if any anything to do with the innervation of the lining membrane of the mouth cavity, and hence are not internal mandibular nerves in the sense in which I have used that term, based on the application of the same term to the ramus mandibularis facialis.

The next two branches of the maxillaris inferior of *Scomber,* after the fourth branch, are given off close together, soon after the main nerve has entered the mandible, one arising from the antero-dorsal edge of the nerve and the other from its postero-ventral edge. Both run forward, the dorsal one of the two entering the dentary near its dorsal edge and running forward, in a canal in the bone, nearly to its anterior end. It lies, in this part of its course, immediately ventral to the small sharp teeth that line the edge of the mandible.

The next branch of the nerve is given off as the main nerve reaches the dorsal surface of Meckel's cartilage. It runs downward along the external surface of that cartilage, and at its ven-

tral edge turns sharply forward. In that position it continues forward, lying dorsal to and close to the mandibularis externus facialis. In some specimens the two nerves are easily separated throughout their entire length; in others they were more or less fused with each other. Toward the anterior end of the adductor mandibulæ muscle, the trigeminal branch turns downward and then mesially, internal to the terminal branches of the facial nerve, and reaching the ventral surface of the inferior division of the geniohyoideus turns mesially and backward on that muscle (Figs. 56–57). Before leaving the mandible a branch is sent forward into the dentary, which it pierces, and issues upon its external surface. From this last branch two or more delicate branches are sent to the tissues between the anterior ends of the mandibles, near the symphysis, and possibly also to the degenerate intermandibularis muscle, though this muscle seemed to receive branches from the main inferior maxillary nerve, as will shortly be described. The main branch, continuing mesially and backward on the ventral surface of the geniohyoideus, soon reaches the mid-ventral line of the head, where it joins and anastomoses completely with its fellow of the opposite side of the head. Running backward a short distance, in the mid-ventral line, the single nerve strand soon separates into two parts, each of which runs backward and laterally, in a wavy course, on the ventral surface of the corresponding geniohyoideus to the place where that muscle becomes entirely tendinous. There the nerve penetrates the muscle, turns almost directly backward, approximately along the middle line of the external surface of the ceratohyal, and so continues until it reaches the hind edge of the tendinous part of the geniohyoideus, where it turns downward and backward and joins the ramus hyoideus facialis between the fourth and fifth branchiostegal rays counting from above downward. A part of this long hyoid part of the nerve, starting from the mid-ventral trunk formed by the anastomosis of the nerves of the two sides of the head, belongs, most certainly, to the ramus hyoideus facialis, but how much of it belongs to that nerve and how much to the trigeminus it is impossible to tell, there being no interruption whatever in the course of the nerve. From the fused nerves branches are sent to both divisions of the geniohyoideus, and, if Herrick is right in his work on *Menidia* (No. 38,

p. 167), it is the trigeminal part of the nerve, and not the facial part, that innervates the muscle.

This terminal part of this large branch of the maxillaris inferior of *Scomber* thus seems to represent the two branches called by me in my descriptions of *Amia r. ghs* and *r. ghi*, and it can for convenience be designated as *r.gh*. It corresponds, apparently, to that branch of the trigeminus that is called by Ruge (No. 63, p. 269) the nervus mylo-hyoideus, and that is said by him to be a "portio facialis des Ram. III. trigemini." In *Ceratodus* this nerve is said by Ruge to contain motor elements destined to innervate, in part, the muscle C_2mv, that muscle also receiving branches directly from the ramus hyoideus facialis; certain of the branches of the latter nerve forming an anastomosis with branches of the former. In *Protopterus* that branch of the trigeminus that corresponds to the nervus mylo-hyoideus of *Ceratodus* is said to take no part in the innervation of the muscle C_2mv, that muscle being innervated wholly by branches that come directly from the ramus hyoideus facialis (No. 63, p. 281). The muscle C_2mv, in each of these fishes, is said by Ruge to be derived, unquestionably, from the muscle similarly designated by him in selachians, and the muscle, in these latter fishes, is said to be a part of the facialis group of muscles. The apparent innervation of the muscle by a branch of the trigeminus, in *Ceratodus*, is then accounted for by the supposition that the motor fibers in the r. mylo-hoideus of that fish are in reality a part of the facialis, and have become associated secondarily with the nervus trigeminus.

The muscles C_2mv of *Ceratodus* and *Protopterus* would seem, unquestionably, to include fibers that represent, in those fishes, the inferior part of the geniohyoideus of *Amia*, which muscle I was led (No. 4, p. 582), under considerable reserve, to derive from the ventral half of the superficial constrictor of the mandibular arch, and not from that of the hyoid arch. Ruge's positive assertion that that branch of the trigeminus that is distributed to this muscle in *Ceratodus* contains motor fibers, and Herrick's statement, already referred to, that, in *Menidia*, it is the trigeminus and not the facialis that innervates the geniohyoideus seem to confirm this conclusion; as does also Cole's statement (No. 15) that in *Chimæra* certain long branches of the mandibularis trigemini go

to the superficial muscles of the ventral region of the head of that fish. Moreover Stannius says, of *Scomber,* that in the roots of the trigemino-facial complex it agrees exactly with *Pleuronectes,* and that in *Pleuronectes* stimulation of the trigeminal root of the fish seemed sometimes to produce movements of the geniohyoideus (No. 70, pp. 25 and 23). Ruge's statement that the muscle C_2mv in *Protopterus* and selachians is innervated, so far as he could determine, solely by the hyoideus facialis would of course lead to an exactly contrary conclusion.

Certain of Ruge's statements regarding these nerves and muscles should perhaps here be noted. On page 209 he says, in speaking of the composition of the truncus hyoideo-mandibularis: "Diesen sensiblen Elementen sind motorische Zweige zugestellt, welche in der Kiefergegend einen sogenannten R. mandibularis externus und einen R. mand. internus vorstellen." And on page 213, he says of one of these mandibular branches, which one is not clear: that in many fishes it forms anastomoses with the ramus mandibularis of the trigeminus, and that "In dieselbe pflegen auch motorische Facialis Elemente hineinbezogen zu werden." The rami mandibularis externus and internus facialis, as thus composed, are clearly not the homologues of the similarly named nerves of *Amia,* the externus, in that fish, being limited to the innervation of lateral sensory organs, and the internus anastomosing with the maxillaris inferior trigemini beyond the point where the branch r.ghi of that nerve is given off. On page 210 Ruge further says: 'Die Annahme, dass auch der zwischen Kiefer- und Zungenbein-Bogen sagittal ausgespannte Muskel (Geniohyoideus) unter der Herrschaft des Facialis stehe, darf als eine irrthümliche und als eine bereits wiederverlassene betrachtet werden"; and, "Da der 'genio-hyoideus' der Fische fraglos zum Rektus-System gehört, so fällt er der Gebiete der vordersten kranialen Spinalnerven oder der spinalen Kranialnerven anheim." And yet on page 283 he says: "Der Intermandibularis empfängt Aeste vom Trigeminus und vom Facialis (Vetter S. 513). Gleiches ist der Fall mit demjenigen Abschnitte von C_2mv, welcher in den geniohyoideus sich forsetzt." There certainly seem to be some contradictions here.

The maxillaris inferior of *Scomber,* after giving off the large

branch *r. gh,* above considered, runs forward along the dorsal surface of Meckel's cartilage to the point where that cartilage enters the ramus of the dentary. There the nerve leaves the cartilage, and, instead of entering the ramus of the dentary, runs mesial to that bone and receives from, or sends an anastomising branch to, the mandibularis internus facialis, exactly as in *Amia.* The nerve then breaks up into several terminal branches, some of which enter the dentary, one of them traversing that bone and coming to its external surface. A branch is apparently sent from this part of the nerve to the imperfectly developed intermandibularis muscle.

The Truncus Hyoideo-Mandibularis Facialis (*hmf*) arises from the hind end of the trigemino-facial ganglionic complex. Running backward and laterally it traverses the facial foramen through the cranial wall and issues in the trigemino-facial chamber of the petrosal. There it turns backward and issues from the chamber by its posterior or facial opening. Turning laterally and upward, along the side wall of the skull, it traverses the adductor hyomandibularis, at its origin, and then runs laterally along the dorsal surface of that muscle to the inner opening of the facial canal through the hyomandibular.

While traversing the foramen through the petrosal, and also while still inside the trigemino-facial chamber, it presents a well marked ganglionic swelling. In the chamber it gives off the ramus palatinus facialis, which runs downward and slightly forward through the palatine canal in the petrosal. The truncus then passes through the loop in the large sympathetic nerve that traverses the trigemino-facial chamber, as already described, and then, as it issues from the chamber, receives from, or gives to the nervus glossopharyngeus a communicating branch, which will be considered in describing the latter nerve. As it reaches the dorsal surface of the adductor hyomandibularis, it gives off two branches, one directed forward and the other backward. The former pierces the adductor hyomandibularis and innervates it and undoubtedly also the adductor arcus palatini, though the fibres of the nerve were not traced definitely to the latter muscle. The other branch runs backward and laterally on the dorsal surface of the dorso-posterior portion of the adductor hyomandibularis, and

reaches the dorso-lateral surface of the adductor operculi, which muscle it innervates. Continuing backward and downward, between the adductor operculi and the levator operculi, and then along the internal surface of the latter muscle, it sends one branch to this muscle, apparently innervating it. Beyond the hind edge of the levator operculi it reaches the inner surface of the operculum, where it breaks up into several branches, one of which goes to the dorsal patch of degenerate muscle fibers near the hind edge of the operculum, and another to the next ventral patch. These two branches of the truncus thus innervate the adductor hyomandibularis, the adductor arcus palatini, and the adductor operculi, and apparently also two patches of degenerate muscle tissue on the inner surface of the gill cover, and the levator operculi. The two branches, taken together, are, accordingly, the homologue of the single ramus opercularis facialis of *Amia*. By Stannius the first of these two branches, in *Scomber,* is called the ramus ad musculum adductorum arcus palatini, the second branch, only, being considered as the ramus opercularis.

Opposite or beyond these two branches the truncus facialis is joined by the commissural branch from the truncus maxillaris trigemini, this branch running dorsal to the truncus facialis, and there usually separating into two parts, both of which join the truncus near its posterior edge. In the specimen examined by Mr. Nomura a small branch was sent from this commissural nerve backward to one of the sympathetic ganglia that are found related to the nervus glossopharyngeus. This commissural branch of *Scomber* is apparently, as already stated, the homologue of the one described by Goronowitsch in *Lota*, in which fish it is said by him to arise from the trigeminus I., and to probably contain motor fibers destined for the truncus facialis. In *Amia* it is not found; and Herrick does not mention it in *Menidia*. By Stannius it is said to be found in nearly all teleosts. In *Chimæra* Cole describes a short commissural connection between the so-called root of the buccal of that fish and the root of the hyomandibularis, which may, possibly, though it seems to me not probably, be this nerve.

Beyond this commissural branch, the truncus, in *Scomber,* enters the facial canal in the hyomandibular, and while still in that

canal gives off a branch which separates at once into two parts. Each of these parts traverses a separate, small, branch canal in the hyomandibular, reaches the outer surface of that bone, enters the preoperculum on its inner surface near the dorsal end of its anterior edge, and then enters the preopercular lateral canal. In that canal the dorsal branch turns upward, but as no indication of a sense organ in relation to it could be found, it is probably not a lateral sensory nerve, notwithstanding its course, position and apparent origin. If it be a lateral sensory nerve its associated organ must have aborted, in advance of the nerve, as would naturally be the case. The other branch turns downward and innervates organ 11 of the preoperculo-mandibular line. From the dorsal nerve a small branch was sent backward along the inner surface of the preoperculum. Its ultimate destination could not be determined, but it apparently went to general connective or dermal tissues only. It is, however, to be noted, that, in *Amia,* in this same region, a branch is sent from the branch that innervates organ 14 preoperculo-mandibular to the horizontal cheek line of pit organs (No. 4, p. 616), and that this same branch is apparently found both in *Lota* and *Esox* in the buccalis accessorius of those fishes.

Having issued from the facial canal, onto the external surface of the hyomandibular, the truncus hyoideo-mandibularis runs downward and backward in the groove on the hind edge of that bone, lying in a canal formed by the hind edge of the hyomandibular and the anterior edge of the preoperculum. Near the ventral end of the hyomandibular the truncus separates into its two main parts, the ramus hyoideus and the truncus mandibularis.

The Truncus Mandibularis Facialis, having separated from the ramus hyoideus, turns downward and forward and issues from the canal between the hyomandibular and preoperculum onto the external surface of the former bone. Continuing its course it crosses the external surface of the interspace of cartilage between the adjoining ends of the hyomandibular and symplectic, passes inward through the narrow space between the symplectic in front and the preoperculum and the dorso-posterior process of the quadrate behind, and reaches the inner surface of the palato-quadrate arch. While on the external surface of the arch it lies internal

to the anterior edge of the preoperculum, or immediately in front of that edge, and while in that position gives off two or three branches, one of which is the ramus mandibularis internus. The larger of the other two branches, in the one specimen in which it was traced, ran downward and forward along the external surface of the quadrate and disappeared in the dermal tissues near the articular end of that bone. The other branch ran downward and inward internal to the preoperculum. That part of the truncus that remains after giving off these branches is the ramus mandibularis externus, but it seems not to be composed entirely of lateral sense organ fibers, as it apparently was in *Amia*.

The Ramus Mandibularis Externus (*mef*), having reached the inner surface of the palato-quadrate, runs downward and forward internal to the anterior edge of the preoperculum, or internal to the adjoining hind edges of the quadrate and symplectic, and here gives off either two or three branches, this varying in different dissections that were made. Two of these branches, where there are three, or both of them where there are but two enter the preoperculum and supply organs 9 to 6 of the preoperculo-mandibular lateral canal. The third branch, noticed in two or three specimens but only traced in one, arose between the two sense organ branches, ran downward and backward along the inner surface of the preoperculum, and then onto the lateral surface of the interoperculum, between that bone and the preoperculum. There it separated into two parts, one of which ran forward and the other backward along the lateral surface of the interoperculum, between that bone and the preoperculum. This branch corresponds, approximately, in its origin from the main nerve, to the branch sent in *Amia* to the vertical cheek line and mandibular line of pit organs. No indication whatever of surface sense organs could however be found in this part of the head of *Scomber*.

After giving off these two or three branches the mandibularis externus continues downward and forward along the inner surface of the quadrate and symplectic, crosses the lower end of the quadrate, internal to its articular head, and reaches the mesial surface of the articular. In this part of its course it passes between the preopercular and quadrate heads of the tendon that arises

from the hind edge of the fascia on the inner surface of $A\omega$, and it lies, throughout its entire course, dorsal to what seems to be the slightly developed ligamentum mandibulo-hyoideum. In *Amia* the corresponding nerve runs downward postero-external to the latter ligament, that is in a position relative to the ligament exactly the opposite of that in which it lies in *Scomber*. The nerve in *Scomber* must accordingly have traversed the ligament, if the ligaments in the two fishes are homologous structures, which seems, as already stated, doubtful. The nerve in *Scomber* then runs forward, ventral to Meckel's cartilage, lying mesial to the articular and dentary, and lateral to the mandibular part of the adductor. It here passes lateral to the ligaments that are connected with the fascia that lines the mesial surface of $A\omega$, but mesial to those tendons of A_2A_3 that have their insertions on or near the hind end of Meckel's cartilage. Beyond this point it accompanies, or anastomoses more or less completely with, that large branch of the ramus maxillaris inferior trigemini, that I have designated as *r. gh*. Before reaching the ventral surface of Meckel's cartilage branches are sent from the nerve to organs 5 and 4 of the mandibular lateral canal, and then, further forward, branches to organs 3, 2 and 1 of the same canal.

THE RAMUS MANDIBULARIS INTERNUS FACIALIS (*mif*), after leaving the truncus mandibularis, runs downward and forward, and passing between the anterior edge of the symplectic and the adjoining edge of the quadrate reaches the inner surface of the latter bone. There it joins the mandibularis externus, and runs forward into the mandible, lying parallel to and immediately dorsal to the externus, but in no way connected with it. As it reaches the hind end of Meckel's cartilage it turns slightly upward, mesial to that cartilage, but it lies throughout its entire course either imbedded in or lateral to the fibers of $A\omega$. Anteriorly it either anastomoses with the terminal portion of the maxillaris inferior trigemini, or with a branch of that nerve, as already stated. The main nerve, after the anastomosis, continues forward and is lost in the tissues toward the symphysis of the mandibles. The nerve thus differs from the nerve in *Amia*, in that it lies in, or lateral to, $A\omega$, instead of ventral to that muscle. As already stated, it must certainly be the chorda tympani of the animal,

as many authors assert, if that nerve is a postspiracular and not a prespiracular one. Ruge so considers it and says, moreover, (No. 63, p. 214) that the ramus mandibularis n. facialis of most reptiles, birds, and mammals seems "dem Trigeminus völlig einverleiht worden zu sein."

The Ramus Hyoideus Facialis (*hf*), after it leaves the main truncus hyoideo-mandibularis facialis, runs inward and downward through the ventral end of the narrow space between the hind edge of the hyomandibular and the anterior edge of the preoperculum, and reaches the inner surface of the latter bone. There it runs downward, slightly posterior to the epihyal, then forward and downward across the inner surface of the proximal end of the ceratohyal, and then forward along the inner surface of the branchiostegal rays, close to the postero-ventral edge of the ceratohyal. While on the inner surface of the gill-cover the nerve gives off two or three rather large branches. The first of these branches leaves the nerve near the ventral edge of the exposed inner surface of the preoperculum, and running backward crosses the exposed surface of that bone, then the inner surface of the pointed process at the anterior end of the suboperculum, and then a short portion of the operculum immediately behind that process. It then reaches the anterior edge of the body of the suboperculum, and passes backward between the adjoining and overlapping edges of that bone and the operculum. From this branch a branch is sent downward between the adjoining and overlapping edges of the preoperculum and interoperculum. The second branch, and a third branch also when found, is sent backward along the inner surface of the interoperculum, between that bone and the muscle fibers that arise from the dorsal branchiostegal ray, and that form the dorsal portion of the superior division of the hyohyoideus. Anterior to these branches other branches are sent from the main nerve to other portions of the superior division of the hyohyoideus, the nerve continuing forward along the external surface of that muscle, between it and the internal surfaces of the branchiostegal rays, onto the external surface of the inferior division of the muscle. Between the fourth and fifth branchiostegal rays, counting from above downward, the nerve sends a branch outward onto the outer surface of the superior division of the geniohyoideus.

This branch, which is less stout at its origin than the anterior continuation of the main nerve, runs forward on the outer surface of the geniohyoideus, or slightly buried in it, and, as already described, anastomoses completely, in the middle line of the head, with its fellow of the opposite side. The anterior end of this mid-ventral trunk is joined, on each side of the head, by the trigeminal branch that I have described as *r. gh,* those two nerves and the two facial branches anastomosing so completely that their respective limits can not be determined. From the united nerves branches are sent to both divisions of the geniohyoideus. In *Menidia* it is, according to Herrick, as already stated, the trigeminus and not the facialis that innervates this muscle.

The Ramus Palatinus Facialis (*pf*) leaves the main truncus facialis, as already described, while that truncus is still inside the trigemino-facial chamber of the petrosal. It runs directly downward, or downward and forward, and immediately leaves the chamber by the dorsal opening of the palatine canal. It then traverses that canal, and issuing from its ventral end enters the anterior end of the eye-muscle canal. From there it runs forward, ventral to all the muscles of the eyeball, lying at first along the lateral edge of the parasphenoid, and then slightly dorsal to that edge. Near the hind edge of the antorbital process of the skull it turns sharply laterally and forward, and separates into two parts. One of these parts turns directly laterally, toward the lateral edge of the palato-quadrate arch, and was lost in the tissues there. It is a delicate nerve and is perhaps the homologue of a part of the ramus palatinus posterior of *Amia.* The other and principal part of the nerve turns directly forward, along the ventral surface of the skull, and could be traced internal to the vomer toward the anterior end of that bone, as all, or part, of the ramus palatinus anterior facialis. No branches of either nerve could be traced far enough to determine whether there was or was not an anastomosis with the maxillaris superior trigemini, as there was in *Amia.*

8. *Nervus Acusticus.*

No special study was made of the ear of *Scomber,* and the two views given of it (Figs. 67 and 68) are intended simply to show its general form and the distribution to it of the several branches

of the nervus acusticus. The anterior semicircular canal and the anterior part of the posterior one are, as already stated, pressed against and slightly imbedded in the lateral surface of the brain. The anterior semicircular canal and the sinus utric. superior lie entirely in the cranial cavity, as does also all of the utriculus excepting its hind end. The sacculus lies in the saccular groove in the floor of the cranial cavity. The external semicircular canal is almost entirely enclosed in a bony or cartilaginous canal, as is also the larger part of the posterior one. Whether there was a membrane separating the labyrinth from the cranial cavity proper, or not, could not be determined.

No ductus endolymphaticus could be found in any of the several dissections made.

The nervus acusticus arises from the lateral surface of the medulla ventral to and between the lateral-sensory root of the trigemino-facial complex and the root of the nervus lineæ lateralis vagi. It runs at first almost directly downward, and, because of the position of the ear, close against the lateral surface of the brain; the anterior part of the nerve then turns laterally while its posterior part turns mesially, giving to the nerve a twisted appearance. The anterior part of the nerve has two long branches, which innervate the cristæ acusticæ in the ampullæ of the anterior and external semicircular canals, and a short portion between them, which innervates the macula acustica of the recessus utriculi. The posterior portion of the nerve sends stout branches to the macula acustica sacculi, and to the macula or papilla acustica lagenæ, and a more slender one to the crista acustica in the ampulla of the posterior semicircular canal. What I take to be a macula neglecta could be recognized in one of several specimens examined. It was innervated, in that specimen, by a short branch of the branch that innervated the crista acustica of the posterior semicircular canal.

There is a large otolith in the sacculus, and, in the lagena, a compact mass of material which, when touched, breaks up into a sand-like substance.

9. *Nervus Glossopharyngeus.*

The nervus glossopharyngeus (*gl*) arises from the brain by a single root which has its apparent origin immediately anterior to the vagus, between that nerve and the acusticus. From there the root runs at first backward, laterally and downward, parallel to and immediately anterior to the vagus root. It then turns sharply forward and laterally, and from this point Mr. Nomura always found a small branch continuing backward and laterally to join and fuse completely with the root of the vagus. Herrick finds what would seem to be this same communicating branch in *Menidia,* and says (No. 38, p. 165) that it is composed of communis fibers that "apparently go out with the first three or four branches of the n. lateralis (the first of these being the n. supratemporalis vagi), accompanying the proper lateralis fibers, and ultimately anastomoses with the r. recurrens VII."

Beyond the point where this communicating branch is given off, the main root of the glossopharyngeus, in *Scomber,* runs forward and laterally until it reaches the inner wall of the skull, where it turns sharply backward and laterally, parallel to the anterior part of its course, and traverses its foramen in the occipitale laterale. Issuing from that foramen it turns sharply forward and laterally again and enters at once its ganglion. In its intracranial course it passes between the sacculus and the sinus utriculi posterior. The ganglion of the nervus is round and flat, and a sympathetic ganglion is closely applied to the ventral surface of its proximal end. From the distal end of the ganglion a single trunk arises, in some specimens, and separates immediately into the anterior and posterior branches of the nervus. In other specimens these anterior and posterior branches arise from the ganglion separately and independently of each other, but close together. From the distal end of the root of the nervus, close to the point where it enters its ganglion. Dr. Dewitz, in certain of his preparations, could separate a bundle of fibers which ran outward across the ventral surface of the ganglion and joined and fused completely with the posterior branch of the nervus, slightly beyond the ganglion. Proximally they could not be separated from the remaining fibers of the root. They represent considerably less

than one half the fibers of the entire root, but, nevertheless, form a bundle that seems sufficiently important to represent the entire motor component of the nervus.

The ramus anterior of the nervus (*agl*) arises either directly from the ganglion of the nervus, as a separate and independent nerve, or as a branch of the single truncus of the nervus, close to the point where the latter leaves the ganglion. It runs forward, or upward and forward, along the side wall of the skull, to the upper edge of the surface that gives origin to the external levators of the first two arches and to the ligament that represents the interarcualis dorsalis of the first arch. There it turns forward, external to the muscle and ligament of the first arch, and between the two heads of the muscle of the second arch, lying immediately against the ventro-lateral surface of the jugular vein. Anterior to the surface of origin of the two muscles the entire nerve, in some specimens, turns downward internal to the mucous lining of the posterior surface of the adductor hyomandibularis (Fig. 66), and joins and fuses completely with the communicating branch already described as coming from the nervus facialis. In other specimens the glossopharyngeal nerve separates into two strands one of which continues directly forward while the other turns slightly downward, both of them joining and fusing completely with the communicating branch from the facialis; one of them however seeming to run proximally into the communicating nerve and the other distally with it. After this anastomosis of the two nerves a single trunk continues downward to the anterior end of the opercular gill, where it separates into two parts. One of these parts turns forward along the ventral surface of the adductor hyomandibularis, the other turning backward and laterally along the ventral edge of the opercular gill. This gill, as already stated, receives its blood supply from the arteria hyoidea.

The anastomosis above described is certainly Jacobson's anastomosis, and it seems to be formed by two nerves, one coming from the nervus facialis and the other from the glossopharyngeus. The ramus anterior glossopharyngei seems, in fact, to here separate into its two divisions, the ramus pharyngeus and ramus pretrematicus. The ramus pharyngeus seems to run proximally into the communicating branch from the facialis, and it may be that it is

simply juxtaposed to that nerve, and then, for a short distance, to the truncus facialis, on its way to join and accompany the ramus palatinus facialis. The ramus pretrematicus glossopharyngei seems to turn distally, with the communicating branch from the facialis, and to be distributed to the opercular gill, as it naturally should be if that gill belongs to the hyoid arch. The fibers that run forward along the ventral surface of the adductor hyomandibularis might be either pretrematic fibers of the glossopharyngeus, or parts of the facialis, in which latter case they would probably represent parts of a posterior division of the palatine nerve. There being no spiracular canal in *Scomber* the relations of the nerves to that structure can not be determined, and the communicating branch from the facialis to the glossopharyngeus may be a prespiracular branch notwithstanding its apparent postspiracular position. That the posterior division of the palatinus facialis, or a part of it, should become separated from the rest of the nerve and have a separate origin from the trunk of the facialis is not improbable.

Stannius (No. 70, p. 77), it is to be noted, considers the communicating branch from the facialis to the glossopharyngeus in *Perca* and *Tinca* as probably sympathetic. In *Scomber* he says that the ramus anterior of the glossopharyngeus receives a branch of the "N. sympathicus, der von der Austrittsstelle der N. facialis aus zu ihm tritt." Whether this branch is the sympathetic trunk of my description or the communicating branch from the facialis, I am unable to decide.

Dixon (No. 23) says that Jacobson's nerve in man and in the rat is an outgrowth of the petrous ganglion of the glossopharyngeus, and that if taste fibers from the trigeminus are found in it in the adult they must be a relatively late acquisition.

Ruge says (No. 63, p. 212) of the ramus anterior s. hyoideus of the glossopharyngeus that, in teleosts, it sends a branch to the pseudobranch; and that "Man wird an den N. tympanicus denken müssen."

In *Menidia* the pseudobranch, and that part of the roof of the mouth that lies between the areas supplied by the glossopharyngeus and the palatinus facialis, are said by Herrick (No. 38) to be supplied by an independent branch of the facialis that arises from the

geniculate ganglion of the fish, between the truncus hyo-mandibularis and the ramus palatinus. This nerve is said to furnish the only nerve supply that the pseudobranch receives, and the nerve is considered by Herrick, because of this, as the pretrematic branch of the facialis, the pseudobranch being said to represent a spiracular, that is, a mandibular gill. The glossopharyngeus is said to lack entirely a ramus pretrematicus, and there is said to be no commissural connection whatever between it and the facialis. The absence of these two nerves, and particularly that of the ramus pretrematicus glossopharyngeus, is so striking a peculiarity, and so different from the conditions found in *Scomber,* that it seems a not improper supposition to assume that they, one or both, may be represented in the so-called pretrematic branch of the facialis. The nerve supply of the pseudobranch of *Menidia* would then probably be the same as that of the opercular gill of *Scomber,* whatever that supply may be. If Friedrich Müller (No. 47), the latest worker on the subject, is correct in his conclusion that the pseudobranch and opercular gills of teleosts all belong to the mandibular arch, it is evident that the fibers that go to the gill, in *Scomber,* must be facial instead of glossopharyngeal.

In *Gadus* Cole says (No. 16, p. 135) that the nerve known as Jacobson's anastomosis is a posterior division of a single facial nerve, the anterior division of which is "the true palatine branch of the facial nerve and its two divisions, the anterior and posterior palatine nerves described by Allis in *Amia.*" Later in the same work, he says (pp. 145–148) that Jacobson's nerve is the palatine or pharyngeal branch of the glossopharyngeus, and that it only joins and accompanies a branch of the palatinus facialis, intimately associated with it. The conditions in *Gadus* may, therefore, represent a condition intermediate between those found in *Amia* and *Scomber,* but it would seem important to know, in *Gadus,* the definite distribution of the palatinus facialis and the ramus anterior glossopharyngei.

In Goronowitsch's descriptions of *Lota,* I can not recognize the homologue of the communicating branch from the facialis to the glossopharyngeus of *Scomber.* A connection between these two nerves is described by Goronowitsch (No. 32, p. 40), but the communicating branch from the glossopharyngeus is said by him to

join that branch of the hyoideo-mandibularis facialis that is sent to innervate the adductor operculi and adductor hyomandibularis muscles; this arrangement thus being markedly different from that found in *Scomber,* although it is said by Goronowitsch to exist in *Esox* also. I also can not recognize in *Scomber* the N. Weberi of Goronowitsch's description of *Lota,* a nerve that is certainly not the complete homologue of the Accessorius Weberi of Haller's nomenclature. In Goronowitsch's Fig. 5 this nerve looks strikingly like the communicating branch from the facialis to the glossopharyngeus in *Scomber,* but its distribution, as shown in Fig. 1, precludes its being that nerve. Other differences in the two fishes are also to be noted. The ramus mandibularis facialis of *Lota* is said to innervate a part of the adductor mandibulæ muscle; which it certainly does not do in either *Scomber* or *Amia.* The levator arcus palatini of *Lota* is said to not be differentiated from the adductor mandibulæ. A nerve, called by Goronowitsch the ramus buccalis facialis, is said to arise from the truncus hyoideo-mandibularis, to be distributed to the skin near the articulation of the lower jaw, and to be the homologue of one of the branches of Trigeminus I. In *Amia* the homologue of this nerve, if I am correct (No. 4), is distributed to the organs of the pit lines of the cheek. The lateral canal organs of *Lota* are also not all innervated as they are in *Amia* and *Scomber,* as has already been previously stated.

The ramus posttrematicus glossopharyngei, runs downward, from its ganglion, to the dorsal surface of the epibranchial of the first arch, reaching that surface between the surface of insertion of the ligamentous interarcualis dorsalis of the first arch and that of the external levator of the same arch. In its course it here lies dorsal to the suprapharyngobranchial of the arch; dorso-posterior to the common carotid artery; dorso-anterior and then ventro-anterior to the efferent artery of the arch; and ventral to the anterior prolongation of that artery. It reaches the antero-lateral edge of the external surface of the first arch, and in that position runs distally to the extreme distal end of the arch, giving off numerous small branches and one large one. Certain of the small branches are distributed to the degenerate interbranchial muscle of the arch, and others to the degenerate

obliquus ventralis. None of them, so far as could be determined, anastomosed with the branches of the ramus posterior of the arch. The one large branch was given off shortly before the nerve reaches the distal end of the epibranchial. It turned downward, internal to the bases of the rays of the anterior row of gill filaments, and then across the antero-lateral face of the ceratobranchial of the arch. There it continued distally to the distal end of the arch, giving off numerous small branches, apparently destined to supply the dermal processes or spines of the arch. None of the branches were traced definitely into those processes, and the branches of the nerve were much less numerous than the processes.

From the base of the ramus posttrematicus two motor branches were given off, one to the anterior division of the internal levator of the arches, and one to the external levator of the first arch.

10. *Nervus Vagus.*

The root of the nervus vagus (*v*) and that of the nervus lineæ lateralis vagi (*nll*) issue together from the vagus foramen, the nervus vagus lying ventro-posterior to the nervus lineæ lateralis. Both roots arise from the lateral surface of the medulla, the root of the lineæ lateralis arising antero-dorsal to the root of the vagus, and slightly dorso-posterior to the root of the acusticus. The vagus arises by several separate rootlets. Both roots run at first backward and downward, and then turn laterally, backward, and downward as they pass through their foramen.

No intracranial branches were found arising from either the vagus or the lateralis roots, my work agreeing in this with Stannius' (No. 70, p. 85). From each of the two roots, however, as they pass through their foramen, a nerve arises, which Stannius seems to have overlooked. The two nerves lie close together and both turn laterally and dorsally as they issue from the skull. The branch of the vagus, which, according to Herrick (No. 38, p. 165), is, in *Menidia,* partly or wholly formed by communis fibers from the root of the glossopharyngeus, runs upward along the outer surface of the anterior edge of the trunk muscles, lying slightly anterior to the branch of the nervus lineæ lateralis. It passes lateral to the posterior process of the intercalar, and there sends a branch forward toward the origin of the levator operculi

muscle. The remainder of the nerve then turns outward and reaches the inner surface of the operculum, where it pierces the opercular bone and could not be further traced. The branch of the nervus lineæ lateralis penetrates the septal membranes that cover the outer surface of the anterior end of the trunk muscles, passes mesial or posterior to the posterior process of the intercalar, and then mesial to the posterior process of the squamosal. There it breaks up into four parts, one of which supplies organ 13 infra-orbital, which lies in the hind end of the squamosal; one organ 15 in the anterior end of the suprascapular; and the other two the three organs in the extrascapular. These two branches, arising one from the vagus root and the other from the root of the lineæ lateralis, are thus the supratemporal branches of their respective nerves, but they are not, in their distribution, the exact homologues of the corresponding branches in *Amia*.

Immediately outside the vagus foramen the first vagus nerve separates from the rest of the truncus and enters a ganglion, which is wholly separate and distinct from the ganglia formed on the other parts of the nervus. These latter ganglia are more or less fused with each other, the second ganglion being partly fused with the third, and the third one still more completely fused with the fourth. All of the ganglia lie internal to the levatores arcuum branchialium, and ventral to the anterior edge of the trunk muscles. The first intermuscular septum has its atachment to the skull immediately dorsal to the vagus foramen; the antero-ventral edge of the second septum lying along the hind edge of the foramen, and extending forward a slight distance both dorsal and ventral to it.

In the later dissections made by Dr. Dewitz he was able to separate two bundles of fibers from the ventral surface of the vagus ganglion, the bundles having their origins from the root of the nervus and running distally, across the ventral surface of the ganglia, to the trunks of the nerves beyond them. Mr. Nomura, in his dissections, did not find these bundles so distinctly differentiated, this difference in the results obtained being doubtless due to the difference in the way the specimens were preserved and treated. One of the two bundles found by Dr. Dewitz arose from the root of the first vagus, just as, or before, that nerve

separated from the main root of the nervus, and running distally along the nerve, and then along the inner surface of its ganglion, joined the nerve again toward the distal end of the ganglion. The other bundle arose from the ventro-mesial surface of the main root of the entire nervus, before the first vagus nerve had separated from it, and running ventro-posteriorly, along the internal surface of the second, third and fourth ganglia, broke up into several branches, all of which joined the three posterior vagus nerves beyond their ganglia. In the final and most perfect dissection made this bundle separated into four branches, one of which went to the second vagus nerve some distance beyond its ganglion, a second to the third vagus close to its origin from its ganglion, and the third and fourth to the fourth vagus. The fibers of these two bundles thus did not pass through any of the ganglia of the nerves to which they were related, resembling in this the bundle of fibers found by Dr. Dewitz on the nervus glossopharyngeus, and already described.

The First Vagus Nerve usually separates, immediately beyond its ganglion, into anterior and posterior parts, the latter being the posttrematic branch of the nerve, and the former the united pharyngeal and pretrematic branches. Lying close together the two parts run downward, backward and laterally between the anterior and posterior divisions of the internal levator of the branchial arches, and there separate from each other, the anterior division also separating into its pharyngeal and pretrematic parts.

The pharyngeal branch of the nervus runs downward and forward, mesial to the interarcualis dorsalis that connected the first and second arches, between that muscle and the antero-lateral edge of the obliquus dorsalis of the second arch, and separates into two branches. One of these two branches, in the specimen examined, was distributed entirely to the tissues along the antero-ventral face of the second infrapharyngobranchial, and the other partly to those same tissues and partly to tissues along the oral edge of the postero-mesial face of the first epibranchial. Both branches lie postero-mesial to the suprapharyngeal process of the first epibranchial and hence also to the suprapharyngeal element of the same arch.

The pretrematic branch of the nervus runs forward, laterally

and downward, passes dorsal to the interarcualis dorsalis of the first and second arches, and reaches the dorsal surface of the first epibranchial immediately distal to the suprapharyngeal process of that element, thus lying posterior to the external levator of the first arch. From there the nerve runs distally, the full length of the arch, as a separate and independent nerve, lying always postero-mesial to the artery of the arch. It gives off in its course numerous branches, none of which fuse with the branches of the posttrematic branch of the glossopharyngeus. Distally, at the point where the afferent artery of the arch reaches the ventral surface of the hypobranchial, the delicate ends of the nerve turned mesially, toward the basal line, and were lost.

From the pretrematic nerve, at and close to the point where it separates from the pharyngeal branch, several small branches are given off. In the one specimen in which they were especially examined, they united with each other and with a single branch from the posttrematic part of the nervus, and formed a sort of plexus, the branches of which were all distributed along the dorsal surface of the interarcualis dorsalis of the first and second arches, certain of them entering that muscle and undoubtedly innervating it.

The posttrematic branch of the nervus runs downward, backward and laterally, and passing ventro-mesial to the anterior prolongation of the efferent artery of the arch reaches the dorsal surface of the second arch along the surface of insertion of the interarcualis dorsalis that connects that arch with the first one. It then continues distally along the arch, lying always toward the antero-lateral edge of the arch, and antero-lateral to the arteries of the arch. Toward the distal end of the hypobranchial of the arch, the main nerve, or one of its terminal branches, perforated that element and appeared on its antero-lateral surface. There it turned upward and broke up into delicate terminal branches which ran forward and backward along the lateral surface of the basal line.

The posttrematic nerve gives off, in its course, several branches. The first branch is given off not far from the ganglion of the nerve, and innervates the posterior division of the internal levator of the arches. The next branch is given off about where the

nerve separates from the pharyngeal and pretrematic parts of the nervus, and innervates the external levator of the second arch. The next branch, in the specimen used for illustration, was a delicate one which fused with four delicate branches of the ramus pretrematicus to form the plexus, already described, that in part innervates the interarcualis dorsalis of the first and second arches. The next branch is a large one, and is given off as the main nerve approaches the distal end of the epibranchial of the arch. It is sometimes single and sometimes double at its origin, the two parts in the latter case soon uniting again to form a single nerve. It turns laterally and then downward over the antero-lateral edge of the epibranchial, and passing internal to the degenerate interbranchial muscle of the arch reaches the dorsal or oral edge of the antero-lateral surface of the ceratobranchial. As it passes the ventral or oral edge of the antero-lateral surface of the epibranchial, a large branch is sent proximally along that edge; and as it traverses the angle between the epibranchial and ceratobranchial a number of delicate branches are sent to the degenerate interbranchial muscle of the arch. The main branch then continues distally to the distal end of the arch, lying at first near the dorsal or oral edge of the antero-lateral surface of the ceratobranchial of the arch, and, beyond that element, near the corresponding edge of the hypobranchial. It gives off, in this part of its course, many delicate branches, thus resembling in every respect the corresponding branch of the corresponding nerve of the first arch.

The main ramus posttrematicus, after giving off this large anterior or oral branch, reaches the ventral aspect of the ceratobranchial, and at the distal end of that element passes onto the ventral surface of the degenerate obliquus ventralis of the arch. Toward the anterior end of that muscle, it perforates the hypobranchial of the arch and appears on its antero-lateral surface, where it turns upward and breaks up into delicate terminal branches which run forward and backward along the antero-lateral surface of the hypobranchial and the adjoining lateral surface of the basal elements. While on the ventral aspect of its arch one or more branches are given off by the nerve, but, as on the first arch, no branch in the full length of the nerve

anastomosed, so far as could be determined, with branches of the posterior nerve of the arch. On the posterior arches also the branches of the anterior and posterior nerves of the arch did not anastomose, *Scomber* thus differing markedly in this respect from *Amia*.

The Second Vagus Nerve separates, slightly beyond its ganglion, into its anterior and posterior portions, both of which run downward and slightly backward through a small triangular space that lies between the hind edge of the posterior division of the internal levator of the arches, the dorsal surface or anterior edge of the obliquus dorsalis of the third arch, and the antero-ventral edge of the external levator of the same arch. The anterior portion of the nervus here separates into its pharyngeal and pretrematic parts.

The pharyngeal branch of the nervus, running downward, reaches the lateral surface of the posterior division of the internal levator, where it lies between that muscle and the proximal edge of the suprapharyngeal process of the second epibranchial. Continuing downward it enters the tissues that lie on the dorsal surface of the third infrapharyngobranchial, lateral to the insertion of the levator muscle, and breaks up into several branches, some of which penetrate the bone itself.

The pretrematic branch of the nervus runs downward and laterally till it reaches the dorsal surface of the suprapharyngeal process of the second epibranchial, where it turns forward and laterally on that process, and at its base reaches the dorsal surface of the epibranchial. There it turns distally and continues distally to the distal end of the arch, not differing in any important respect from the corresponding branch of the first vagus. Both this branch and the posttrematic branch pass ventral to the anterior continuation of the efferent artery of the third arch.

The posttrematic branch of the nervus runs backward, downward and laterally, crosses the dorsal surface of the interarcualis dorsalis that connects the second and third arches, and reaches the dorsal surface of the epibranchial of the third arch. There it has a course and distribution not differing from that of the corresponding branches on the two anterior arches. At its distal end it separates into two branches, one of which passes internal

to the obliquus ventralis of its arch, and then toward the basal line. The other branch reaches the ventral surface of the obliquus ventralis, sends a branch to that muscle, traverses the so-called obliquus ventralis of the fourth arch, and then turns backward along the mesial surface of the pharyngo-hyoideus muscle near its insertion. It apparently innervates both this muscle and the obliquus of the fourth arch but this could not be definitely determined.

From the main truncus of the nervus, just as it separates into its three portions, or even from the base of the pharyngeal branch of the nervus, a large branch is sent downward and mesially to the dorsal surface of the obliquus dorsalis of the third arch. There it breaks up into several branches, some of which turn mesially and forward, and others mesially and backward, along the dorsal surface of the muscle. Certain of the posterior branches enter the obliquus of the third arch, and others the transversus dorsalis posterior. The anterior branches run forward onto the obliquus of the second arch and onto the anterior division of the transversus dorsalis, certain of them entering those muscles, and others going to the general tissues of the region. As this nerve apparently innervates all the muscles to which its branches are distributed, it is evident that it must either contain, not only elements that belong to the second vagus, but also elements belonging to the first vagus, or that the muscles that it innervates must all belong to the third arch. As the latter supposition seems the less probable, it must be that certain motor fibers belonging to the first vagus are carried to the second vagus in that branch, found by Dr. Dewitz, that goes to this last nerve from the large bundle of fibers that passes ventral to the ganglia of the several nerves without entering them. This branch of the bundle separates into two parts as it fuses with the second vagus, one branch going to the posttrematic branch of the nervus and one toward the base of the branch here under consideration.

Close to the origin of this motor branch of the second vagus, but either from the pretrematic branch of the nervus, or from the united pretrematic and pharyngeal nerves, a separate branch is sent to the external levator of the third arch; and slightly distal to it another branch to the interarcualis dorsalis that connects the second and third arches.

The Third Vagus Nerve runs backward and downward, ventro-mesial to the external levator muscles of the third and fourth arches, and approximately parallel to them. At some distance from its ganglion it separates into its anterior and posterior portions. The former is a slender nerve which, turning slightly laterally, runs downward, backward and laterally, between the external levators of the third and fourth arches, and passing dorsal to the obliquus dorsalis of the third arch reaches the dorsal surface of the suprapharyngeal process of the third epibranchial. There it separates into its pharyngeal and pretrematic branches. The former continues backward and downward, and traverses the space between the postero-mesial edge of the suprapharyngeal process of the third epibranchial and the adjacent antero-lateral edge of the fourth epibranchial, lying immediately lateral to the surface by which the two elements articulate, and immediately mesial to the mesial edge of the interarcualis dorsalis that connects the two arches. It sends a branch to the interarcual muscle, apparently innervating it, and turning mesially and downward enters the tissues on the dorsal surface of the fourth infrapharyngobranchial. The pretrematic branch of the nervus reaches the dorsal surface of the third epibranchial and has a course and distribution similar to that of the corresponding nerves on the anterior arches.

The posttrematic branch of the nervus runs downward, backward and laterally, between the external levator of the fourth arch and that levator that has its insertion on the clavicle, and reaches the dorsal surface of the fourth epibranchial, where it separates into two parts. The larger of these two parts continues distally along the dorsal surface of the epibranchial, passing ventral to the anterior prolongation of the efferent artery of the arch, and reaches the antero-lateral aspect of the main artery; where it continues distally as the ramus anterior of the arch. The other part turns downward and backward, ventral to the main efferent artery of the arch, immediately dorso-mesial to the point where that artery gives off its anterior prolongation. Crossing the postero-mesial edge and surface of the fourth epibranchial it reaches the oral surface of the fourth ceratobranchial, where it has a course and distribution similar to that of the branches which, on the anterior arches, run downward over the antero-

lateral edges of the epibranchials of their respective arches. These two principal portions of the ramus posttrematicus of this arch thus seem, when compared with the corresponding nerves on the anterior arches, to have shifted backward and downward around their arch, the anterior part of the nerve being, on this arch, the main nerve of the arch, and the posterior portion being an oral branch. The posterior portion innervates the adductor muscle of the arch, and it is to be noted that on the anterior arches no adductor muscle is found. The anterior part, which is, in position, the ramus anterior, or principal nerve of the arch, innervates no muscles whatever, so far as could be determined, though delicate branches of it may perhaps go to the obliquus ventralis of the fourth arch and to the transversus ventralis anterior.

From the main truncus of the nervus, close to its ganglion, a delicate branch is sent to the external levator of the fourth arch. In the first specimens examined this nerve had its apparent origin from the truncus of the second vagus, and was considered by Dr. Dewitz as a branch of that nerve. As this seemed unusual another specimen was examined, with the same result, but it was found on further examination, that this branch could be separated from the second vagus and traced to the third vagus. In still another specimen the branch arose from the third vagus alone.

The Fourth Vagus Nerve gives off, from its root, proximal to its ganglion, or from the ganglion itself, a delicate branch which goes to that levator muscle that has its insertion on the clavicle. From the distal end of the ganglion, or from the trunk of the nerve beyond the ganglion, another branch has its apparent origin. When the ganglion is carefully cleaned this branch is seen to be formed by two strands, one of which arises from the fourth vagus, while the other and larger one can be traced proximally, along the inner surface of the fourth vagus and its ganglion, to the third vagus. Where it joins the third vagus that nerve is also joined by one of the four branches of the bundle of fibers that pass outward from the main root of the vagus without entering the ganglionic formations. A second branch of this same bundle joins the fourth vagus close to the point where the first mentioned strand of the nerve here under consideration has

its apparent origin. This nerve thus has an apparently double origin, arising both from the fourth and third vagi. It undoubtedly receives a part, at least, of its fibers from the non-ganglionic strand of the main vagus root. The branch is a long one. It runs at first backward and slightly mesially to the hind edge of the efferent artery of the fourth arch, which artery lies slightly posterior to the hind edge of the transversus dorsalis posterior. There it turns downward and forward behind and around the artery, and runs forward ventral to the artery and then ventral to the transversus dorsalis, lying between that latter muscle and the anterior end of the retractor arcuum branchialium of its side of the head. Running forward in this position, along the mesial edge of the superior pharyngeal bone, it is distributed to tissues there, certain of its branches perforating the third infrapharyngobranchial and going to general tissues on its ventral surface. One branch of the nerve goes to the retractor muscle, and others to the anterior extensions of the constrictor œsophagei.

After giving off these two branches, and at some distance from its ganglion, the fourth vagus separated, in one specimen, into two nearly equal parts. In a second specimen it separated into three parts, two of which first anastomosed, and then, separating, one of the two strands united with the remaining third part of the nervus, thus forming two principal nerves. These two parts of the fourth vagus are the superior and inferior pharyngeal nerves of the fish, both of which run backward, dorsal to the efferent arteries of the third and fourth arches. The inferior nerve sends branches to the interarcualis dorsalis that connects the fourth and fifth arches, and then separates into two parts, both of which turn downward and then forward over the posterior end of the gill arches. One of these two parts reaches the grooved external surface of the fourth ceratobranchial, at its proximal end, and becomes the ramus posterior of the fourth arch. It is accordingly the ramus pretrematicus of the fourth vagus. From it, before it reaches the grooved surface of the ceratobranchial, certain delicate branches are given off, some of which go to the tissues of the pharynx, and apparently represent pharyngeal elements of the nervus, while others apparently innervate the adductor muscle of the fifth arch. The other branch of the main nerve reaches the

ventral surface of the ceratobranchial of the fifth arch and, separating into two parts, runs distally along that bone, one part of it lying ventral to the lateral edge of the transversus ventralis posterior, and another dorsal to that muscle. It is accordingly the ramus posttrematicus of the fourth vagus. From that part of the nerve that lies ventral to the transversus muscle a branch is sent downward along the mesial surface of the pharyngo-claviculares externus and internus, which it innervates. A delicate branch of this nerve could be traced forward onto the mesial surface of the pharyngo-hyoideus, but whether it innervates the muscle in part or in whole could not be determined.

The large superior pharyngeal nerve runs backward along the dorsal surface of the œsophagus, its course and distribution not being investigated.

The Nervus Lineæ Lateralis Vagi issues, as already stated, with the vagus from the vagus foramen, lying dorsal to that nerve. It runs at first backward, internal to all the levator muscles, and then backward and upward along the external surface of the anterior end of the trunk muscles. As it traverses the vagus foramen it gives off its first branch, which, as already stated, turns upward along the side of the skull, enters the superficial layers of the anterior end of the trunk muscles and reaches the mesial aspect of the posterior process of the squamosal. There, it separates into three or four branches. The anterior one of these four branches turns forward, and entering that short section of the main infraorbital canal that lies in the squamosal posterior to the point where the main canal is joined by the preoperculo-mandibular canal, innervates organ No. 13 infraorbital. The posterior branch of the nerve turns backward, and entering the anterior end of the suprascapular innervates organ No. 15 in that bone. The remaining one or two branches separate into three parts all of which enter the extrascapular, one of them innervating the main infraorbital organ No. 14, found in that bone, and the other two the two organs of the supratemporal commissure.

The second branch of the main nervus is an accessory part of the main nerve, rather than a branch of it, for, as far backward as the dissection was carried, it lies parallel to the main nerve

and somewhat dorsal to it, and it is from it and not from the main nerve that the branches to the sense organs of the lateral line of the body arise, as far back as the dissections were carried. At certain intervals branches from the main nerve join the accessory one. That the lateral line nerve of *Scomber* is found in two parallel portions is stated by Stannius.

The first branch that arises from this accessory nerve enters the suprascapular and innervates the second organ in that bone, organ No. 16 infraorbital. The second branch innervates the organ in the supraclavicular and also the organ in the first scale of the lateral line. The third branch innervates the organ in the second scale of the lateral line, and was the last one traced.

11. *Occipital and First Spinal Nerves.*

The ganglion of each of the first six spinal nerves lies nearer the anterior than the posterior septum of the muscle segment to which it belongs, the relative distance from that septum increasing regularly from the first to the sixth nerve. From each ganglion four nerves arise, as in *Amia,* a ventral nerve or branch, a horizontal one, a dorsal one, and an anterior or communicating one.

The ventral branch of each of the posterior four nerves examined first runs downward and backward along the lateral surface of its vertebra, toward the posterior septum of its segment, and then passes downward through an open space found in the horizontal septum, immediately in front of that horizontal rib that lies in the transverse septum posterior to the segment. It then reaches the inner surface of the trunk muscles, that is the lining wall of the body cavity, and turning relatively forward gradually approaches the anterior transverse septum of its segment and its associated ventral rib, which it reaches slightly proximal to the ventro-posterior angle of the septum. Here the third, fourth and sixth nerves, in the specimen examined, turned forward and downward mesial to the anterior ventral ribs of their respective segments, the fifth nerve taking the same course but passing lateral to the anterior rib of its segment. The anterior parts of all the nerves then followed, approximately, the course of the anterior parts of their muscle segments, branches however being always

sent downward along the internal surfaces of the next posterior one or more segments. Certain of these latter branches anastomosed with each other, a net-work of branches thus being formed along the inner surface of the body wall. Whether or not any of the terminal branches of the nerves innervated any part of the trunk muscles could not be established. Near the proximal end of each nerve a branch was always sent into the muscle of its segment, innervating it.

The horizontal branch of each nerve ran at first downward to the dorsal surface of the horizontal muscle septum, and then ran outward along that septum, close to the anterior septum of its segment, according to my notes, but, according to Dr. Dewitz's sketches, rather nearer the posterior than the anterior septum.

The dorsal branch of each nerve ran upward and backward, gradually approaching the posterior septum of its segment, and then continued its course close to that septum until it reached the place where the septum turned sharply backward from its associated dorsal vertebral arch toward the next posterior arch. At this point the anterior septum of the segment passes close to and, in its deeper portions, partly fuses with the posterior septum, as already described. The nerve here gives off a branch which continues in its own segment, the larger part of the nerve, however, continuing its upward and backward course and piercing the anterior septum of its segment. The nerve then turns gradually upward, or even upward and forward, and courses toward the dorsal fin, traversing the first anterior segment, then the angle of the dorso-posterior pocket of the next, or second anterior muscle segment, then the first anterior segment again, then its own segment, and then certain of the posterior segments.

The anterior, or communicating branch of the nerve runs almost directly upward, traverses the anterior septum of its segment and joins and anastomoses with the dorsal branch of the next anterior nerve.

The first and second spinal nerves differ from the fourth to the sixth only in their ventral branches. Each of these ventral branches, after traversing the horizontal muscle septum, sends a branch into the muscle mass of the segment to which it belongs, these branches corresponding exactly with the branches sent from

the posterior nerves. The first nerve then sends a branch to the nervus pterygialis, to be described below, the remainder of the nerve running downward along the inner surface of the trunk muscles, immediately posterior to the clavicle, and entering the muscles of the ventral fin. The second nerve, after sending its first branch into the muscle of its segment, sends a long branch downward and backward along the inner surface of its segment. It then sends a branch forward to the ventral branch of the first spinal nerve, the branch joining the latter nerve distal to the point where the communicating branch is sent to the nervus pterygialis. The remainder of the second nerve then continues downward and forward along the inner surface of the trunk muscles and enters the ventral fin.

The two roots of each of the spinal nerves issue through foramina in the vertebra that gives attachment to the intermuscular septum that forms the anterior boundary of the muscle segment that the nerve innervates. The first spinal nerve thus innervates the segment that lies between the first and second vertebræ, that is the fifth muscle segment of the trunk.

The Occipital Nerves are three in number, two of them having dorsal and ventral roots, and one of them, the anterior one, a ventral root only. These roots pierce the occipitale laterale by one, two, or several openings, a separate foramen for each of the five roots having been found in one fish. Immediately outside the skull the several roots all enter a ganglionic formation that is partly double, as if it had been formed by the fusion of two ganglia. This ganglion lies immediately posterior to the third intermuscular septum, and from it, in the one specimen in which the dissection was successfully made, eight branches arose. Three of these branches were dorsal branches, two of them horizontal branches, and three of them ventral branches. The most posterior of the three dorsal branches took the same general course in relation to the fourth muscle segment that the dorsal branches of the spinal nerves do to the segments to which they are related. The next anterior one ran almost directly upward, pierced the third intermuscular septum and then turned upward and backward in the third muscle segment. The first, or most anterior one pierced at once the third intermuscular septum, trav-

ersed the third segment and then the second septum, and entered the second segment.

The most posterior of the two horizontal branches ran outward in the fourth muscle segment, to which it had the relations of the corresponding branches of the spinal nerves in the posterior muscles segments. The other, or anterior horizontal branch, ran forward and outward, traversed the third and second septa and the intervening third muscle segment, and then ran outward in the second segment, as its horizontal nerve. As it traversed the third segment it sent a horizontal branch outward in that segment.

The three ventral branches ran downward, relatively close together, along the lateral surface of the skull, and passing anterior to the ligamentum occipito-supraclavicular reached the inner surface of the trunk muscles. The two posterior branches here lie close together, the anterior branch issuing from the muscle mass slightly in front of them. Running downward and backward, the first and second nerves first unite, and then the nerve so formed unites with the third nerve, a single trunk thus being formed. From this trunk, or even from the first two nerves before they have been joined by the third one, a branch is sent downward and forward along the anterior edge of the mesial surface of the clavicle, the remainder of the nerve running onward toward the fin and becoming, after it has received a branch from the first spinal nerve, the nervus pterygialis. The anterior branch runs internal to the pharyngo-claviculares, near their origins from the clavicle, and enters the sterno-hyoideus. A small branch is sent from this nerve to certain muscle fibers along the inner surface of the clavicle that seem to belong to part of the muscles of the ventral fin.

The nervus pterygialis has the course already described in describing the muscles of the pectoral fin.

No branches of any of the nerves could be traced into the first muscle segment of the trunk.

There are thus in *Scomber,* if one considers only the foramina of the nerves, three occipital nerves; but as all the branches of the posterior one of these three nerves innervate the fourth muscle segment, and as that segment lies between the hind end of the skull and the first free vertebra, the nerve that innervates it is,

in the nomenclature and numbering employed by me in my descriptions of *Amia* (No. 4, p. 720), a postoccipital, or first spinal nerve, and not an occipital nerve. This has been already fully set forth in an earlier work (No. 6), but can be briefly summarized here. In the nomenclature employed by Fürbringer (No. 25) the third occipital nerve of *Scomber* must be either nerve "*c*," or nerve "*d*," for it issues through the skull and the nerve next posterior to it is the first free spinal nerve. If it be nerve "*c*," the anterior occipital nerve of *Scomber* would be nerve "*a*," a nerve which, according to Fürbringer, has never yet been observed in any teleost. If it be considered as nerve "*d*," instead of as nerve "*c*," *Scomber* would still seem to form an exception to all teleosts in that this nerve traverses an occipital foramen, for the nerve next posterior to nerve "*c*" is, in all the teleosts described by Fürbringer, said to be nerve 4, and the nerves so designated are said to be the first free spinal nerves. In certain fishes this nerve 4 is said by Fürbringer, to issue with nerve "*c*" from the cerebrospinal canal; but as, in the fishes in which this is said to occur, the second occipital arch is said to have disappeared, this would seem to indicate that the two nerves did not either of them perforate, in any part, the skull.

In *Amia* the first free vertebra gives attachment to the sixth intermuscular septum. In *Scomber* it gives attachment to the fourth. In *Amia* there are, anterior to this first vertebral or sixth intermuscular septum, one free spinal nerve, two spinal-like nerves with dorsal and ventral roots, and two with ventral roots only. In *Scomber* there are, anterior to the first vertebral septum, three spinal-like nerves, two of them having both dorsal and ventral roots, and one of them a ventral root only. The anterior muscle segment in each fish has no corresponding nerve. There are thus, in *Amia,* in front of the first free vertebra, two more muscle segments and two more spinal-like nerves than there are in *Scomber*. This, taken together with the relations of the several nerves to the pectoral fin, to the clavicle, and to the trunk muscles arising from that bone, and also the relations of the septa and muscle segments to the skull and to the dermal bones of the region, all seem to indicate that the two occipital vertebræ found partly fused with the hind end of the skull in *Amia,* are found as the first two free vertebræ in *Scomber*.

In *Salmo* Haller (No. 33, p. 53) finds the postvagal nerve of his descriptions arising by two ventral roots, which unite inside the cranium to form a single stem. Outside the cranium this stem unites with the first and second spinal nerves, both of which have both ventral and dorsal roots and a spinal ganglion. The trunk so formed is said to innervate the pectoral fin but to send no branch to the hypoglossal region of the fish, that region being supplied by a branch of the vagus. In *Esox* Haller says the postvagal nerve seems to present the same conditions as in *Salmo*. In *Anguilla* he says the nerve is formed of two ventral spinal roots and one dorsal root, and that it possesses a ganglion. The peripheral distribution of the nerve in *Anguilla* he did not investigate.

Anguilla may thus present the same conditions as *Scomber*, if it be assumed that the postvagal nerve of *Anguilla* lies posterior to the cranium instead of issuing through it as it does in *Scomber*. With the conditions described in *Samo* and *Esox* no comparison seems possible from the descriptions given, the hypoglossal region in those two fishes being said to be innervated by a branch of the vagus. It is to be noted that Vetter says (No. 75) that the pharyngo-claviculares of *Esox* are innervated as they are in *Scomber*, that is by branches of the Ri. pharyngei inferioris vagi, and that the sternohyoideus is innervated by "die vereinigten ersten und zweiten Spinalnerven, genauer den R. anterior derselben." Both the pharyngo-claviculares and the sternohyoideus muscles of *Amiurus* are said by McMurrich (No. 49) to be innervated by branches of the first, or first and second spinal nerves.

In the Cyprinidæ the postvagal nerve arises, according to Haller (No. 33), by a single ventral root. This root is joined first by a dorsal root, which Haller considers as the hypoglossal part of the vagus, and then by a large root coming from the so-called "Trigeminus-Komplex"; the three roots united forming the accessorius Weberi of the fish, on which a ganglion is formed. The trigeminus component of this nerve is said to arise partly from the trigeminal ganglion of its own side of the head, and partly from the corresponding ganglion of the opposite side. As the stem formed by these two roots united passes backward, it is said

to receive two or three strands "aus dem Facialisaste des Trigeminus." From the ganglion of the united roots two nerves arise. One runs dorsally inside the cranial cavity, is joined by a small branch from the most posterior bundle of the vagus root, and issues from the cranial cavity by a special foramen in the supra-occipital region of the skull, the foramen lying behind the foramen that transmits the so-called dorsal trigeminus-branch. The other and larger branch from the ganglion of the accessorius Weberi, issues from the cranial cavity through a foramen corresponding to the occipital foramina of *Amia* and *Scomber,* turns downward and backward, sends a branch to the hypoglossal region, unites with the first spinal nerve, and then enters and is distributed to the pectoral fin. Until the distribution of the branches of this nerve to the associated muscle segments of the trunk, and the distribution of the first free spinal nerve also, are known, it seems useless to attempt a comparison with *Amia* and *Scomber.* The supposition that the two spinal roots of the nerve must be the equivalent of the five roots of *Scomber,* and that the so-called trigeminal root may be a sympathetic one is however obvious, and has already been referred to by me in an earlier work (No. 8). Cole (No. 16) has suggested that the trigeminal root is probably the anterior, trigeminal root of the ramus lateralis accessorius of his own descriptions. My reasons for disbelieving this have already been given, and it is to be furthermore noted that Haller himself probably gives this anterior root of the lateralis accessorius in the nerve called by him the dorsal trigeminus branch.

In *Lota* Goronowitsch shows (No. 32, Fig. 5) the first two spinal nerves each arising by a dorsal and a ventral root, and the two nerves uniting to form a single trunk which is presumably the postvagal nerve of the fish. A nerve called by him the nervus Weberi is said to arise from the ganglion of the facialis, and is said to contain fibers from all the segmental nerves of the trigemino-facial complex. Its distribution, so far as given, seems to indicate that it is the ramus lateralis trigemini, or ramus recurrens facialis, of other descriptions of teleosts, and Cole (No. 16, p. 166) identifies it as such. It certainly cannot be the homologue of the accessorius Weberi of Haller's descriptions,

and it would seem to me impossible for it to be the homologue of any part of that nerve.

Stannius describes, in certain fishes, a ramus lateralis nervi trigemini which is apparently the nervus Weberi of other authors. He also describes a "Rückenkantenast von R. lateralis N. vagi" often found in place of the lateralis trigemini. He could not find any indications of either nerve in *Scomber*.

Palais Carnolès, Menton,
July 2, 1899.

BIBLIOGRAPHY.

1. **Alcock, R.**
The Peripheral Distribution of the Cranial Nerves of Ammocœtes. I., The Branchial Nerves, and the Innervation of the Lateral Line System. Journ. Anat. and Phys., V. 33, N. S., V. 13, Part I., pp. 131–153, October, 1898.

2. **Allis, Edward Phelps, Jr.**
The Anatomy and Development of the Lateral Line System in Amia calva. Journ. of Morph., Vol. II., No. 3, April, 1889.

3. **Allis, Edward Phelps, Jr.**
The Cranial Muscles and Cranial and First Spinal Nerves in Amia calva. Preliminary. Journ. of Morph., Vol. XI., No. 2, October, 1895.

4. **Allis, Edward Phelps, Jr.**
The Cranial Muscles and Cranial and First Spinal Nerves in Amia calva. Journ. of Morph., Vol. XII., No. 3, March, 1897.

5. **Allis, Edward Phelps, Jr.**
The Morphology of the Petrosal Bone and of the Sphenoidal Region of the Skull of Amia calva. Zool. Bulletin, Vol. I., No. 1, August, 1897.

6. **Allis, Edward Phelps, Jr.**
The Homologies of the Occipital and First Spinal Nerves of Amia and Teleosts. Zool. Bull., Vol. 2, No. 2, pp. 83–97, October, 1898.

7. **Allis, Edward Phelps, Jr.**
The Morphology of Certain Bones of the Cheek and Snout of Amia calva. Journ. of Morph., Vol. XIV., No. 3, Nov. 3, 1898.

8. **Allis, Edward Phelps, Jr.**
A Reply to Certain of Cole's Criticisms of my work on Amia calva. Anat. Anz., Bd. 15, Nos. 19, 20, pp. 364–379, Feb. 24, 1899.

9. **Allis, Edward Phelps, Jr.**
On Certain Homologies of the Squamosal, Intercalar, Exoccipitale and Extrascapular Bones of Amia calva. Anat. Anz., Bd. XVI., Nos. 3, 4, pp. 49–72, June 6, 1899.

10. **Apolant, Hugo.**
Ueber das Ganglion ciliare. Anat. Anz., Ergzs. Heft zum XII. Bd., pp. 173–174, July 31, 1896.

11. **Broman, Ivar.**
Die Entwickelungsgeschichte der Gehörknöchelchen beim Menschen. Anat. Hefte, Heft XXXVII., pp. 507–670, 1899.

12. **Brooks, H. St. John.**
The Osteology and Arthropology of the Haddock (Gadus æglefinus). Proc. Roy. Soc. Dub., Vol. IV., N. S., Part 4, Jan., 1884.

13. **Chiarugi, G.**
Contribuzioni allo Studio dello Sviluppo dei Nervi Encefalici nei Mammiferi in Confronto con Altri Vertebrati. 4. Sviluppo dei Nervi Oculomotore e Trigemello, 1897.

14. **Cole, F. J.**
The Cranial Nerves of Chimæra monstrosa. Proc. Roy. Soc. Edinburgh, Vol. XXI., March, 1896.

15. **Cole, F. J.**
On the Cranial Nerves of Chimæra monstrosa (Linn.) with a Discussion of the Lateral Line System and of the Morphology of the Chorda Tympani. Trans. Roy. Soc. Edinburgh, Vol. XXXVIII., Part 3 (No. 19), 1896.

16. **Cole, F. J.**
Observations on the Structure and Morphology of the Cranial Nerves and Lateral Sense Organs of Fishes; with Special Reference to the genus Gadus. Trans. Linn. Soc. London, Vol. VII., Part 5, October, 1898.

17. **Collinge, W. E.**
Note on the Lateral Canal System of Polypterus. Proc. Birm. Phil. Soc., Vol. VIII., Part 2, pp. 255–262, March 16, 1893.

18. **Collinge, W. E.**
The Lateral Canal System of Lepidosteus osseus. Proc. Birm. Phil. Soc., Vol. VIII., Part 2, pp. 263–272, May 24, 1893.

19. **Collinge, W. E.**
On the Sensory Canal System of Fishes. Teleostei. Proc. Zool. Soc. London, pp. 274–299, April 2, 1895.

20. **Corning, H. K.**
Ueber die Entwickelung der Zungenmuskulatur bei Reptilien. Verh. Anat. Ges., 9th Vers., Basel, April 17–20, 1895.

21. **Dahlgren, Ulric.**
The Maxillary and Mandibular Breathing Valves of Teleost Fishes. Zoöl. Bull., Vol. II., No. 3, pp. 117–124, December, 1898.

22. **Dean, Bashford.**
The Early Development of Amia. Quart. Journ. Micr. Sci., Vol. 38, Part 4, pp. 413–444, February, 1896.

23. **Dixon, Francis A.**
On the Development of the Branches of the Fifth Cranial Nerve in Man. Sci. Trans. Roy. Dub. Soc., Vol. VI. (Series II.), pp. 19–76, May, 1896.

24. **Ewart, J. C.**
The Lateral Line Sense Organs of Elasmobranchs. I. The Sensory Canals of Læmargus. Trans. Roy. Soc. Edinburgh, Vol. 37, Part I., Nos. 5, 6, 1891.

25. **Fürbringer, Max.**
Ueber die Spino-Occipitalen Nerven der Selachier und Holocephalen und ihre Vergleichende Morphologie. Festschrift f. Carl Gegenbaur, 1896.

26. **Fürbringer, Paul.**
Untersuchungen zur vergleichenden Anatomie der Muskulatur des Kopfskelets der Cyclostomen. Jen. Zeitschr. f. Naturw., Bd. IX., Heft I., pp. 1–93, Jan. 30, 1875.

27. **Gaupp, E.**
Ueber das Primordialcranium von Lacerta agilis. Anat. Anz., Ergzgsheft z. XIV. Bd., pp. 157–163, July 30, 1898.

28. **Gegenbaur, Carl.**
Untersuchungen zur vergleichenden Anatomie der Wirbeltiere. 2 Hefte. (1) Schultergürtel der Wirbeltiere. (2) Brustflosse der Fische. Leipzig, 1865.

29. **Gegenbaur, Carl.**
Ueber das Kopfskelet von Alepocephalus rostratus. Morph. Jahrb., Bd. 4, suppl. 1878.

30. **Goeppert, Ernst.**
Untersuchungen zur Morphologie der Fischrippen. Morph. Jahrb., Bd. 23, Heft 2, pp. 145–217, Nov. 12, 1895.

31. **Goronowitsch, N.**
Das Gehirn und die Cranialnerven von Acipenser ruthenus. Ein Beitrag zur Morphologie des Wirbeltierkopfes. Morph. Jahrb., Bd. 13, 1888.

32. **Goronowitsch, N.**
Das Trigemino-Facialis-Complex von Lota vulgaris. Festschrift f. Carl Gegenbaur, Bd. 3, 1896.

33. **Haller, B.**
Der Ursprung der Vagusgruppe bei den Teleostiern. Festschrift f. Carl Gegenbaur, 1896.

34. **Haller, B.**
Vom Bau des Wirbeltiergehirns. Theil I., Salmo u. Scyllium. Morph. Jahrb., Bd. 26, Heft 3, 4, Dec. 2, 1898.

35. **Herrick, C. J.**
The Cranial Nerves of Amblystoma punctatum. Journ. Comp. Neur., Vol. 4, December, 1894.

36. **Herrick, C. J.**
The Cranial Nerve Components of Teleosts. Anat. Anz., Bd. 13, No. 16, pp. 425–431, May 22, 1897.

37. **Herrick, C. J.**
Contributions to the Morphology of the Brain of the Bony Fishes. I., Siluridæ. Journ. Comp. Neur., Vol. I., pp. 211–245.

38. **Herrick, C. J.**
The Cranial Nerves of the Bony Fishes. Journ. Comp. Neur., Vol. 8, No. 3, Aug. 1, 1898.

39. **Hoffmann, C. K.**
Beiträge zur Entwicklungsgeschichte der Selachii. Morph. Jahrb., Vol. 25, Heft 2, pp. 250–304, July 2, 1897.

40. **Holt, Ernst.**
Observations upon the Development of the Teleostean Brain, with Especial Reference to that of the Clupea harengus. Zoölog. Jahrb., Bd. 4, Heft 3, pp. 478–496, Dec. 11, 1890.

41. **Holtzmann, H.**
Untersuchungen über Ciliarganglion und Ciliarnerven. Morph. Arb., Bd. VI., Heft I., pp. 114–140, 1896.

42. **Kingsbury, B. F.**
The Lateral Line System of Sense Organs in Some American Amphibia and Comparison with Dipnoans. Proc. Amer. Micr. Soc., Vol. 17, 1895.

43. **Kingsbury, B. F.**
On the Brain of Necturus maculatus. Journ. Comp. Neur., Vol. 5, Dec., 1895.

44. **Klaatsch, H.**
Die Brustflosse der Crossopterygier. Festschrift f. Carl Gegenbaur, Leipzig, 1896.

45. **Maurer, F.**
Ein Beitrag zur Kenntnis der Pseudobranchien der Knochenfische. Morph. Jahrb., Bd. IX., Heft 2, 1883.

46. **Mitrophanow, P.**
Etude Embryogènique sur les Sèlachiens. Arch. de Zool. Exp. et Gen., 3e Ser., Vol. I., pp. 161–120, 1893.

47. **Müller, Friedrich W.**
Ueber die Entwicklung und morphologische Bedeutung der Pseudobranchie, und ihre Umgebung bei Lepidosteus osseus. Anat. f. Mik. Anat., Bd. 49, Heft 3, pp. 463–502, May 20, 1897.

48. **McMurrich, J. P.**
The Osteology of Amiurus catus. Proc. Can. Institute, Toronto, pp. 270–310, Vol. II., Fasc. 3, 1884.

49. **McMurrich, J. P.**
The Myology of Amiurus catus L. Gill. Proc. Can. Inst., Vol. II., Fasc. 3, Toronto, October, 1884.

50. **Parker, W. K.**
On the Structure and Development of the Skull in the Salmon (Salmo salar L.). Bakerian Lectures. Read May 30, 1872. Phil. Trans., 1873.

51. **Parker, W. K.**
On the Development of the Skull in Lepidosteus osseus. Phil. Trans., 1882.

52. **Pinkus, F.**
Ueber einen noch nicht beschriebenen Hirnnerven des Protopterus annectens. Anat. Anz., Bd. 9, No. 18, pp. 562–566, June 23, 1894.

53. **Pinkus, F.**
Die Hirnnerven des Protopterus annectens. Morph. Arb., Bd. 4, Heft 2, pp. 275–346, 1894.

54. **Platt, J. B.**
Ontogenetische Differenzirung des Ectoderms in Necturus. Studie I. Archiv. f. Mikr. Anat., Bd. 43, Heft 4, pp. 911–966, June 30, 1894.

55. **Platt, J. B.**
Ontogenetic Differentiations of the Ectoderm in Necturus. Study II. On the Development of the Peripheral Nervous System. Quart. Journ. Micr. Sci., No. 152, pp. 485–547, February, 1896.

56. **Platt, J. B.**
The Development of the Cartilaginous Skull and of the Branchial and Hypoglossal Musculature in Necturus. Morph. Jahrb., Bd. 25, Heft 3, pp. 377–459, Dec. 3, 1897.

57. **Plessen, Jos. V., and Rabinovicz, J.**
Die Kopfnerven von Salamandra maculata in vorgeruckten Embryonalstadium. München, J. F. Lehmann, 1891.

58. **Pollard, H. B.**
On the Anatomy and Phylogenetic Position of Polypterus. Zool. Jahrb., Bd. V., Heft 3 u. 4, pp. 387–428, October 20, 1892.

59. **Pollard, H. B.**
The Lateral Line System in Siluroids. Zool. Jahrb., Bd. V., Heft 3 u. 4, pp. 524–551, October 20, 1892.

60. **Pollard, H. B.**
The Suspension of the Jaws in Fishes. Anat. Anz., Bd. X., No. I., pp. 17–25, Sept. 10, 1894.

61. **Quain.**
Elements of Anatomy, edited by E. A. Schafer and G. D. Thane. Longmans Green & Co., London, 1892–1895.

62. **Retzius, Gustav.**
Ueber das Ganglion ciliare. Anat. Anz., Bd. IX., No. 21, pp. 633–637, July 18, 1894.

63. **Ruge, Georg.**
Ueber das Peripherische Gebiet des Nervus Facialis bei Wirbeltieren. Festschrift f. Carl Gegenbaur, Leipzig, 1896.

64. **Sagemehl, Max.**
Beiträge zur vergleichenden Anatomie der Fische. I., Das Cranium von Amia calva L. Morph. Jahrb., Bd. IX., Heft 2, 1883.

65. **Sagemehl, Max.**
Beiträge zur vergleichenden Anatomie der Fische. III., Das Cranium der Characiniden, nebst allgemeinen Bemerkungen ueber die mit einem Weber'schen Apparat versehenen Physostomenfamilien. Morph. Jahrb., Bd. X., Heft I., 1884.

66. **Sagemehl, Max.**
Beiträge zur vergleichenden Anatomie der Fische. IV., Das Cranium der Cyprinoiden. Morph. Jahrb., Bd. XVII., Heft 4, Oct. 23, 1891.

67. **Schneider, H.**
Ueber die Augenmuskelnerven der Ganoiden. Inaug. Dissert., Jena, 1881.

68. **Schwalbe, G.**
Das Ganglion oculomotorii. Ein Beitrag zur vergleichenden Anatomie der Kopfnerven. Jen. Zeitschr. f. Naturw., Bd. XIII., Heft 2, July 16, 1879.

69. **Sewertzoff, A.**
Beitrag zur Entwicklungsgeschichte des Wirbeltierschädels. Anat. Anz., Bd. XIII., No. 16, May 22, 1897.

70. **Stannius, H.**
Das Peripherische Nervensysteme der Fische. Rostock, 1849.

71. **Stöhr, Ph.**
Zur Entwicklungsgeschichte des Kopfskeletes der Teleostier. Festschrift z. Feier d. 300 jahr. Best. d. Julius, Max, Univ. z. Wurzburg, Leipzig, C. W. Vogel, 1882.

72. **Studnicka, F. K.**
Beiträge zur Anatomie u. Entwicklungsgeschichte des Vorderhirns der Cranioten. 2te Abthg. Sitzber. d. K. Boh. Gesell. d. Wiss. Math. naturw. Cl., Prag, 1896.

73. **Studnicka, F. K.**
Untersuchungen ueber den Bau des Sehnerven der Wirbeltiere. Jen. Zeitschr. f. Naturwiss., Bd. 31, Heft I., pp. 1–28, April 30, 1897.

74. **Traquair, Ramsay H.**
The Cranial Osteology of Polypterus. Journ. Anat. and Phys., Sec. Ser., No. 7, Nov., 1870.

75. **Vetter, B.**
Untersuchungen zur vergleichenden Anatomie der Kiemen- und Kierfermusculatur der Fische. Theil II., Jen. Zeitschr. f. Naturw., Bd. XII., Heft 3, Aug. 1, 1878.

76. **Vrolik, A. J.**
Studien uber die Verknocherung und die Knochen des Schädels der Teleostei. Niederland Archiv. f. Zool., Vol. I., Heft 3, 1873.

77. **Wiedersheim, Robert.**
Grundriss der vergleichenden Anatomie der Wirbeltiere. Jena, 1893.

78. **Van Wijhe, J. W.**
Ueber das Visceralskelett und die Nerven des Kopfes der Ganoiden und von Ceratodus. Niederl. Archiv. f. Zool., Bd. V., Heft 3, July, 1882.

79. **Van Wijhe, J. W.**
Ueber die Mesodermsegmente und die Entwicklung der Nerven des Selachierkopfes. Amsterdam, 1882.

80. **Wright, R. Ramsay.**
On the Nervous System and Sense Organs of Amiurus. Proc. of Canadian Inst., Vol. II., Fasc. No. 3, Toronto, 1884.

EXPLANATION OF PLATES.

Index Letters.

A.	Superficial portion of adductor mandibulæ.
A_ω.	Mandibular portion of adductor mandibulæ.
A_2A_3.	Deeper portion of adductor mandibulæ.
Aap.	Adductor arcus palatinus.
ab.	Nervus abducens.
Abds.	Abductor superficialis muscle of the pectoral fin.
Abdp.	Abductor profundus muscle of the pectoral fin.
acvfr.	Foramen for anterior cerebral vein.
Add^p.	Adductor profundus.
Adds.	Adductor superficialis.
agl.	Ramus anterior glossopharyngei.
Ah.	Adductor hyomandibularis.
ahfr.	Foramen for the arteria hyoidea.
ANT.	Antorbital (Sag.), preorbital (Bridge).
Ao.	Adductor operculi.
ART.	Articular.
AS.	Alisphenoid.
BB$^{1-4}$.	First to fourth basibranchials.
bf.	Ramus buccalis facialis.
bf. io$^{1-9}$.	Branches of buccalis facialis to sense organs of infraorbital canal.
bf. so.	Branch of buccalis facialis to first sense organ of supraorbital canal.
BH.	Basihyal.
BRG.	Branchiostegal rays.
BS.	Basisphenoid.
cb.	Ciliaris brevis.
CB I–V.	First to fifth ceratobranchials.
cc.	Common carotid artery.
CH^d, CH^p.	Distal and proximal ossifications of the ceratohyal.
cl.	Ciliaris longus.
csa.	Anterior semicircular canal.
cse.	External semicircular canal.
csp.	Posterior semicircular canal.
D.	Dentary.
dgr.	Dilator groove.
dmp.	Dorso-median pocket of intermuscular septum.
Do.	Dilator operculi.
dpp.	Dorso-posterior pocket of intermuscular septum.
ea I–IV.	Efferent arteries of first to fourth branchial arches.
ECP.	Ectopterygoid.

EH.	Epihyal.
ENP.	Entopterygoid.
EO.	Exoccipital, occipitale externum (Sag.), epiotic (Bridge).
epr.	Epiphysial ridge.
es.	Eyestalk.
ESC.	Extrascapular (Sag.), supratemporal (Bridge).
ETH.	Ethmoid.
ffr.	Facial foramen.
FR.	Frontal.
fo.	Facial opening of trigemino-facial chamber.
gc.	Ciliary ganglion.
gl.	Nervus glossopharyngeus.
glfr.	Glossopharyngeal foramen.
gsy.	Sympathetic ganglion.
HB I–IV.	First to fourth hyobranchials.
hf.	Ramus hyoideus facialis.
hfn.	Hypophysial fenestra.
HH′, *HH″*	Two ossifications of the hypohyal.
Hhi^{d}.	Deeper portion of hyohyoideus.
Hhi_{s}.	Superficial portion of hyohyoideus.
HMD.	Hyomandibular.
hmf.	Truncus hyoideo-mandibularis facialis.
hms.	Horizontal muscle septum of trunk muscles.
HR.	Horizontal rib.
Iad I–V.	First to fifth interarcuales dorsales.
IC.	Intercalar (Sag.), opisthotic (Bridge).
icfr.	Internal carotid foramen.
ie.	Ethmoid incisure.
ig^{1-21}.	Infraorbital groups of pores nos. 1–21, or trunk canals leading to those pores.
$i^{18}l^{1}p$.	Pore at union of infraorbital and lateral line canals.
Im.	Intermandibularis.
IOP.	Interoperculum.
ip.	Preorbital incisure.
IPB I–IV.	First to fourth infrapharyngobranchials.
$i^{13}pm^{5}g$.	Double group of pores at union of infraorbital and preoperculo-mandibular canals.
$i^{11}s^{1}g$.	Double group of pores at union of infraorbital and supra-orbital canals.
LA.	Lachrymal.
Labe I–V.	Levator arcus branchialis externus of first to fifth branchial arches.
Labi .	Levator arcus branchialis internus, anterior muscle.
$Labi^{p}$.	Levator arcus branchialis internus, posterior muscle.
Lap.	Levator arcus palatini.
Le.	Levator muscle of the pectoral fin.
lg.	Lagena.
M.	Meckel's cartilage.
mdc.	Mandibular lateral canal.

mdit.	Ramus mandibularis internus trigemini.
mef.	Ramus mandibularis externus facialis.
mif.	Ramus mandibularis internus facialis.
mif. fr.	Foramen for passage of mandibularis internus facialis.
mit.	Ramus maxillaris inferior trigemini.
MX.	Maxillary.
NA.	Nasal.
na.	Nasal aperture.
nll.	Nervus lineæ lateralis.
nll. v. st.	Supratemporal branch of vagus and lineæ lateralis.
O.	Nervus opticus.
OB.	Occipitale basale (Sag.), or basioccipital (Bridge).
ocfr.	Occipital foramina.
ocm.	Nervus oculomotorius.
ocm. fr.	Foramen for nervus oculomotorius.
ocmi.	Inferior branch of nervus oculomotorius.
ocms.	Superior branch of nervus oculomotorius.
Od^{1-3}.	Obliqui dorsales.
of.	Ramus oticus facialis.
ofc.	Canal for ramus oticus facialis.
Oi.	Obliquus inferior.
OL.	Occipitale laterale (Sag.), or exoccipital (Bridge).
ol.	Nervus olfactorius.
OP.	Operculum.
opf.	Ramus ophthalmicus superficialis facialis.
opf. so$^{2-7}$.	Branches of ophthalmicus facialis to sense organs of supra-orbital canal.
opp. fr.	Foramen for profundus nerve.
oprf'.	Ramus opercularis facialis, anterior branch.
oprf''.	Ramus opercularis facialis, posterior branch.
opt.	Ramus ophthalmicus superficialis trigemini.
Os.	Obliquus superior.
P.	Palatine.
PA.	Parietal.
PC.	Procoracoid.
pc.	Palatine canal.
Pce.	Pharyngo-clavicularis externus.
Pci.	Pharyngo-clavicularis internus.
PE.	Petrosal.
pf.	Ramus palatinus facialis.
pfr.	Palatine foramen.
Ph.	Pharyngo-hyoideus.
pmg.	Preoperculo-mandibular groups of pores.
pmp.	Preoperculo-mandibular primary pores.
PMX.	Premaxillary.
POP.	Preoperculum.
PRE.	Prefrontal.
pr. fr.	Foramen for nervus profundus.
prgl + f.	Pretrematicus glossopharyngeus + facialis.

PS.	Parasphenoid.
PSF.	Postfrontal (Sag., Allis), dermo-postfrontal (Bridge).
psgl.	Ramus posttrematicus glossopharyngei.
PSP.	Processus spinosus.
PST.	Postorbital ossification (Allis), postfrontal (Sag.), sphenotic (Bridge).
pto.	Pituitary opening.
Q.	Quadrate.
R.	Rostrale.
raa.	Ramulus ampullæ anterioris.
r.ae.	Ramulus ampullæ externæ.
r.am.	Branch of "r. max. inf. trig." to "A_2A_3."
r.ap.	Ramulus ampullæ posterioris.
r.gh.	Branch of "r. max. inf. trig." to geniohyoideus.
retf.	Ramus communicans from trigeminus to facialis.
Rita.	Accessory rectus internus muscle.
r.lap.do.	Branch of "r. max. inf. trig." to "lap." and "do."
Re.	Rectus externus.
Rif.	Rectus inferior.
Rit.	Rectus internus.
rl.	Radix longa.
r.mn.	Ramulus maculæ acusticæ recessus utriculi.
r.oi.	Branch of oculomotorius to obliquus inferior.
rp.	Radix ophthalmici profundi.
r. rif.	Branch of oculomotorius to rectus inferior.
r. rit.	Branch of oculomotorius to rectus internus.
Rs.	Rectus superior.
S.	Sternum.
SC.	Scapulare.
sc.	Sacculus.
scr.	Saccular groove or recess.
sg$^{1-8}$.	Supraorbital groups of pores nos. 1–8, or trunk canals leading to those pores.
Sh.	Sternohyoideus.
SO.	Supraoccipital.
SOP.	Suboperculum.
SPB,I.	Suprapharyngobranchial of first arch.
spt.gr.	Supratemporal groove.
SQ.	Squamosal.
SS.	Suprascapular.
Stc.	Supratemporal lateral canal.
SY.	Symplectic.
Sy.	Sympathetic nerve.
t.a_3*art.*	Tendon of A_3 to inner surface of articulary.
t.a_1*la.*	Tendon of A_1 to inner surface of lachrymal.
t.a_2*mx.*	Tendon of A_2 to inner anterior end of maxillary.
tcp.	Truncus ciliaris profundus.
Tda.	Transversus dorsalis anterior.
Tdp.	Transversus dorsalis posterior.

tfr.	Trigeminal foramen.
tgr.	Temporal groove.
tmt.	Truncus maxillaris trigemini.
to.	Trigeminal opening of trigemino-facial chamber.
tr.	Nervus trochlearis.
trfr.	Foramen for trochlearis.
V^1.	First vertebra.
v.	Nervus vagus.
$v^1v^2v^3v^4$.	First to fourth vagus nerves.
vfr.	Vagus foramen.
VO.	Vomer.
VR.	Ventral rib.

EXPLANATION PLATE III.

Fig. 1. Dorsal view of the head of *Scomber*, showing the lateral sensory canals. × 1½.

Fig. 2. Ventral view of the same, showing the lateral sensory canals. × 1½.

Fig. 3. Lateral view of the same, showing the lateral sensory canals. × 1½.

Fig. 4. Lateral view of the skeleton of the head. × 1½.

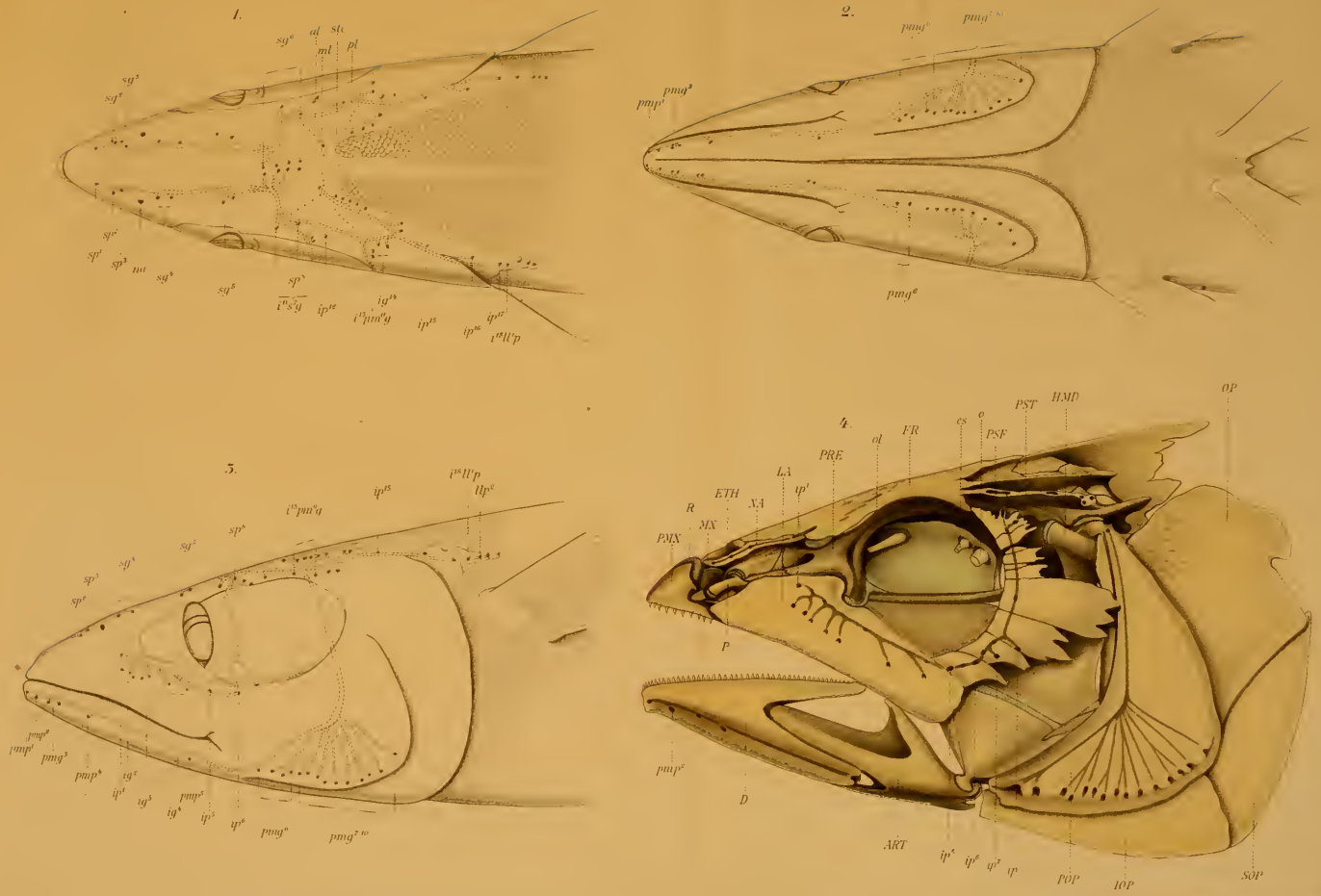
1.
2.
3.
4.
PMX
MX
R
ETH
NA
LA
PRE
ol
FR
es
o
PSF
PST
HMD
OP
P
D
ART
POP
IOP
SOP

EXPLANATION OF PLATE IV.

Fig. 5. Dorsal view of the skull. × 2.

Fig. 6. Dorsal view of the skull, with the purely dermal bones removed. × 2.

Fig. 7. Lateral view of the skull. × 2.

Fig. 8. Median view of a bisected skull. × 1½.

Fig. 9. Ventral view of the skull. × 2.

Fig. 10. Posterior view of the skull. × 2.

5.
PRE
FR
dgr
tgr
sptgr
ofc
PA
SO
EO
IC
VO
ETH
OL
PSP
sp²
XA
sg⁵
sg⁶
sp⁸
PST
SQ
ESC
SS
tg¹⁶
6.
ie
ip
7
PST
PA
SQ
EO
IC
OL
VO
ETH
PRE
PS
AS
trfr
BS
to
icfr
fo
PE
vfr
glfr
ocfr
OB
8.
AS
epr
FR
PST
PA
SO
EO
OL
ETH
VO
PS
trfr
ocmfr
pfr
icfr
PE
glfr
vfr
ocfr
OB
9.
AS
ofc
PST
BS
PE
icfr
SQ
IC
OL
ETH
FR
OB
ETH
PRE
VO
ol
PS
acvfr
trfr
ocmfr
to
fo
glfr
vfr
10.
EO
OL
SQ
IC
fo
PE
PS
BS

EXPLANATION OF PLATE V.

Fig. 11. Lateral view of the brain case, showing the surfaces of insertion of the muscles. × 2.

Fig. 12, *a*. External view of the rostrale. × 2.

Fig. 12, *b*. Internal view of the same. × 2.

Fig. 13. Lateral view of the squamosal bone. × 2.

Fig. 14. External view of the maxillary. × 2.

Fig. 15. Internal view of the maxillary. × 2.

Fig. 16. External view of the premaxillary. × 2.

Fig. 17. Internal view of the premaxillary. × 2.

Fig. 18. Internal, or dorsal view of the parasphenoid. × 2.

Fig. 19. Internal, or dorsal view of the vomer. × 2.

Fig. 20. Internal, or ventral view of the frontal. × 2.

Fig. 21. External view of the petrosal. × 2.

Fig. 22. Internal view of the petrosal. × 2.

Fig. 23. Dorsal view of the occipitale laterale. × 2.

Fig. 24. Dorsal view of the basioccipital. × 2.

Fig. 25. Ventral view of the basioccipital. × 2.

Fig. 26. Lateral view of the first three vertebræ. × 2.

Fig. 27. Lateral view of the supraclavicular. × 2.

Fig. 28. Three scales of the lateral line. × 4.

11.

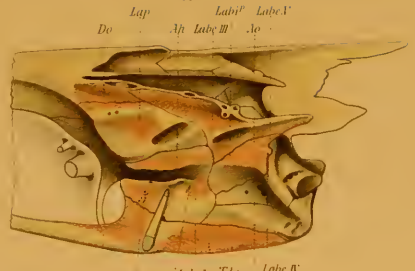

12

13.



14.

15.

16.

17.



18.

19.

20.

21.

22.



23.

24.

25.

26.

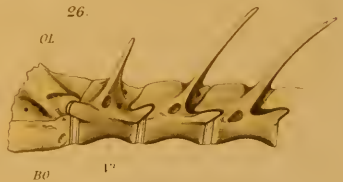

27.

28.

EXPLANATION OF PLATE VI.

Fig. 29. Dorsal view of the hyoid and branchial arches, showing the insertions of the muscles. The basihyal has been pulled forward, the fifth ceratobranchials pulled backward, and the bones all spread apart somewhat, for better illustration. × 2.

Fig. 30. Ventral view of the same, with the epibranchials and pharyngobranchials removed. × 2.

Fig. 31. Lateral view of the cerato-hypohyal. × 2.

Fig. 32. Lateral view of the basibranchials. × 2.

Fig. 33. Lateral view of the basibranchials. × 2.

Fig. 34. Ventral view of the basibranchials. × 2.

Fig. 35. Internal, or mesial view of the mandible. × 2.

29.

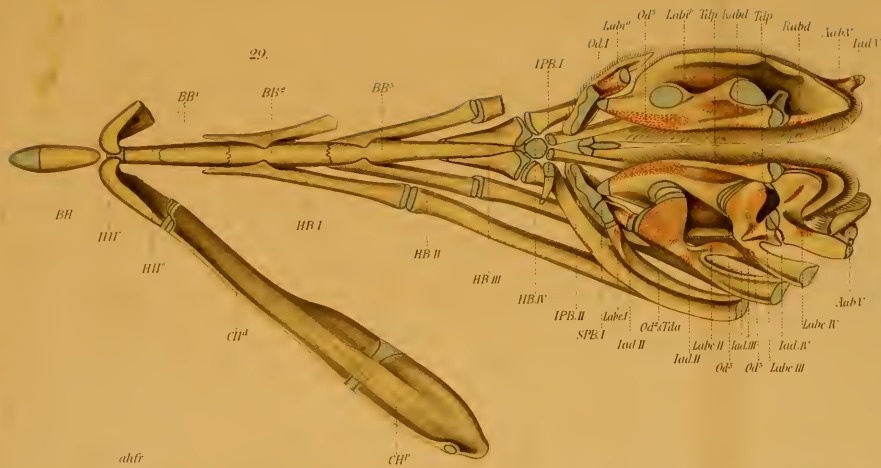

30.

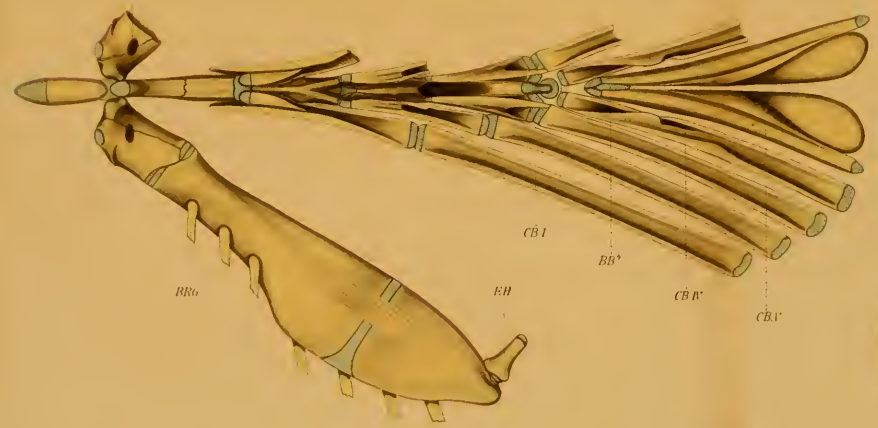

31

32.



33.



34.

35.

EXPLANATION OF PLATE VII.

Fig. 36. External, or lateral view of the hyomandibulo-symplectic and palato-quadrate apparatus. × 2.

Fig. 37. Internal view of the same, with the opercular bones attached. × 2.

Fig. 38. Dorsal view of the ventral surface of the mouth and branchial cavity. × 2.

Fig. 39. Diagrammatic view of a section of the opercular demibranch.

Figs. 40 and 43. Enlarged views of the bristles on the dermal processes of the branchial arches.

Figs. 41 and 42. Enlarged views of the dermal processes on the branchial arches.

Fig. 44. Enlarged view of the dermal rays of the gill filaments, showing the associated muscles.

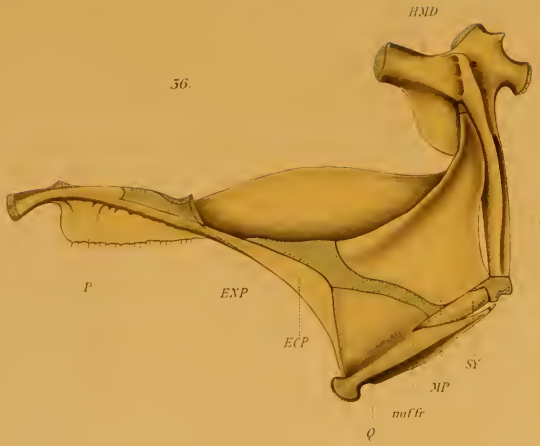
36.
HMD
P
EXP
ECP
SY
MP
muf/r
Q

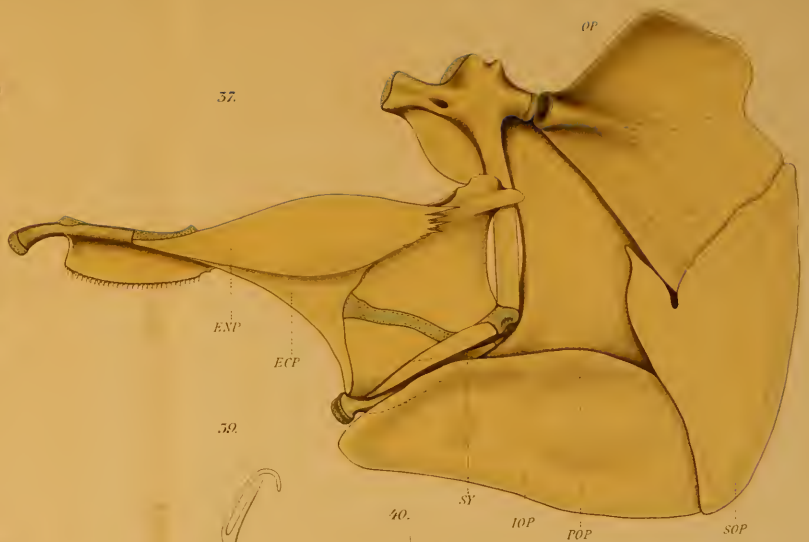
37.
OP
EXP
ECP
SY
IOP
POP
SOP

38

39.


40.

a
41.
b


a
42.
b

43.

44.

EXPLANATION OF PLATE VIII.

Fig. 45. Lateral view of the left clavicle and primary shoulder-girdle, with all the muscles removed. × 2.

Fig. 46. The same, with the abductor superficialis alone removed. × 2.

Fig. 47. Dermal ray of the pectoral fin, showing the attachment of the muscles. × 4.

Fig. 48. Three views of the propterygial ray of the pectoral fin. × 4.

Fig. 49. Lateral view of the left clavicle, the sternum, and the fifth cerato-branchial, with the associated muscles. × 2.

Fig. 50. Internal, or mesial view of the left clavicle, the primary shoulder-girdle and the accessory bones, with all the associated muscles removed. × 2.

Fig. 51. The same, with the associated muscles; the superior division of the adductor profundus has been cut and turned backward. × 2.

Fig. 52. Ventral view of the left eyeball and its associated muscles; the posterior portion of the rectus internus removed. × 2.

Fig. 53. The lachrymal and suborbital bones, showing the lateral canal and the nerves innervating it. × 1½.

45.
Sc
PC
CL
46.
Abdp
Le
47.
48.
a
b
c
49.
CBV
Pct
Sh
Ph
Sh
S
50.
Adas
51.
Addp
Adds
Addp
Pct
Pct
52.
Rs
Rt
Ot
es
Rit
Rit''
Rit'
Rit
53.

EXPLANATION OF PLATE IX.

Fig. 54. Lateral view of the head; with the skin that covers the muscles removed. × 2.

Fig. 55. The same, a deeper dissection. × 2.

54.

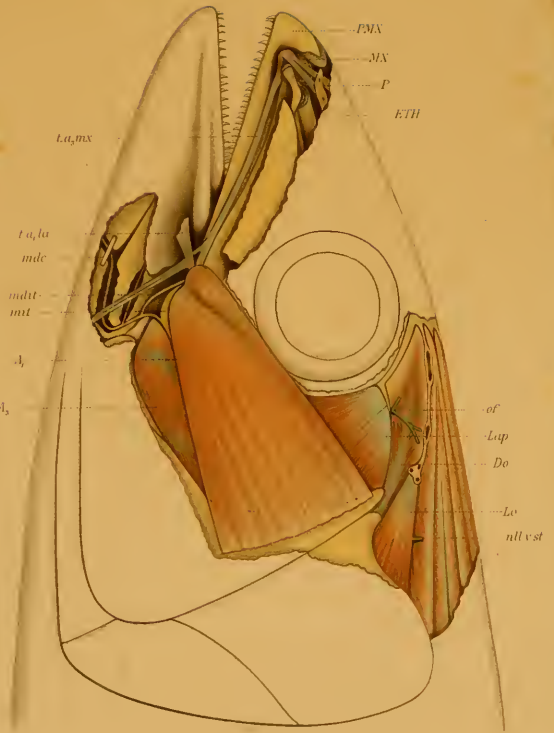
PMX
MX
P
ETH
t.a₃mx
t.a₁la
mdc
mdit
mit
A₁
A₂A₃
of
Lap
Do
Lo
nll v st

55.

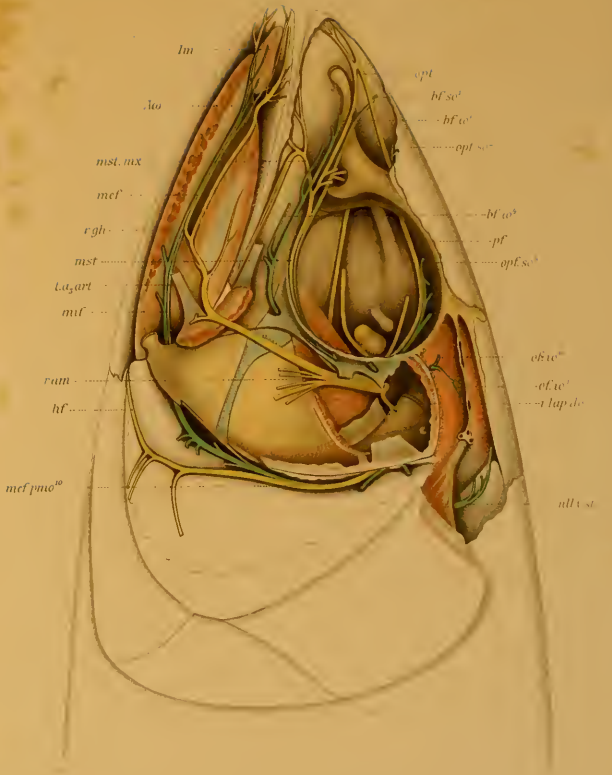
Im
Ao
mst. mx
mcf
rgh
mst
t.a₃art
mif
ram
hf
mcf pmo¹⁰
opt
bf so¹
bf io¹
opf so²
bf io⁴
pf
opf so⁵
of io¹⁰
of io¹
r lap do
nll v st

EXPLANATION OF PLATE X.

Fig. 56. Ventral view of the anterior end of the head; with the outer skin removed, and the mandibles spread apart so as better to show the muscles. × 2.

Fig. 57. The same, a slightly deeper dissection. × 2.

Fig. 58. The same, a still deeper dissection. × 2.

Fig. 59. Dorsal view of the branchial arches, with the associated muscles, nerves and arteries. The skull and spinal column have been removed by cutting the nerves and muscles, and the muscles that were attached to the skull have been allowed to fall mesially and downward onto the arches and considerably out of their natural position. The levator of the fifth arch is shown as a small bit of muscle attached to the nerve that innervates it. × 3.

56.


Hhi
BRG
Ghs
Ghi
rgh

57.

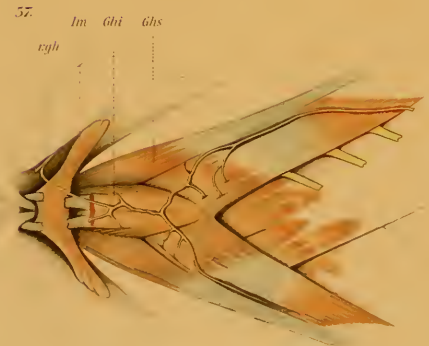
Im
Ghi
Ghs
rgh

58.


HH
Ghs
Hhi
BRG

59.

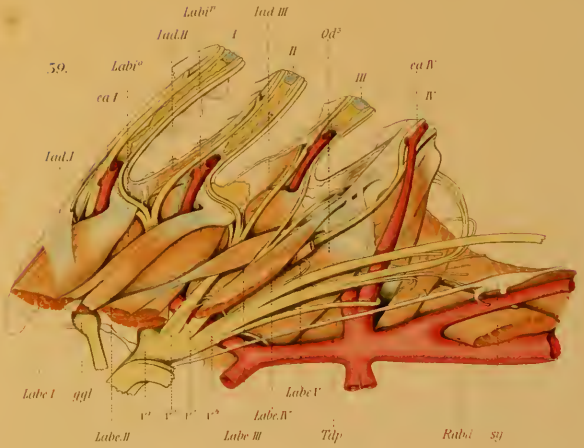
Labi^p
Iad III
Iad.II
I
Od^3
II
Labi^o
III
ca IV
ca I
IV
Iad.I
Labe I
ggl
Labe V
Labe.IV
Labe.II
Labe III
Tdp
Rabd
sg

EXPLANATION OF PLATE XI.

Fig. 60. The same as Fig. 59; with the levator muscles of the arches all cut near their insertions. × 3.

Fig. 61. Internal, or mesial view of the right eyeball, with its associated muscles and nerves. × 1½.

Fig. 62. Lateral view of the anterior muscle segments of the trunk, the muscle fibers all removed so as to show the septa and the related spinal and occipital nerves. × 4.

Fig. 63. Dorsal view of the floor of the cranial cavity. × 2½.

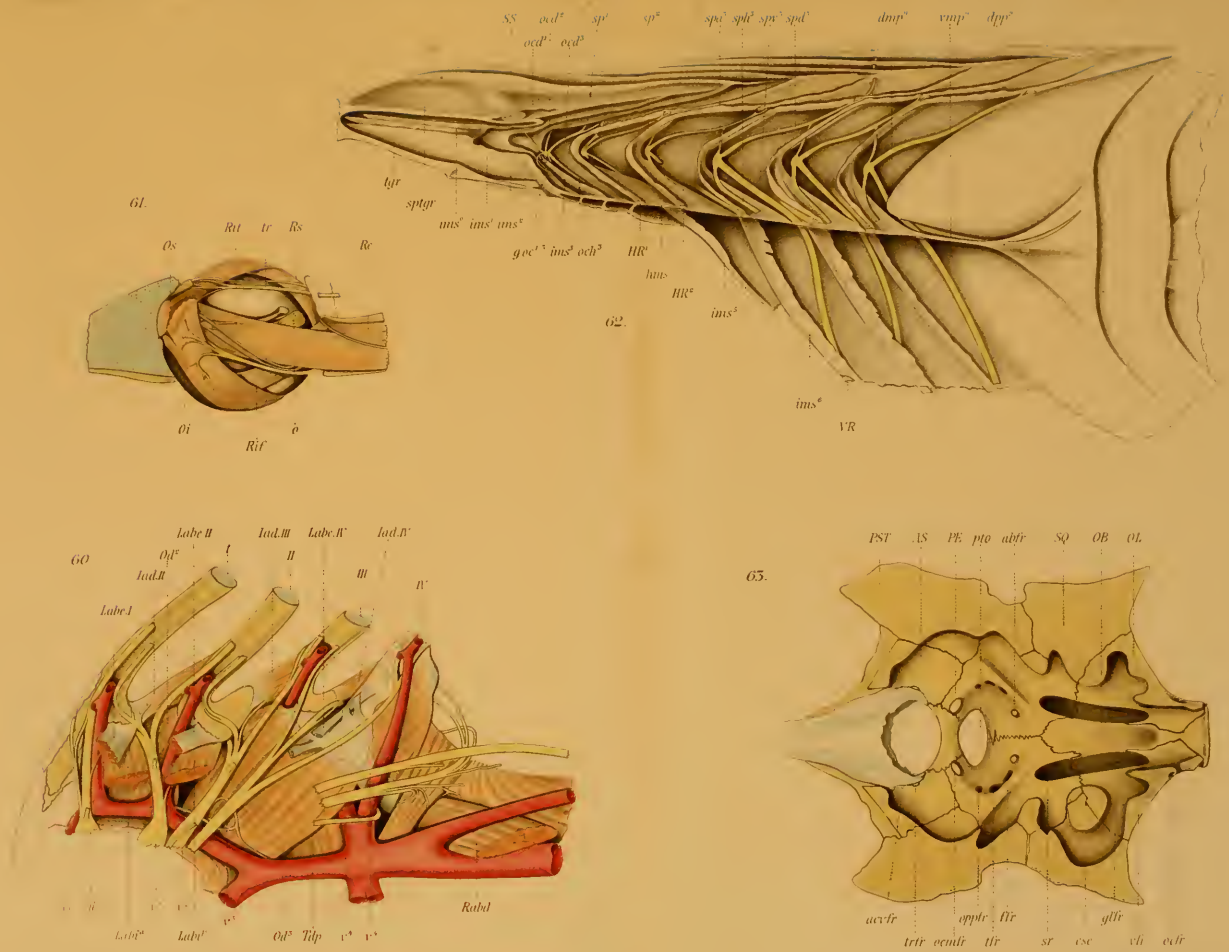
61.
Os
Rit
tr
Rs
Rc
Oi
o
Rif
62.
SS
ocd²
sp¹
sp²
spa³
sph³
spv³
spd³
dmp⁴
vmp⁴
dpp⁴
ocd¹
ocd³
tgr
sptgr
ims⁰
ims¹
ims²
goc¹³
ims³
och³
HR¹
hms
HR²
ims⁵
ims⁶
VR
60
Labe II
Iad.III
Labe.IV
Iad.IV
Od²
Iad.II
Labe.I
II
III
IV
Labi²
Labi¹
v³
Od³
Tilp
v⁴
v⁵
Rabl
63.
PST
AS
PE
pto
abfr
SQ
OB
OL
acvfr
opptr
ffr
glfr
trfr
ocmfr
tfr
sr
csc
vfi
ocfr

EXPLANATION OF PLATE XII.

Fig. 64. Lateral view of the brain, showing the apparent origins of the cranial nerves. × 3.

Fig. 65. Ventral view of the same. × 3.

Fig. 66. Lateral view of a part of the side of the head, showing the eyeball pushed forward and the trigeminofacial chamber opened so as to expose the issuing nerves. The truncus hyoideo-mandibularis facialis is turned upward against the side wall of the skull. × 4.

Fig. 67. Lateral view of the membranous ear. × 3.

Fig. 68. Mesial view of the membranous ear. × 3.

64.

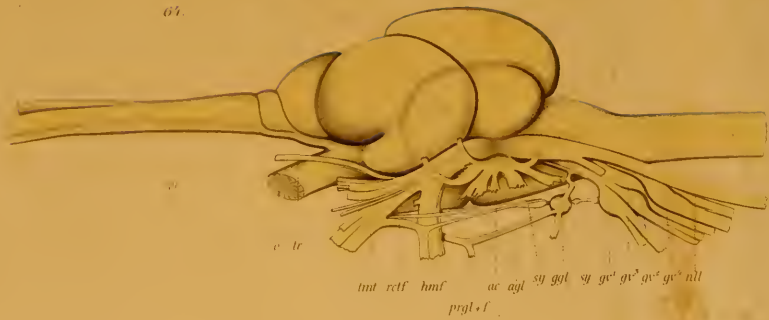
e tr
tmt rctf hmf ac agl sy ggl sy gv¹ gv³ gv² gv⁴ nll
prgl+f

65.

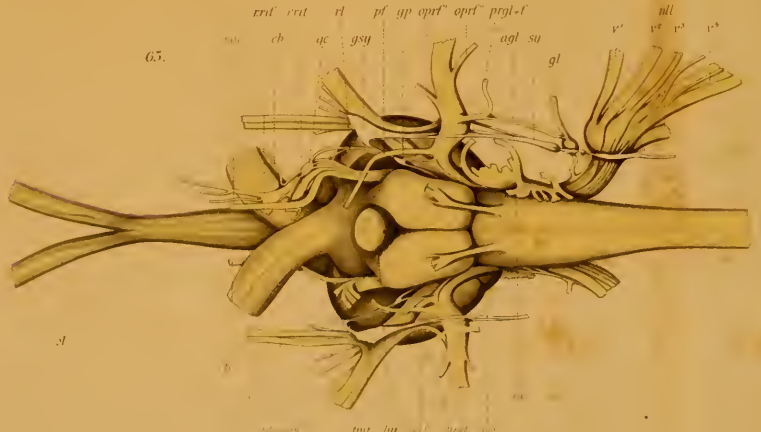
rrif rrit rl pf gp oprf' oprf'' prgl+f nll
cb ac gsy agl sy
gl
v¹ v² v³ v⁴
tmt hy

66.


Os Rs cl opt opt gsy tmt oprt hmf oprf
cb Rit Rit rov gc ocm rl pf prgl+f

67.

68

5 WHSE 04695

Sept. 2, 1915

111